

Case Report

Carotid Cavernous Sinus Fistula with Non-Pulsatile Exophthalmos

Sultan Ahmad, Muhammad Khalil, Tayyaba Gul Malik, Mian Muhammad Shafique, Khalid Farooq

Pak J Ophthalmol 2007, Vol. 23 No. 4

.....
See end of article for
authors affiliations

We report a case of post traumatic carotid artery cavernous sinus fistula with a special feature of non pulsatile exophthalmos in the presence of bruit.

.....
Correspondence to:
Sultan Ahmad
Eye Department
Lahore Medical and Dental
College, Lahore.

Received for publication
August' 2006
.....

Carotid-cavernous fistula (CCF) is an abnormal connection between the carotid arterial system and the venous vessels in the cavernous sinus. This occurs when the walls of the arteries and veins break down and combine together into one vessel. As a result, blood flows backwards in the vein¹⁻³.

D.L. Barrow and colleagues classified CCF into four types⁴.

Type I: Direct fistula between the internal carotid artery and the cavernous sinus.

Type II: Indirect fistula between the meningeal branches of the internal carotid artery and cavernous sinus.

Type III: Indirect fistula between the meningeal branches of the external carotid artery and cavernous sinus.

Type IV: Indirect fistula between the branches of both internal carotid artery and external carotid artery and cavernous sinus.

CASE REPORT

A 25 years old Asian male presented with protrusion of his right eye 20 days after a road traffic accident. (RTA). He remained unconscious for few hours and underwent surgery for his right knee joint which was fixed with wiring. 20 days after RTA he started developing gradual onset, slowly progressive protrusion of his right eye unassociated with any ocular or periorbital pain. He gave history of noises in the head but there was no diplopia, fever and vomiting. Systemic history was unremarkable.

On ocular examination, his BCVA was finger counting on right side and 6/6 on left side. Intraocular pressures were 17 and 12 mmHg respectively. There was right proptosis of 10 mm which increased on bending and Valsalva's maneuver. There were no visible pulsations of the eyeball. Lids were edematous and severe conjunctival chemosis and keratinization was seen (Fig. 1, 2). There were no signs of exposure keratopathy. Color vision was normal. Extra ocular movements of the right eye were restricted in all gazes (Fig. 3). Right pupil was mid-dilated and non-reactive to light and accommodation. Left pupil was round and reacting normally to light and accommodation.

On palpation there was no thrill and tenderness. Temperature of the skin was normal. Corneal sensations were impaired on the right side. There was no palpable periorbital mass. On auscultation there was medium pitched bruit over the eyeball which was synchronous with arterial pulse. It was absent on

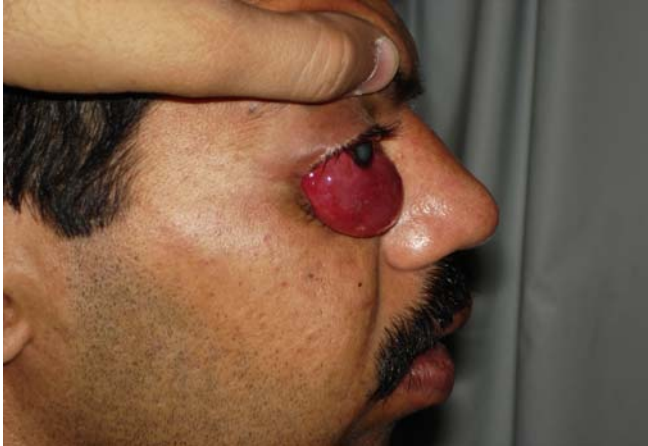

Fig. 1: Prolapsed, congested and chemosed conjunctiva of right eye (lateral view).

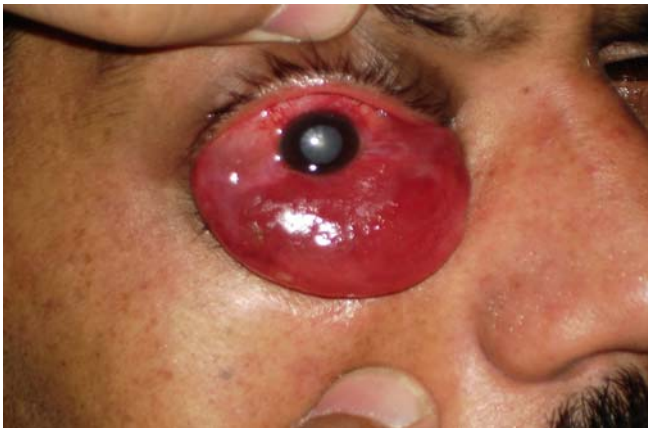

Fig. 2: Closer view. Arrow indicates dilated fixed pupil and post traumatic cataract.

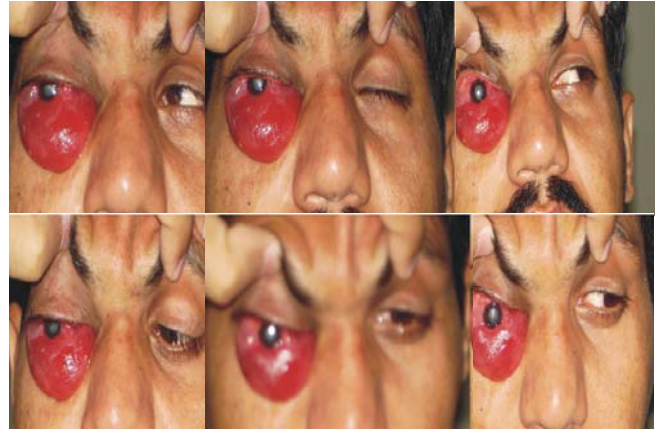

Fig. 3: Restricted extra ocular movements of right eye.

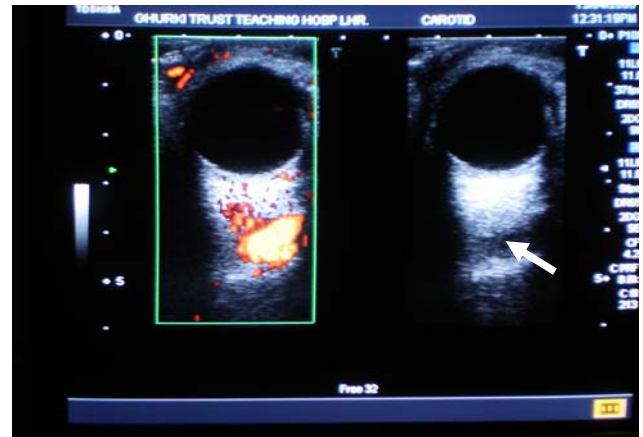


Fig. 4: Doppler ultrasound of right orbit. Red arrow shows turbulence in right superior ophthalmic vein. White arrow pointing towards dilated right superior ophthalmic vein.

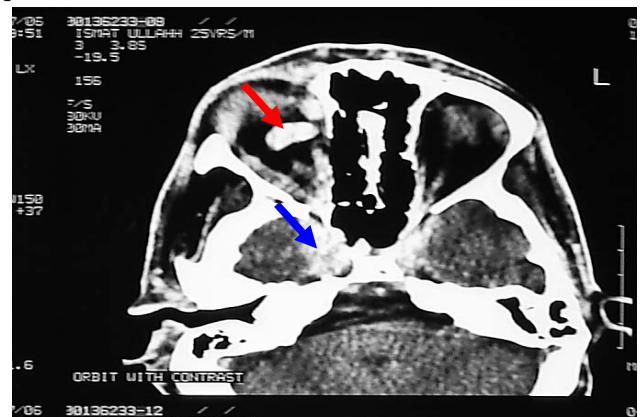


Fig. 5: CT axial view orbit: Red arrow indicating dilated superior ophthalmic vein on right side. Blue arrow shows dilated right cavernous sinus.

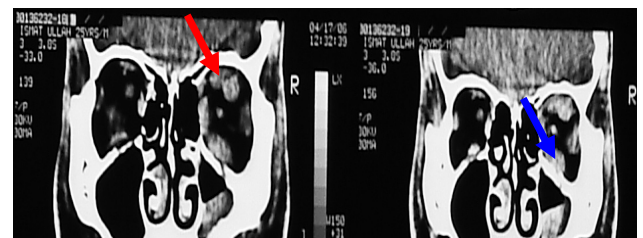


Fig. 6: CT Coronal view skull. Dilated superior ophthalmic vein (Red arrow) and swollen extra ocular muscles (Blue arrow).

temple and forehead. On slit lamp examination conjunctiva was severely congested with tortuous, dilated blood vessels. Corneal endothelial dusting was present. Anterior chamber was normal in depth and quiet. Few pigments were seen floating with mild flare. Pupil was vertically oval and fixed. Lens was opaque. No micropulsations of eye ball were seen on applanation. Fundus examination of right eye was not possible because of cataract. Left eye was normal with normal fundus with no vascular abnormalities.

B-scan of right eye was performed which showed anechoic vitreous. Retina was normal. Orbital fat edema and dilated superior ophthalmic vein of the right eye was quite obvious. Doppler ultrasound showed turbulent flow in superior ophthalmic vein (Fig. 4). Patient was subjected to computerized tomographic scan which revealed protruded eyeball with swollen extra ocular muscles. Superior ophthalmic vein was dilated (Fig. 5, 6). Mandible of the right side was fractured. On the basis of these clinical findings and investigations, the diagnosis of post traumatic direct carotid cavernous sinus fistula was made. Carotid angiography was planned but the patient refused further investigations.

DISCUSSION

Although the common presentation of direct carotid cavernous sinus fistula is the classic triad of pulsatile proptosis, conjunctival chemosis & flushing noise in the head⁵. There are situations in which any of these may be absent or they are subtle enough to be detected clinically. e.g. in low flow fistulas chemosis, pulsation or flushing noise/ bruit may be absent. How ever in direct type with high flow fistula it is rather infrequent to find a marked proptosis without pulsation as in our

case. Possibilities regarding absence of pulsation may be due to:

1. Superior ophthalmic vein thrombosis⁶
2. Very large or very small fistula size
3. Retrograde flow towards intracranial circulation
4. Bilateral involvement

The best way to find out the exact etiology is cranial angiography which was unluckily not done. Doppler flow of orbital circulation revealed high turbulence and dilatation of superior ophthalmic vein which indicated absence of thrombosis in superior ophthalmic vein. As the bruit in our patient was medium pitched, depicting moderate sized fistula, the possibility of very large and very small fistula was negated. Retrograde flow towards intracranial circulation should have some neurological deficit and or signs of raised intracranial pressure which were absent in our case. There was no bilateral involvement as obvious from the CT scan. The exact mechanism for the absence of pulsations remains a mystery.

CONCLUSION

Cranial Angiography is the gold standard for Carotid cavernous sinus fistulas to establish the size of fistula, status of blood flow in the vessels and presence or absence of thrombosis. Even in the absence of angiography, CT scan and Doppler studies are helpful in the diagnosis.

Author's affiliation

Brig.(Rtd.) Sultan Ahmad
Associate Professor, Eye Department
Lahore Medical and Dental College, Lahore.

Dr. Muhammad Khalil
Assistant Professor
Ophthalmology Department
Lahore Medical and Dental College, Lahore.

Dr. Tayyaba Gul Malik
Ophthalmology Department
Lahore Medical and Dental College, Lahore.

Dr. Mian Muhammad Shafique
Associate Professor
Ophthalmology Department
Lahore Medical and Dental College, Lahore.

Dr. Khalid Farooq
Assistant Professor
Radiology Department
Lahore Medical and Dental College
Lahore

REFERENCES

1. **Kupersmith MJ.** Neuro-Vascular Neuro-Ophthalmology. Berlin, Springer-Verlag, 1993.
2. **Fleishman JA, Garfinkel RA, Beck RW.** Advances in the treatment of carotid cavernous fistula. *Int Ophthalmol Clin.* 1986; 26: 301.
3. **Parkinson D.** Carotid cavernous fistulas: Direct repair with preservation of the carotid artery: Technical note. *J Neurosurg.* 1973; 38: 99.
4. **Barrow DL, Spector RH, Braun IF, et al.** Classification and treatment of spontaneous carotid-cavernous sinus fistulas. *J Neurosurg.* 1985; 62: 248-56.
5. **Kanski JJ.** Carotid Cavernous Fistula: *Clinical Ophthalmology.* 2003; 574.
6. **Miller NR.** Walsh and Hoyt's Clinical Neuro-Ophthalmology, 4th ed. Baltimore, Williams & Wilkins, 1991.