

# Out Come of Sahaf Enucleation Implants in 60 Patients

Zahid Kamal Siddiqi, Girdhari Lal, Abdul Hye

*Pak J Ophthalmol 2008, Vol. 24 No. 1*

.....  
See end of article for  
authors affiliations  
.....

Correspondence to:  
Zahid kamal Siddiqi  
Eye Unit I  
Lahore General Hospital  
Lahore.

Received for publication  
December' 2007  
.....

**Purpose:** To give an overview of surgical outcome of Sahaf enucleation implant in 60 patients.

**Material and Methods:** A descriptive prospective study was done of patients visiting the department of Ophthalmology in Lahore General Hospital, Lahore from June 2003 to May 2006. PMMA Sahaf implant was used in all cases after enucleation.

**Results:** A total number of 60 patients were included. Intraocular tumor was most important cause for enucleation. The second most common disorder was trauma. Three initial cases (5 %) had necrosis of the conjunctiva leading to exposure of implant, which needed reinforcement by autogenous fascia lata. Later all those cases who had thin Tenon's fascia had a reinforcement by sclera or autogenous fascia lata.

**Conclusion:** All patients had excellent cosmetic results, with out any serious side effects.

Sahaf enucleation implant is a new PMMA orbital implant. It has unique two piece design. Posterior hemispherical portion of Sahaf enucleation implant gives support to hold recti muscles and anterior convex curvature supports the prosthesis. (Fig. 1) It is inert, cost effective, with no cutting edges and easily available in Pakistan. Multiple sizes are available to restore volume (Fig. 2), enhance ocular motility and support prosthesis after enucleation.

The three most common indications for enucleation are intraocular malignancy; trauma and a blind painful eye<sup>1</sup>. Evisceration, enucleation and exenteration are indeed mutilating procedures. However, they are still resorted to, in order to save the other eye, to relieve the patient from agonizing pain or save the life of the patient<sup>2</sup>. Orbital implants mainly being used are Allen implants, silicone implants and porous implants<sup>3</sup>. Spherical nonporous and non-

pegged porous enucleation implants provide similar prosthesis motility when they are implanted using similar surgical techniques<sup>4</sup>.

The top three reasons for implant choice are surgical outcome, cost, and experience<sup>5</sup>. Primary orbital implant with adequate sized Allen type acrylic after tension-free closure of Tenon and conjunctiva give fairly acceptable cosmetic results<sup>6</sup>. However, the sharp cutting edges of the implant combined with tilt when rubbed with prosthesis results in cutting of conjunctiva exposure and extrusion.

The objective of this study was to assess outcome of newly introduced and locally made Sahaf enucleation implant.

## METHODOLOGY

This descriptive and prospective study was conducted in the department of ophthalmology

Lahore General hospital Lahore, from May 2003 to June 2006. All those patients who need enucleation were included in this study and patients with recurrent tumors with extra-ocular extension were excluded.

Hospital patient entry registers were used to collect the data and all entries were made on specific performa. All relevant information then entered into the computer for analysis.

**MATERIAL AND METHODS**

The procedure was explained and written consent for eye removal was taken from patient or parents of child. All the patients were operated under general anesthesia. After conjunctival peritomy recti muscle were secured with 5/0 vicryl and cut from their insertion. Posterior portion of implant was inserted and all recti tendons were passed through it (Fig. 3). Horizontal and vertical recti were sutured with each other. Anterior portion placed over posterior and closure was done in two layers (tenon’s and conjunctiva). The anterior part was wrapped in sclera or fascia lata in some cases. After 5 days dressing was opened. Volume replacement of the socket was measured by comparing it with normal eye.

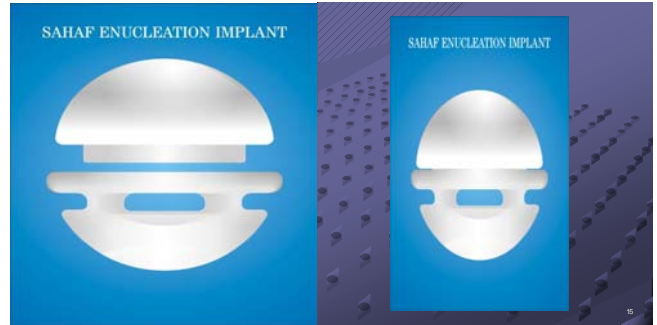
Motility was graded 0-3 (grade 0= no motility, grade 1=10°, grade 2=10°-30°, grade 3=>30°) in horizontal and vertical meridian.

Cosmetic satisfaction was assessed by patient’s comments and doctor’s observation. The data was analyzed according to age, gender, diagnosis, and management. Simple descriptive analysis was carried out.

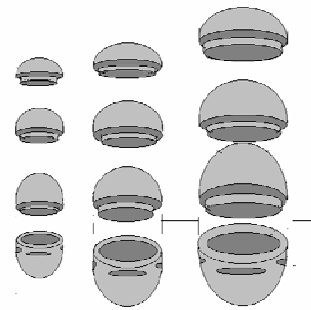
**RESULTS**

This study comprised of a total number of 60 cases, out of which, 45 (75%) were male and 15 (25%) were female. The age range was 2-65 years (median 12 years). The underlying pathology included retinoblastoma 36 (60%), malignant melanoma 4 (6.66%), painful blind eye 12 (20%) and phthisis bulbi 8 (13.3%) eyes.

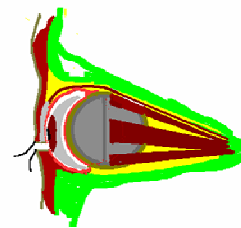
Three initial cases had necrosis of the conjunctiva leading to exposure of implant, which needed reinforcement by autogenous fascia lata.



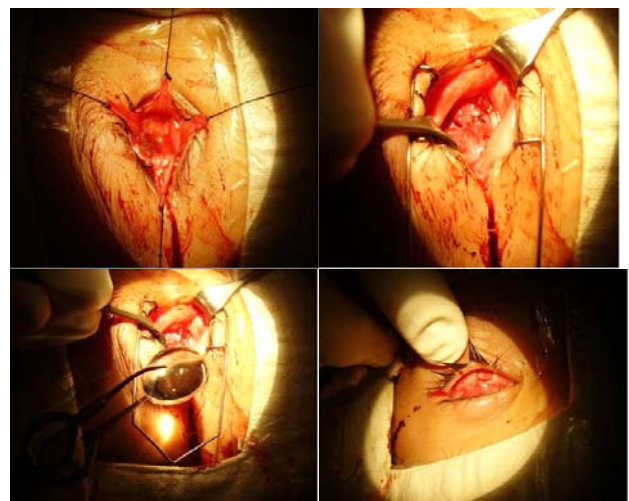
**Fig 1:** Sahaf enucleation implant (left open, right closed)



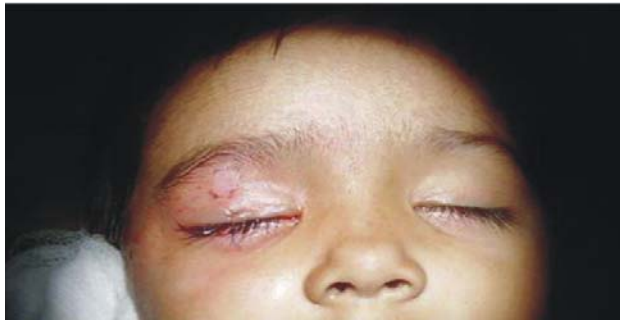**Fig 2:** Different sizes of Sahaf implant



**Fig 3 :** Diagrammatic presentation of Sahaf implant in socket



**Fig 4:** Technique of implantation



**Fig 5:** Posoperative fill of the socket after Sahaf implant.

In one case the anterior part of the implant was extruded. Later all those cases who had thin Tenon's fascia had a reinforcement by sclera or autogenous fascia lata. All cases had satisfactory socket fill (Fig. 4).

## DISCUSSION

Socket reconstruction following enucleation with the use of intraorbital implants provides better cosmesis and prosthetic motility. Porous hydroxy apatite implants from the natural coral give excellent results but have certain drawbacks like need of scleral wrapping and repeated infection. Other commercially available porous implants like MEDPOR (Porex Surgical, Newnan, GA, USA), derived from synthetic linear high-density polyethylene have similar problems. Moreover they are expensive and not readily available in Pakistan.

The Sahaf implant is readily available to the ophthalmologists in Pakistan whereas the porous implants have to be imported a process that takes several weeks.

In the present study we have used Sahaf enucleation implant made up of PMMA. In all the cases, Sahaf implants with same design and different sizes were used. Muscle-integrating options were found stable within the orbital socket and provided desired volume replacement. All patients had healthy socket and adequate fornices. Three cases showed minor post-surgical mild exposure problems, which were managed by reinforcement using autogenous fascia lata. All these three patients were on chemotherapy. One with extruded anterior part had combined chemo and radiotherapy.

In future we plan to put a scleral or fascia lata cover in all cases with possibilities of chemo or

radiotherapy. It also gives better adjustment initially to conformer and later to the prosthesis.

The technique of implantation is easy. Although 90% of the patients had good implant motility. Remaining patients had fair motility. The PMMA-based sahaf enucleation implants give homogenous outer surface. To overcome exposure problem in the present study, we used special smooth anterior surface of the implants which was covered in tenon and conjunctiva. Peculiar anterior surface of implant is smooth. The availability of different sizes allows good orbital fill (Fig. 4). Multiple sized posterior part helps in adapting to any muscle length. The multiple sizes of anterior part allow completing the orbital fill accurately.

The problem of growing orbit is also solved by exchanging the front part of larger sizes as the child grows with minimal intervention.

The present study indicates that the Sahaf PMMA orbital implant is safe and cosmetically acceptable after enucleation in human subjects. However, further long-term studies with larger number of patients are necessary.

## Author's affiliation

Dr Zahid Kamal Siddiqi  
 Assistant Professor  
 Eye Unit I  
 Lahore General Hospital, Lahore.  
 Dr Girdhari Lal  
 PGR, Eye Unit-I  
 Lahore General Hospital, Lahore  
 Dr Abdul Hye  
 Associate Professor  
 Eye Unit I  
 Lahore General Hospital, Lahore.

## REFERENCE

1. **Moshfeghi DM, Moshfeghi AA, Finger PT.** Enucleation. *Surv Ophthalmol.* 2000; 44: 277-301.
2. **Babr TF, Masud Z, Iqbal A, et al.** Should Ophthalmologist ever opt for Mutilating Operations like Evisceration, Enucleation and Exenteration? *Pak J Ophthalmol.* 2003; 19: 113-7.
3. **Ducasse A, Segal A, Gotzamanis A, et al.** Tolerance of orbital implants. Retrospective study on 14 years. *J Fr Ophthalmol.* 2001; 24: 277-81.
4. **Custer PL, Kennedy RH, Woog JJ, et al.** Meyer Orbital implants in enucleation surgery. *Ophthalmology.* 2003; 110: 2054-61.