

Case Report

Benign Retinal Flecks with Neuroretinitis

Muhammad Dawood Khan, Khawaja Khalid Shoaib, Inam-ul-Haq, Shahid Hamid, Kashif Ali
Muhammad Ahsan Mukhta

Pak J Ophthalmol 2008, Vol. 24 No. 2

.....
See end of article for
authors affiliations

.....
Correspondence to:
Khawaja Khalid Shoaib
Eye Specialist
CMH, Kharian Cantt

Received for publication
July' 2007
.....

Fleck retina is a heterogeneous category with massive mosaic hyaline excrescences of Bruch membrane, leading to the appearance of multiple deep yellow to yellowish white lesions of variable size and shape in the ocular fundus. Krill¹ in 1977 identified 4 classes: Fundus albipunctatus, inherited as either an autosomal dominant or autosomal recessive; Fundus flavimaculatus, inherited as an autosomal recessive; Familial drusen, inherited as an autosomal dominant and Fleck retina of Kandori², inherited as an autosomal recessive. In a consanguineous Arab Palestinian family, Sabel Aish and Dajani in 1980³ observed what they interpreted to be a fifth category, Familial benign fleck retina, inherited as an autosomal recessive.

Neuroretinitis is characterized by papillitis in association with inflammation of retinal nerve fiber layer.

CASE REPORT

We are presenting a case of benign fleck retina with neuroretinitis. To the best of our knowledge there is no reported case of benign fleck retina with neuroretinitis.

Our patient, forty five years old male, presented with history of visual loss in the right eye for the last six weeks which was rapid in onset and painless. There was no history of night blindness and family history was also not contributory.

Vision in right eye was counting fingers at two meters, not improving further and 6/6 in left eye. There was gross impairment of color vision in the right eye with relative afferent pupillary defect. Intraocular pressure was within normal limits in both eyes. Fundoscopy (Fig.1,2) revealed punctuate, well-demarcated, yellow-white flecks involving whole of the fundus except fovea in both eyes. Right optic disc had gross pallor, marginal blurring, and reduction in number of micro vessels associated with resolving macular fan. Left optic disc and macula were with in normal limits. There was no retinal pigmentation or vascular attenuation.

FFA (Fig. 3, 4) revealed hyperfluorescent spots in superotemporal perimacular vessels in both eyes in

early venous phase. There was diffuse leakage at the disc at late phase in right eye.

Serum Venereal Disease Research Laboratory (VDRL) test was non reactive and Treponema pallidum Haemagglutination Assay (TPHA) was negative.

All these findings were consistent with diagnosis of benign retinal flecks with neuroretinitis.

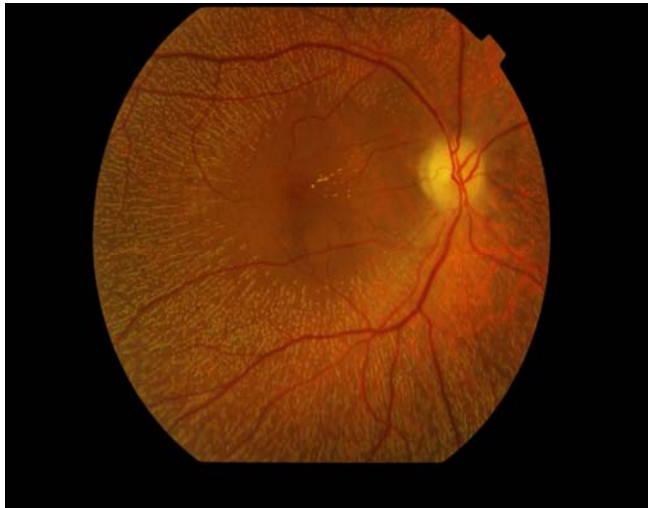

Fig. 1: Fundus photograph of right eye

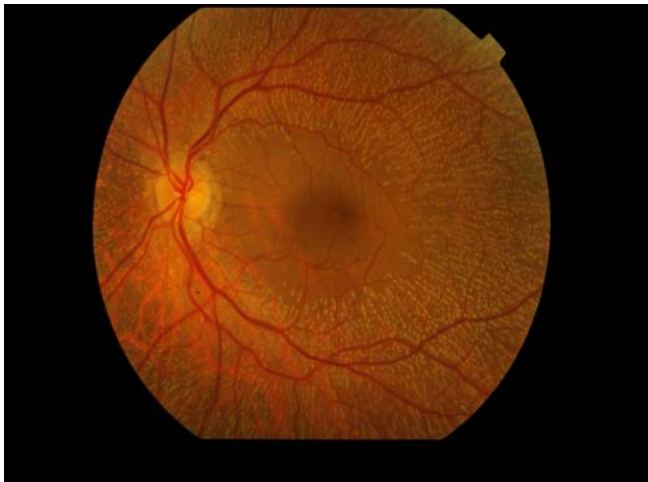

Fig. 2: Fundus photograph of left eye

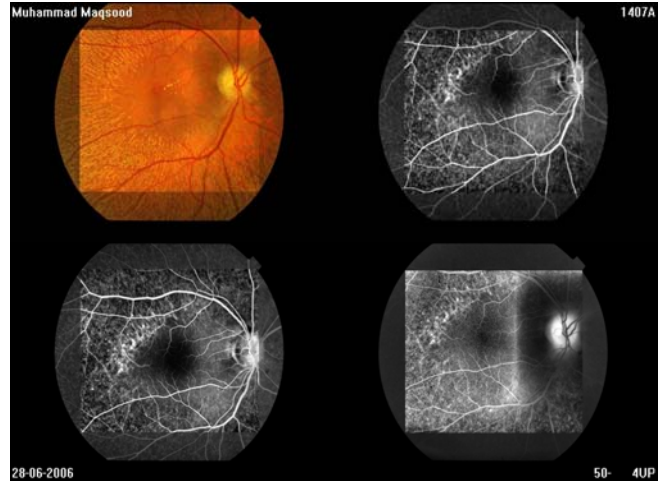

Fig. 3: fundus photograph and FFA right eye

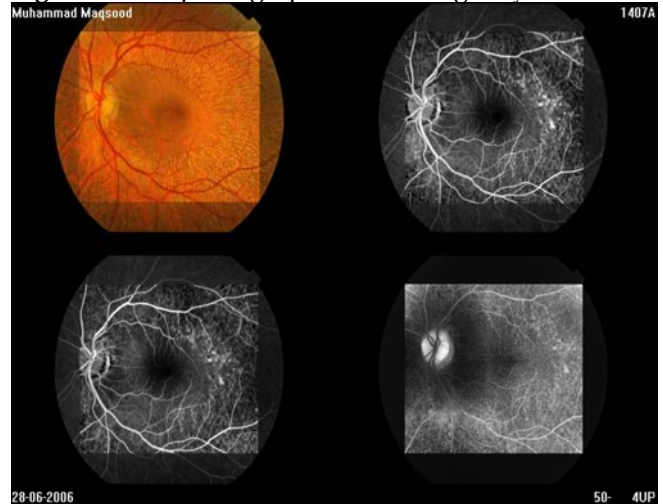


Fig. 4: Fundus photograph and FFA left eye

CASE DISCUSSION

Benign fleck retina is a very rare autosomal recessive disorder, which is asymptomatic and therefore usually discovered by chance⁴.

Inheritance

Autosomal recessive

Signs

- Widespread, discrete, yellow-white, flecks at the level of the RPE which spare the fovea.
- The flecks have variable shapes and extend to the far periphery⁵.

ERG

Electroretinogram is usually normal.

Prognosis

Prognosis is excellent because the retinal changes are innocuous.

Neuroretinitis is the least common type of optic neuritis and is most frequently associated with viral infections, cat-scratch fever, syphilis and Lyme disease. In most cases it is a self-limiting disorder, which resolves within 6-12 months.

Author's affiliation

Brig. Muhammad Dawood Khan
Combined Military Hospital
Kharian Cantt

Col. Khawaja Khalid Shoaib
Combined Military Hospital
Kharian Cantt

Inam-ul-Haq
Combined Military Hospital
Kharian Cantt
Shahid Hamid

Combined Military Hospital
Kharian Cantt

Kashif Ali
Combined Military Hospital
Kharian Cantt

Muhammad Ahsan Mukhta
Combined Military Hospital
Kharian Cantt

REFERENCE

1. **Krill A.** Hereditary Retinal and Choroidal Diseases: Flecked Retina Disease. 2nd ed. Hagerstown: Harper and Row; 1977. 739-819.
2. **Kandori F.** Very rare cases of congenital non-progressive night blindness with fleck retina. Jpn J Ophthalmol. 1959; 13: 384-6.
3. **Aish S, Dajani B.** Benign familial fleck retina. Br J Ophthalmol 1980; 64: 652-9
4. **Isaacs TW, McAllister IL, Wade MS.** Benign fleck retina. Letter to the editor. Br J Ophthalmol 1996; 80: 267-9.
5. **Kanski JJ.** Clinical Ophthalmology: A Systematic Approach. 5th ed. Edinburgh: Butterworth Heinemann; 2003

OBITUARY

LT. GEN MUSHTAQ AHMED BAIG, MBBS MCPS FCPS HI (M) (1951-2008)



February 25, 2008 will always remain in our memories as a very sad day. The news of a suicide bomb blast flashed across the media screens. Little did we realize that this time the victim would be one of our dearest colleague, Lieutenant General Mushtaq Ahmed Baig, head of the army's medical corps. A graduate of King Edwards Medical College, Lahore, Lt. Gen. Mushtaq Ahmad Baig joined Army Medical Corp in January 1976. Baig was awarded MCPS in Ophthalmology in 1977 and FCPS Ophthalmology in 1988 by College of Physicians and Surgeons Pakistan. He was promoted as Lieutenant General and appointed Surgeon General Pakistan Army and Director General Medical Services (Inter Services) on Feb 8, 2007. Presently he was serving as Principal Army Medical College, Rawalpindi. He was awarded Hilal-e-Imtiaz (Military), in recognition of his meritorious services.

In a reference held in his honour Miss Maryam Mushtaq, the daughter of Lieutenant General Mushtaq Ahmed Baig Shaheed described him as a "loving father, a caring husband, an obedient son, a responsible brother, an adept eye surgeon, a devoted soldier and above all a pious Muslim". He was a person who exuded great personal warmth and affection with a smiling and easy going approach to life. For a person of such a high rank it was a

rare trait. He was incisive in his thoughts and very organized in his work. He was a role model for medical profession. A large number of Ophthalmologists trained by him are serving throughout the country and it would be apt to say that he lives through his work. The irreparable loss and gap produced by his martyrdom will take years to fill. He is survived by his wife, three sons and a daughter. On behalf of the ophthalmic community we extend our deepest sympathies to the bereaved family and pray that they bear the loss with fortitude and forbearance.

Prof. Hamid Mahmood Butt

Prof. Brig. Asad Jamal Dar