

# Role of Laser Peripheral Iridoplasty in Acute Attack of Primary Angle Closure Glaucoma

P.S Mahar, Dilshad Laghari, Israr A. Bhutto

*Pak J Ophthalmol 2010, Vol. 26 No. 3*

.....  
See end of article for  
authors affiliations  
.....

Correspondence to:  
P.S. Mahar,  
Isra Postgraduate Institute of  
Ophthalmology  
Al-Ibrahim Eye Hospital  
Malir, Karachi

Received for publication  
December 2009  
.....

**Purpose:** To study the effect of laser peripheral iridoplasty (LPIp) on the intra ocular pressure (IOP) and the anterior chamber angle in the patients with an acute attack of primary angle closure glaucoma (PACG), non-responsive to the medical therapy.

**Materials and Methods:** The study was carried out at Isra Postgraduate Institute of Ophthalmology, Karachi, from April, 2005 to June, 2009. Sixteen patients with the mean age of 61.36 year SD  $\pm$  3.38 year, (10 female & 6 males) were treated with LPIp, when their IOP remained elevated with closed angle despite maximum medical treatment, comprising of intravenous Mannitol 20%, topical beta blocker and Pilocarpine.

**Results:** The pre-laser IOP of the patients ranged between 36 mmHg to 48 mmHg with mean IOP of 41.64mmHg SD  $\pm$  4.03mmHg. The post laser IOP measured at 1 hour ranged between 9 mmHg to 22 mmHg with the mean IOP of 14.36 SD  $\pm$  4.70 mmHg.

Pre-laser gonioscopy revealed total appositional closure of the angle in all 4 quadrants. After laser, 11 patients had grade II angle (Shaffer's classification), revealing posterior part of the trabecular meshwork in 2 quadrants, while 5 patients had grade II angle in all the quadrants.

**Conclusion:** LPIp is a safe and effective procedure in controlling the IOP in patients, with an acute attack of PACG, unresponsive to the medical therapy with opening of the anterior chamber angle

**A**n acute attack of Primary Angle Closure Glaucoma (PACG) constitutes a true ocular emergency. It is important to abort the attack with the reduction of the Intra Ocular Pressure (IOP) and opening of the anterior chamber angle, before permanent damage to the angle structure and optic nerve occurs. The management of an acute attack of PACG is achieved into two stages. First is to reduce the IOP and second is to relieve the angle closure. The reduction of the IOP is carried out by the intravenous use of hyper-osmotic agents such as Mannitol or carbonic anhydrase inhibitor (CAI) such as Acetazolamide. The topical medication to reduce IOP includes beta blockers and CAI. Once IOP is brought

under control, miotic therapy with Pilocarpine is initiated to constrict the pupil with opening of the angle. Miotic therapy is usually ineffective in the earlier phase of the attack, when the IOP is very high resulting in the ischemia of the iris<sup>1</sup>. It is mostly started once IOP is reduced. Pilocarpine instilled three hours after the topical use of beta blocker breaks the angle closure attack<sup>2</sup>. The eventual treatment is relieving the pupillary block by the Laser peripheral iridectomy (LPI)<sup>3</sup>.

There is a group of patients presenting with an acute attack of PACG in which conventional medical treatment fails to reduce the IOP, with the anterior chamber angle remaining occluded. Laser peripheral

iridoplasty (LPIp) has been used in this group of patients to mechanically open the close angle with the settling of the IOP<sup>4,5</sup>. LPIp involves the placement of contraction laser burns in the peripheral iris, resulting in its tightening, pulling it posteriorly away from the trabecular meshwork, and thus opening the anterior chamber angle with the decrease in IOP.

We performed LPIp on the patients with acute attack of PACG, where medical therapy failed to reduce the IOP and the anterior chamber angle remained closed. In this prospective study, LPIp was performed to demonstrate the effect of this procedure on the anterior chamber angle contour and on the level of IOP. The study approval was granted by the ethical and educational committee of the institute.

## MATERIAL AND METHODS

A total of 55 patients were treated with the clinical diagnosis of an acute attack of PACG at the Isra Postgraduate Institute of Ophthalmology/Al-Ibrahim Eye Hospital, Karachi, between April, 2005 to June, 2008. Sixteen of these patients failed to show any decrease in the IOP with the standard medical treatment. The patient's age ranged between 55 to 68 years with the mean age of 61.36 years SD  $\pm$  3.38 years. The gender distribution showed 6 male and 10 females. None of these patients had any previous history of glaucoma. The duration of the attack was between 2 to 5 days, determined by the onset of the patient's symptoms. The patient's snellen's vision was charted between 6/36 to counting fingers. Thirteen patients had initial treatment with topical Timolol maleate 0.5% (Betalol-Sante, Pakistan) and Pilocarpine 2% (Medicarpine-MediPak, Pakistan) along with intravenous Mannitol 20% in the dose of 1G/1kg body weight. The remaining three patients had topical instillations of topical CAI and Pilocarpine but intravenous Mannitol could not be given due to the medical history of congestive cardiac failure (CCF) in 2 patients and history of renal failure in 1 patient. The IOP of all these patients remained above the normal level, measuring between 36 to 48 mmHg, despite the initiation of medical treatment. Due to the high IOP with fine corneal edema and mid dilated pupils, LPI could not be performed because of the bunched up thick iris in the peripheral part.

After the informed consent, all patients received LPIp under topical anaesthesia with one drop of Proparacaine Hcl 0.5% (Alcaine-Alcon, Belgium) instilled in the affected eye. A double frequency YAG laser emitting green light in the wave-length of 532nm

was used (Ophthalas 532 Eyelite - Alcon USA). The laser setting comprised of spot size of 250-500 microns and duration between 0.2 to 0.5 seconds with the power use of 250-450 micro watts. The principle applied in the laser treatment is large area, long duration and low power to make the peripheral iris contract to pull away from the angle and not to burn<sup>6</sup>. The laser power is increased if no contraction of the iris is noticed, and power is reduced in the case of formation of gas bubble, liberation of iris pigment, charring of iris and pop noise causing burning of the iris. A double mirror Goldmann gonio lens or Ritch trabeculoplasty lens was used to focus the beam on the peripheral convex part of the iris away from the angle structures, striking tangentially. All quadrants of the iris were treated with 10-15 applications in the each quadrant. The end point of the laser treatment was the contraction of the iris at the area of the treatment. Patient's IOP was checked using Goldmann applanation tonometer (GAT) before the treatment and one hour after the laser application, followed at every day. After the laser, medical treatment continued with Timolol maleate 0.5% (Betalol-Sante, Pakistan) twice a day, and Pilocarpine 2% (Medicarpine-MediPak, Pakistan) three times a day and Brinzolamide 2% (Trusopt-MSD, France) three times a day (In patients with history of CCF) with the addition of Dexamethasone 0.1% (Maxidex-Alcon, Pakistan) four times a day, till the definitive treatment of LPI was undertaken.

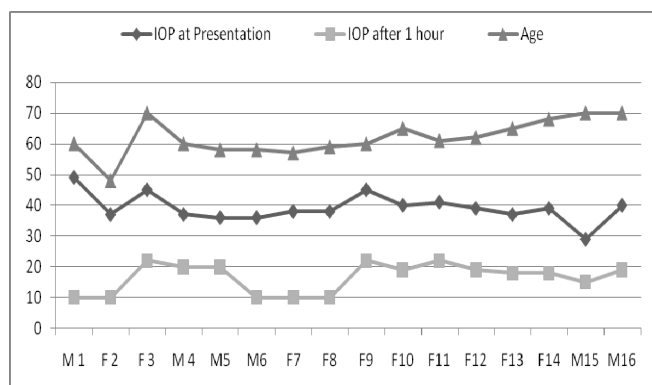
## RESULTS

Our functional success was defined when the IOP was brought under 22mmHg and the treated angle was opened to the posterior part of the trabecular meshwork, at least in 50% of the angle. Sixteen patients with the mean age of 61.36 years SD  $\pm$  3.38 years with an acute attack of PACG, failed to show drop in their IOPs with the standard medical treatment. LPIp was performed to open the angle in these patients. The results were analyzed on Microsoft Excel 2007 with data analysis pack. The pre-laser IOP measured between 36 mmHg to 48 mmHg with the mean IOP of 41.64 mmHg SD  $\pm$  4.03 mmHg. The post laser IOP at 1 hour ranged between 9 mmHg to 22 mmHg with the mean IOP of 14.36 mmHg SD  $\pm$  4.70 mmHg (Table 1). There was an overall drop of 26.28 mmHg SD  $\pm$  4.70 mmHg. All corneal edema cleared with the lowering of the IOP. The IOP remained controlled within the normal limits throughout the follow up period.

Pre-laser gonioscopy revealed total appositional closure of the angle in all the 4 quadrants of the patients. After laser, 11 patients had grade II angle (Shaffer's classification)<sup>7</sup>, revealing posterior part of the trabecular meshwork in at least 2 quadrants while 5 patients had grade II angle in all the quadrants.

There was mild iritis, present in all the patients after the laser procedure.

**Table I:** Patient's characteristics with profile of the IOP before and after LPIp



IOP = Intra ocular pressure, LPIp= Laser peripheral Iridoplasty, M=Male, F=Female

## DISCUSSION

The routine treatment to abort an attack of PACG involves starting patients on intravenous Mannitol or Acetazolamide to decrease the IOP substantially<sup>8</sup>, with the concomitant use of topical beta-blockers and Pilocarpine on the later stage. In this country, Acetazolamide is not available for the intravenous use, so along with Mannitol, oral CAI is used. The use of Mannitol is contraindicated in the patients with medical history of CCF (also beta-blockers) or compromised renal function<sup>9,10</sup>. Oral CAI can cause paraesthesia and confusion along with the serious side effects of metabolic acidosis,<sup>11,12</sup> Stevens Johnson syndrome<sup>13</sup> and blood dyscrasias<sup>14</sup>

Once the IOP is reduced, opening of the anterior chamber angle with Pilocarpine therapy and eventual treatment of LPI is carried out to relieve the pupillary block permanently. The opening of the anterior chamber angle is important with normalization of the IOP, otherwise permanent damage to the angle structure occurs with the formation of the Peripheral anterior synechiae (PAS), resulting in the damage to the optic nerve head, leading to the permanent loss of vision. In this situation, even LPI performed, does not

relieve the angle blockage and patient may require drainage surgery to control the IOP.

LPIp is therefore a simple procedure, carried out when medical therapy fails to reduce the IOP. The laser application makes the iris to contract away from the angle structures, with the opening of the angle, with due result of lowering of the IOP. The patient eventually receives LPI to prevent any further attack of the pupillary block.

The role of the LPIp was established way back in 1982 when Ritch<sup>5</sup> showed its usefulness in patients where medical treatment failed to reduce the IOP after an acute attack of PACG.

This procedure is not a replacement of LPI, which is still a definitive treatment to prevent any further pupillary block. LPIp is rather an adjunct to the medical treatment, to bring the IOP down by opening the anterior chamber angle. Lam and coworkers<sup>15</sup> examined the IOP lowering effect of an immediate LPIp as a first line treatment for an acute attack of PACG. In their preliminary study of 10 patients, mean IOP was reduced from  $59.5 \pm 10.4$  mmHg to  $28.7 \pm 14.9$  mmHg at 15 minutes,  $21.7 \pm 13.1$  mmHg at 30 minutes and  $16 \pm 9.4$  mmHg at 60 minutes. No complications from the laser procedure were noted and all patient's corneal edema cleared with lowering of the IOP. These authors<sup>16</sup> carried out a further prospective trial, where 33 eyes with an acute attack of PACG received immediate LPIp, whereas 40 eyes with similar attack had conventional systemic medical treatment. They concluded that, the LPIp treated eyes had lower IOP level then the medically treated group at 15 minutes, 30 minutes and 60 minutes, after the start of the treatment. Tham et al<sup>17</sup> studied the safety and efficacy of LPIp in patients with secondary angle closure glaucoma due to intumescent cataract. After LPIp, the mean IOP was reduced from  $56.1 \pm 12.5$  mmHg to  $34.2 \pm 9.7$  mmHg at 60 minutes.

Although we did not study if the duration of the attack had any bearing on the effectiveness of the medical or laser therapy but this has been shown by Lam et al<sup>16</sup> that there were no statistically significant differences in the IOP at each time point between the patients with shortage duration of attack and the patients with the longest.

Our patients only showed mild iritis after the procedure, treated successfully with the topical steroids. Other complications reported in the literature include, transient elevation of the IOP, corneal

endothelial burns, distortion of the pupil and focal iris atrophy<sup>18</sup>.

The advantage of LPIp is that, its early use can prevent formation of PAS, preventing conversion of acute to chronic angle closure glaucoma. Also some of the cases with an acute attack may have Plateau iris configuration, for which this laser would be the treatment of the choice<sup>19</sup>. The only contraindications for this procedure, is totally flat anterior chamber when laser application can cause corneal endothelial burn and presence of significant corneal edema which dissipates the effect of the laser<sup>20</sup>.

The usefulness of LPIp has been established in the western and in the far-eastern people of the Chinese origin. Although our series of patients is small but with the positive outcome of the laser treatment, we feel, this procedure should be employed in an acute attack of PACG, especially when routine medical treatment fails, to bring down the IOP or when medical treatment is contraindicated on certain medical grounds.

## CONCLUSION

LPIp can be carried out in the patients with an acute attack of PACG, when medical treatment fails to bring down the IOP or it can be used as a first line therapy in the acute attack, and lens related angle closure glaucoma. LPI however remains the definitive treatment for an acute attack of the PACG.

## Author's affiliation

Prof. P.S Mahar  
Isra Postgraduate Institute of Ophthalmology  
Al-Ibrahim Eye Hospital, Malir  
Karachi

Dr. Dilshad Laghari  
Isra Postgraduate Institute of Ophthalmology  
Karachi

Dr. Israr A. Bhutto  
Isra Postgraduate Institute of Ophthalmology  
Karachi

## REFERENCE

1. Charles ST, Hamasaki DI. The effect of IOP on the pupil size. Arch Ophthalmol. 1970; 83: 729-31.

2. Ganius F, Mapstine R. Miotic in closed angle glaucoma. Br J Ophthalmol. 1979; 63: 822-6.
3. Robin AL, Pollack IP. Argon laser peripheral iridectomies in the treatment of primary angle closure glaucoma. Arch Ophthalmol. 1982; 100: 919-23.
4. Wies HS, Shingleton BJ, et al. Argon laser goniotomy in the treatment of angle closure glaucoma. Am J Ophthalmol. 1991; 114: 14-8.
5. Ritch R. Argon laser treatment for medically unresponsive attacks of angle-closure glaucoma. Am J Ophthalmol. 1982; 94: 197-204.
6. Ritch R. Argon laser peripheral iridoplasty: an overview. J Glaucoma. 1992; 1: 206-18.
7. Kanski JJ. Clinical ophthalmology. Butterworth, 5<sup>th</sup> edition 2003; 202.
8. Smith EW, Drance SM. Reduction of human intraocular pressure with intravenous mannitol. Arch Ophthalmol 1962; 68: 734-41.
9. Spaeth GL, Spaeth EB, Spaeth PG, et al. Anaphylactic reaction to mannitol. Arch Ophthalmol. 1967; 78: 583-7.
10. Weaver A, Sica DA. Mannitol-induced acute renal failure. Nephron. 1987; 45: 233-8.
11. Chaparon DJ, Gomolin IH, Sweeney KR. Acetazolamide blood concentrations are excessive in the elderly: propensity for acidosis and relationship to renal function. Clin Pharmacol. 1989; 29: 348-53.
12. Cowan RA, Hartnell GG, Lowdell CP, et al. Metabolic acidosis induced by carbonic anhydrase inhibitors and salicylates in patients with normal renal functions. Br Med J (Clin Res Ed). 1984; 289: 347-8.
13. Shirato S, Kagaya F, Suzuki Y, et al. Stevens-Johnson syndrome induced by methazolamide treatment. Arch Ophthalmol. 1997; 115: 550-3.
14. Mogk LG, Cyrlin MN. Blood dyscrasias and carbonic anhydrase inhibitors. Ophthalmology. 1988; 95: 768-71.
15. Lam DS, Lai JS, Tham CC. Immediate argon laser peripheral iridoplasty as treatment for acute attack of primary angle closure glaucoma: a preliminary study. Ophthalmology. 1998; 105: 2231-6.
16. Lam DS, Lai JS, Tham CC, et al. Argon laser peripheral iridoplasty versus conventional systemic medical therapy in treatment of acute primary angle closure glaucoma: a prospective, randomized, controlled trial. Ophthalmology. 2002; 109: 1591-6.
17. Tham CCY, Lai JSM et al. Immediate argon laser peripheral iridoplasty (ALPI) initial treatment for acute phacomorphic angle closure (Phacomorphic Glaucoma) before cataract extraction, a preliminary study. Eye 2005; 19: 778-83.
18. Lai JSM, Tham CCY, Lam DSC. Immediate argon laser peripheral iridoplasty as immediate treatment for an acute attack of primary angle closure glaucoma: a preliminary study. Eye 1999; 13: 26-30.
19. Chew P, Chee C, Lim A. Laser treatment of severe acute angle closure glaucoma in dark Asian irides: the role of iridoplasty. Lasers Light Ophthalmol. 1991; 4: 129-32.
20. Lim ASM, Tan A, Chew P, et al. Laser iridoplasty in the treatment of severe acute angle closure glaucoma. Int Ophthalmol. 1993; 17: 33-6.