

Visual Effects of Intravitreal Triamcinolone Acetonide Injection in Patients with Refractory Diabetic Macular Edema

Khalid Mehmood, Baber Attique Malik, Muhammad Tariq Khan, Mirza Jamil ud Din Baig, Zaheer ud Din Aqil Qazi

Pak J Ophthalmol 2010, Vol. 26 No. 4

See end of article for authors affiliations

Correspondence to:
Khalid Mehmood
Department of Ophthalmology
Avicenna Medical College
DHA Phase IX Lahore

Received for publication
June' 2010

Purpose: The visual outcome in patients with refractory diabetic macular edema receiving intravitreal triamcinolone acetonide injection.

Materials and Methods: This was an interventional, prospective hospital based study conducted at LRBT Eye Hospital Lahore from Jan 2007 to Aug 2007. Fifty eyes of 50 patients received Intravitreal injection of triamcinolone in a single dose of 4mg/0.1 ml. visual acuity was measured preoperatively and at postoperative visit of 1 week, 1 month and 3 months using Snellen's Visual Acuity chart.

Results: Pre operatively there was 1 (2%) eye with VA > 6/18, 28 (56%) eyes with VA 6/24-6/60 and 21 (42%) eyes had VA <6/60. On third post operative month follow up visit day there were 6 (12%) eyes with VA > 6/18, 31 (62%) eyes with VA 6/24-6/60 and 13 (26%) eyes had VA <6/60.

There is statistically significant difference between the preoperative and postoperative visual acuity, $p=0.005$.

Conclusion: This study suggests that Intravitreal injection of triamcinolone acetonide in a dose of 4mg/0.1ml considerably improved vision in patients with diffuse diabetic macular edema refractory to previous macular grid photocoagulation at three months after the injection.

Blindness is one of the most feared complications of diabetes but also one of the most preventable¹. Proliferative diabetic retinopathy and diabetic macular edema are the most common causes of blindness not only in Pakistan but also all over the world².

Visual impairment in diabetic patients is usually due to involvement of the fovea³. Laser photocoagulation reduces the risk of moderate visual acuity loss for all eyes with diabetic macular edema by about 50% as demonstrated by Early Treatment Diabetic Retinopathy Study [ETDRS]. Results show that for some patients, laser photocoagulation is effective but treated eyes often develop moderate visual loss inspite of the treatment⁴. The frequency of an unsatisfactory outcome following laser photocoagulation in eyes in diabetic macular edema has prompted interest in other

treatment modalities. Intravitreal injection of triamcinolone acetonide has emerged as a promising therapy for diabetic macular edema refractory to conventional laser photocoagulation^{5,6}.

This modality was first proposed in 1999 as a treatment for refractory diabetic macular edema due to its effect of attenuating the vascular endothelial growth factor (VEGF) mediated retinal capillary permeability that is presumed to be a contributing factor in its pathogenesis. Intravitreal triamcinolone acetonide is effective in improving vision, reducing macular thickness and inducing reabsorption of hard exudates. Jonas JB and coworkers on the use of Intravitreal triamcinolone acetonide suggest that this treatment resulted in reducing the macular edema and improvement of visual acuity in diabetic patients⁷.

The aim of this study was to evaluate the visual

outcome with Intravitreal triamcinolone acetonide injection in patients with refractory diabetic macular edema.

MATERIALS AND METHODS

This was an interventional prospective hospital based study. Patients were selected from the outpatient department of LRBT eye hospital, Lahore. Fifty eyes of 50 patients were included in this study ranging between 44 – 64 years of age. All patients had nonproliferative diabetic retinopathy with unresolved diffuse exudative diabetic maculopathy with previous macular grid photocoagulation. Preoperatively visual acuity with Snellen’s Visual Acuity chart and intraocular pressure with Goldman’s tonometer were recorded.

Slit lamp examination of anterior segment and detailed dilated fundus examination with Volk superfield non-contact lens was performed in all patients. Digital fundus fluorescein angiography was done in all patients but this was not taken as a reference point. All patients underwent an Intravitreal injection of triamcinolone acetonide 4mg/0.1ml under topical anesthesia through pars plana 3.5 mm from limbus with a small-bore needle (27 gauge). The procedure was done in operation theatre under strict aseptic conditions. Topical anaesthesia was given in the form of a cotton vick soaked in 2% lignocaine solution kept in lower fornix for 2 minutes with a single drop of proparacaine hydrochloride 0.5% just before inserting the needle. Eye was padded for 4 hours. A combination of ofloxacin and dexamethasone topical eye drops was given 4 times a day for 1 week. Postoperative visual acuity, intraocular pressure, slit lamp examination of anterior segment and dilated fundus examination were performed in all patients on 1 week, 1 month and 3 months interval.

RESULTS

There were 27 (54%) males and 23 (46%) females. The age range was from 44-64 years with a mean age of 53.2 years with standard deviation of 4.76 years.

Pre operatively there was 1 (2%) eye with VA >6/18, 28 (56%) eyes with VA 6/24-6/60 and 21 (42%) eyes had VA <6/60. Pre-operatively intraocular pressure range was from 10-16 mmHg. Mean IOP was 13.12 mmHg with standard deviation of 8.51 mmHg.

On first post operative week there was 1 (2%) eye with VA > 6/18, 28 (56%) eyes with VA 6/24-6/60 and 21 (42%) eyes had VA <6/60.

On first post operative month, there were 8 (16%) eyes with VA > 6/18, 38 (76%) eyes with VA 6/24-6/60 and 4 (8%) eyes had VA <6/60.

On third post operative month, there were 6 (12%) eyes with VA > 6/18, 31 (62%) eyes with VA 6/24-6/60 and 13 (26%) eyes had VA <6/60.

There was a statistically significant difference between the preoperative and postoperative visual acuity, p=0.005.

Postoperative intraocular pressure range was from 10-40 mmHg. Mean IOP was 19.86 mmHg with standard deviation of 8.51 mmHg. Secondary glaucoma developed in 18 (36%) eyes which was successfully treated with topical medication in all patients. Cataract developed in 2 (4%) eyes. One (2%) eye developed postoperative endophthalmitis while 29 (58%) eyes developed no postoperative complications.

DISCUSSION

Diabetic retinopathy is the leading cause of blindness in patients aged more than 50 years in our country. Among them macular edema is the main reason of reduced vision in this population. Diffuse macular edema is one of the most intractable complications of diabetic retinopathy⁸.

This was a hospital based prospective study to evaluate the visual outcome in patients with diabetic macular edema refractory to previous macular grid photocoagulation after administering intravitreal triamcinolone acetonide injection.

Intravitreal triamcinolone acetonide has increasingly been used in previous studies as treatment for intraocular proliferative, edematous, and neovascular diseases⁹⁻¹¹.

Table 1: Post operative complications

Complications	No. of eyes n (%)
Secondary glaucoma	18 (36)
Cataract	2 (4)
Endophthalmitis	1 (1)

The results of our study showed that Intravitreal triamcinolone acetonide may be useful in increasing VA in patients with diffuse diabetic macular edema. Postoperative VA showed a significant increase in VA as compared to the preoperative VA, expressed on Snellen’s Visual Acuity chart. Our results are

comparable to the results of J B Jonas and coauthors¹² who also reported the similar results.

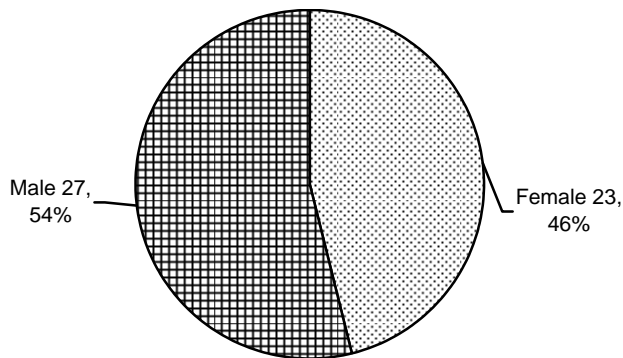


Fig. 1: Gender Distribution

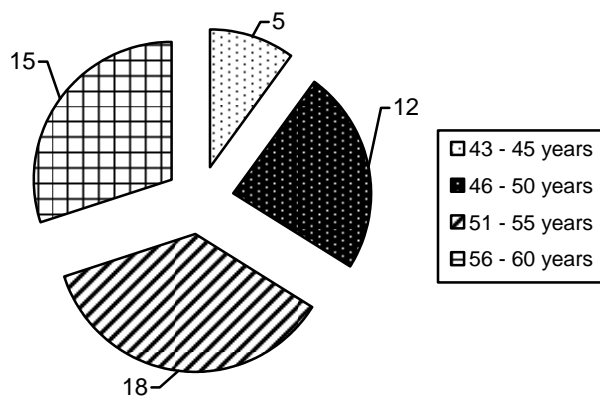


Fig. 2: Number of patients with age distribution

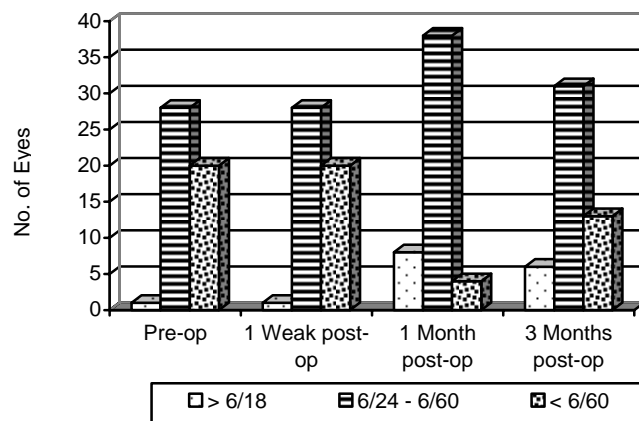


Fig. 3: Comparison of pre and post-operative visual acuity

Based on the results of present study and in agreement with other studies¹³ it may be inferred that patients with persisting diffuse macular edema may

undergo Intravitreal injection of triamcinolone acetonide in a controlled manner.

This study supported that the use of Intravitreal injection of triamcinolone acetonide improved visual acuity in patients with refractory diabetic macular edema. Another study conducted by J B Jonas and coauthors showed that intravitreal injection of triamcinolone acetonide can increase visual acuity in patients with diffuse macular oedema¹⁴.

Another study conducted by Nadeem Ishaq showed that Intravitreal injection of triamcinolone acetonide was a promising therapy for patients with diabetic macular edema refractory to laser treatment. It was effective in improving vision, reducing macular thickness and inducing re absorption of hard exudates¹⁵.

Our study is comparable to the above mentioned studies in that intravitreal injection of triamcinolone acetonide resulted in improvement in visual acuity in patients with refractory diabetic macular edema.

One limitation of this study might be that, although intravitreal injection of triamcinolone acetonide will have increased the degree of cataract, cataract surgery was not performed in combination with, or after, the intravitreal injections of triamcinolone acetonide during follow up. The vision reducing effect of progressive cataract, however, might have hidden parts of a vision improving effect of triamcinolone so that this limitation of the study might serve to support the conclusion.

The main side effect of intravitreal injection of triamcinolone acetonide observed in the present study was an increase in IOP. Eighteen (36%) eyes developed maximal IOP measurements higher than 21 mmHg. As is described in other studies,¹⁶ the secondary glaucoma could usually be treated by topical beta blockers and carbonic anhydrase inhibitor anti glaucoma medications without the development of glaucomatous optic nerve damage.

CONCLUSION

Macular edema in diabetic patients is a major factor of visual impairment. Intravitreal triamcinolone acetonide is effective alternative treatment for eye with diabetic macular edema refractory to medical and laser treatments. This study suggests that intravitreal injection of triamcinolone acetonide in a dose of 4mg/ 0.1ml improve visual outcome in patients with diffuse

diabetic macular edema during the first three months after the injection.

Author's affiliation

Dr. Khalid Mehmood
Associate Professor of Ophthalmology
Avicenna Medical College
Lahore

Dr. Baber Attique Malik
Consultant
Laser Vision Eye Center
Lahore

Dr. Muhammad Tariq Khan
Consultant Ophthalmologist
LRBT Eye Hospital
Lahore

Dr. Mirza Jamil ud Din Baig
Senior Ophthalmologist
LRBT Eye Hospital
Lahore

Dr. Zaheer ud Din Aqil Qazi
Chief Consultant Ophthalmologist
LRBT Eye Hospital
Lahore

REFERENCE

1. **Haider SA.** Blindness and Diabetic Retinopathy. Pak J Ophthalmol. 2001; 17: 42.
2. **Kanski JJ.** Clinical ophthalmology. A systematic approach 5th ed. Butter worth I leinemann; Oxford. 2003: 445.
3. Early treatment diabetic retinopathy study Research Group. Retina and Vitreous Sec 12. American Academy of Ophthalmology. USA. 2003-04: 99.
4. **Jonas JB, Sofker A.** Intraocular injection of crystalline triamcinolone as adjunctive treatment for diabetic macular edema. Am J Ophthalmol. 2001; 132: 425-7.
5. **Jonas JB, Kreissig I, Sofker A, et al.** Intravitreal triamcinolone injection for diffuse diabetic macular edema. Arch Ophthalmol. 2003; 121: 57-61.
6. **David NZ, Mark WJ.** Combined intravitreal injection of triamcinolone acetonide and pan retinal photocoagulation for concomitant diabetic macular edema and proliferative diabetic retinopathy. Retina. 2005; 25: 135-40.
7. **Jonas JB, Kreissig I, Sofker A, et al.** Intravitreal injection of triamcinolone for diffuse diabetic macular edema. Arch Ophthalmol. 2003; 121: 57-61.
8. Early Treatment Diabetic Retinopathy Study Group. ETDRS report no. 11. Classification of diabetic retinopathy from fluorescein angiograms. Ophthalmology. 1991; 98: 807-22.
9. **Greenberg PB, Martidis A, Rogers AH, et al.** intravitreal triamcinolone acetonide for macular edema due to central retinal vein occlusion. Br J Ophthalmol. 2002; 86: 247-8.
10. **Jonas JB, Sofker A.** intravitreal triamcinolone acetonide for cataract surgery with iris neovascularization. J Cataract Refract Surg. 2002; 28: 2040-1.
11. **Martidis A, Duker JS, Puliafito CA.** intravitreal triamcinolone for refractory cystoid macular edema secondary to birdshot retinochoroidopathy. Arch Ophthalmol. 2001; 119: 1380-3.
12. **Jonas JB, Akkoyun I, Kreissig I, et al.** Diffuse diabetic macular oedema treated by intravitreal triamcinolone acetonide: a comparative, non-randomized study. Br J Ophthalmol. 2005; 89: 321-6.
13. **Massin P, Audren F, Haouchine B, et al.** Intravitreal triamcinolone acetonide for diabetic diffuse macular oedema: preliminary results of a prospective controlled trial. Ophthalmology. 2004; 111: 218-24.
14. **Nadeem Ishaq.** Al-Shifa Journal of ophthalmology. 2005; 1: 30-3.
15. **Wingate RJ, Beaumont PE.** Intravitreal triamcinolone and elevated intraocular pressure. Aust N Z J Ophthalmol. 1999; 27: 431-2.
16. **Jonas JB, Kreissig I, Degenring RF.** Secondary chronic open angle glaucoma after Intravitreal injection of triamcinolone acetonide. Br J Ophthalmol. 2003; 87: 24-7

Phacoemulsification in hard nuclear cataract.

Mostly stay within the bag away from posterior capsule and corneal endothelium. Use good quality viscoelastic VERY FREQUENTLY.

Prof. M. Lateef Chaudhry
Editor in Chief