

Comparison of Raised IOP after Pars Plana Vitrectomy (Ppv) Using 1000 cSt and 5000 cSt Silicone Oil in Rhegmatogenous Retinal Detachment

Azizur Rahman, Munawer Hussain, Muhammad Fayaz, Mazharul Hassan, Muhammad Nasir Bhatti, Asif Mashood Qazi

Pak J Ophthalmol 2011, Vol. 27 No. 1

See end of article for authors affiliations

Correspondence to:
Azizur Rahman
Isra postgraduate institute of Ophthalmology,
Al-Ibrahim Eye Hospital,
Old Thaana, Malir, Karachi

Received for publication
November 2010

Purpose: To compare raised intraocular pressure after pars plana vitrectomy using 1000 cSt and 5000 cSt silicone oil.

Materials and Methods: This Interventional quasi experimental study was conducted at Isra Postgraduate Institute of Ophthalmology, Al-Ibrahim Eye Hospital, Malir, Karachi; from January 2008 to June 2008. Study included total 60 eyes of 60 patients fulfilling the inclusion criteria. All cases were worked up according to the protocol. After examination, patients were divided into two groups. Group A were injected with 1000 cSt silicone oil and group B were injected with 5000 cSt silicone oil on randomized basis. Patients were followed up at 1st day 1st week, 2nd week, 1st month, 2nd month 3rd month and 6th month. Complete eye examination including IOP measurement was done on each visit. Data analysis was done by SPSS version 10.0

Results: Over a follow up period of 6 months, there was no significant difference in raised intraocular pressure after using 1000 cSt and 5000 cSt silicone oil injection.

Conclusions: Difference in IOP was observed between the study groups on three months follow-up. However, there was no significant difference in raised intraocular pressure after 6 months of the intervention.

Raised intraocular pressure (IOP) is common in the immediate postoperative period after silicone oil injection in both phakic and aphakic eyes^{1,2}. This rise in the IOP is probably related to anterior chamber activity, obstruction to the aqueous flow by choroidal effusion, a buckle, or both. In most cases, it is short lived, easily controlled, and resolves spontaneously, but in some instances, particularly in highly myopic eyes, the angle closes permanently, and glaucoma becomes a chronic problem.

Glaucoma has long been recognized as a late complication of silicone oil injection. Late silicone oil induced glaucoma is probably due to trabecular blockage by emulsified oil in the anterior chamber.

There is no doubt that in a small number of aphakic eyes injected with silicone oil, it will come to occupy the anterior chamber, at least in the upper half or two third, preventing free flow of aqueous to the angle or blocking the pupil. Persistently raised IOP then becomes increasingly difficult to control medically, so that in such cases, permanent visual loss occurs due to optic atrophy as a result of failed medical treatment, or desperate surgical measures may have to be undertaken.

Despite the progress in vitreoretinal surgery and the importance of silicone oil as an adjunct for the treatment of complex forms of retinal detachment, controversy still surrounds the issue of selecting the proper oil viscosity for clinical use^{3,4}. Herein, we

compare the rise in intraocular pressure after injecting 1000 cSt and 5000 cSt silicon oil.

MATERIALS AND METHODS

The study included 60 eyes of 60 consecutive patients who underwent pars plana vitrectomy with silicone oil injection during January to June 2008 at Isra Postgraduate Institute of Ophthalmology, Al-Ibrahim Eye Hospital, Karachi. The patients were 20-70 years old. Those patients with previous history of retinal detachment surgery in the same eye, with primary or secondary glaucoma, and with traumatic or tractional retinal detachment were excluded.

Written informed consent was taken prior to procedure. Preoperatively history was taken about any previous retinal detachment surgery and glaucoma surgery or medication. Patients were selected from surgical retina clinic of Al- Ibrahim Eye Hospital. All patients underwent pars plana vitrectomy (PPV) with silicone oil injection. Intra ocular pressure was checked with applanation tonometer. Gonioscopy was done with Goldman single mirror gonioscope. The intra ocular pressure was measured on 1st day, 1st week, 2nd week, 1st month, 2nd month, 3rd month and 6th month postoperatively. Other anterior segment and posterior segment findings were noted on proforma and analyzed subsequently.

Patients were divided into two groups. Group (A) were injected with 1000 cSt silicone oil and group (B) were injected with 5000 cSt silicone oil on randomized basis. Sixty envelopes were made, 30 of group A and 30 of group B. The patients were asked to pick up one envelop for group allocation.

STATISTICAL ANALYSIS

Data analysis was performed through SPSS version 10.0. The data was analyzed using Fisher's exact test, student's t-test (unpaired), analysis of variance (ANOVA) and Post Hoc Scheffe's test. Statistical significance was taken at $p \leq 0.05$.

RESULTS

Among the 60 patients who received silicone oil injections, 51 (85%) were males and 9 (15%) females (M: F=5.7: 1). The gender distribution in subgroup of different viscosities of silicone oil is shown in Fig. 1.

Mean age of patients who received 1000 cSt silicone oil injection was 45.2 ± 15.6 and of those who

received 5000 cSt silicone oil injection was 38.6 ± 13 years. Although it was higher in the group who received 1000 cSt silicone oil injection but this difference was statistically insignificant ($p=0.080$).

Preoperative intraocular pressure (IOP) of patients who received 1000 cSt silicone oil injection was 12.67 ± 4.05 and of those 5000 cSt was 12.07 ± 5.57 , $p=0.635$. Mean IOP 3 months after surgery was significantly higher in the group of patients who received 5000 cSt silicone oil injection (16.27 ± 4.19 vs. 13.67 ± 3.24 , $p=0.009$).

Preoperative mean IOP of 30 patients who received 5000 cSt silicone oil injection was 12.1 ± 5.6 which increased to 17.4 ± 7.8 on postoperative day-1 and 17.3 ± 7.0 on 1 week follow up. Later on a decreasing trend of mean IOP was seen after 2 weeks follow up but again it increased to 16.9 ± 7.5 after one month, 16.1 ± 5.1 at two months, 16.3 ± 4.2 at 3 months and 14.3 ± 2.8 at 6 months.

Preoperative mean IOP of 30 patients who received 1000 cSt silicone oil injection was 12.67 ± 4.05 which increased to 14.9 ± 6.7 on postoperative day-1 and 16.3 ± 6.0 on 1 week follow up. Later on a decreasing trend of mean IOP was seen on 2 weeks, one month, two months, 3 months and 6 months of follow up. A significant difference between the preoperative mean IOP and postoperative mean IOP, taken on different time intervals, was observed at $p \leq 0.05$.

Repeated measure ANOVA reveals statistically significant difference of trend of IOP on different follow up readings ($F=4.01$, $p=0.050$) within and between the groups of patients who received 1000 cSt versus 5000 cSt silicone oil injection as shown in Fig. 2.

DISCUSSION

Since the invention of the vitrectomy surgery, the role of silicone oil as a vitreous substitute and retinal tamponade has expanded. Various viscosities of silicone oil have been used and studies have shown no difference in the tamponading force of them^{3,5}.

Low viscosity silicone oils are preferred by some surgeons because of easier surgical handling and removal from the vitreous cavity^{4,6,7}. On the other hand, higher viscosity silicone oils are subject to decreased and delayed emulsification, so that the tamponading force lasts longer, which may provide better tamponade for some complex forms of retinal detachment that need a longer effect⁴.

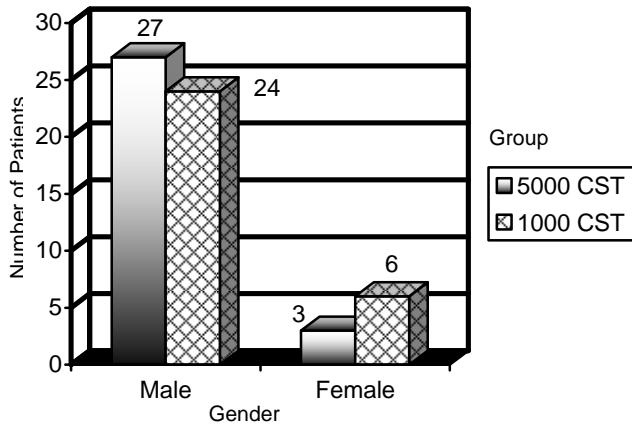


Fig. 1: Gender distribution between two groups of silicone oil

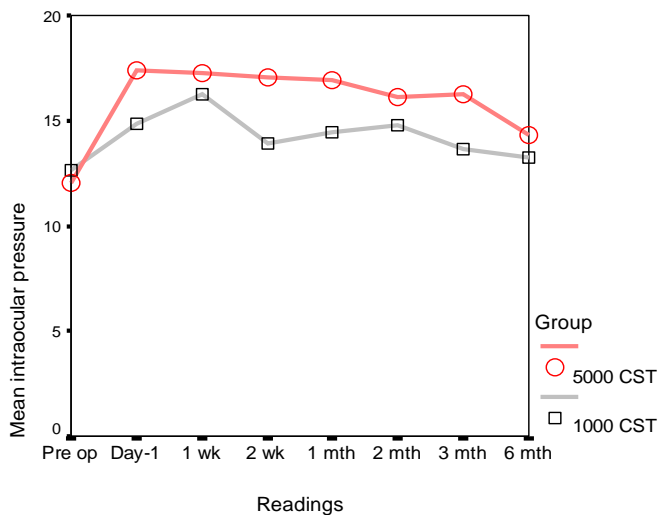


Fig. 2: Trend of IOP following 1000 cSt versus 5000 cSt on subsequent follow ups:

Early postoperative rise in the IOP is common after PPV with silicone oil injection in both phakic and aphakic eyes. This rise in the IOP is possibly related to anterior chamber inflammatory activity, obstruction to aqueous flow by choroidal effusion, a buckle or both^{8,9}.

The incidence of raised IOP varies from 3-40%¹⁰⁻¹². Silicone study report observed a prevalence of chronically elevated IOP of 8% in patients treated with conventional silicone oil¹³.

In this study we compared the intraocular pressure after successful complex retinal detachment surgery following silicone oils of two different viscosities, 1000 cSt and 5000 cSt.

The incidence of IOP elevation after silicone oil injection has been described in case series using 1000 cSt silicone oil. Honavar et al reported the overall incidence of glaucoma after PPV and silicone oil injection at 40% (60 of 150 eyes)¹¹. Nguyen et al reported a 48% (24 of 50 eyes) incidence of glaucoma after PPV and silicone oil injection¹⁴. Valone and McCarthy reported a 23% (11 of 48 eyes) incidence of glaucoma after PPV and silicone oil injection¹⁵. Billington et al reported a 29% (16 of 55 eyes) incidence of glaucoma after PPV and silicone oil injection¹⁶. In a case series that included patients treated with 5000 cSt silicone oil, Henderer et al found elevated IOP in 12.9% at 6 months, 21% at 1 year and 29.5% at 2 years¹².

Our results suggested that difference of mean IOP was statistically insignificant in both groups on day-1, one week, two weeks, one month, two months and six months. Mean IOP 3 months postoperatively was significantly higher in the group B patients who received 5000 cSt silicone oil injection.

Preoperative mean IOP of 30 patients who received 1000 cSt silicone oil injection was 12.67±4.05 which increased to 14.9±6.7 on postoperative day-1 and 16.3±6.0 on 1 week follow up. Later on a decreasing trend of mean IOP was seen on 2 weeks, one month, two months, 3 months and 6 months of follow up. A significant difference between the preoperative mean IOP and postoperative mean IOP, taken on different time intervals, was observed at p≤0.05.

Preoperative mean IOP of 30 patients who received 5000 cSt silicone oil injection was 12.1±5.6 which increased to 17.4±7.8 on postoperative day-1 and 17.3 ±7.0 on 1 week follow up. Later on a decreasing trend of mean IOP was seen after 2 weeks follow up but again it increased to 16.9 ±7.5 after one month, 16.1 ±5.1 at two months, 16.3 ±4.2 at 3 months and 14.3 ±2.8 at 6 months. A significant difference between the preoperative mean IOP and postoperative mean IOP after 1st postoperative week was observed while it was not statistically significant with mean IOP taken on different time intervals at p≤0.05.

CONCLUSION

Difference in IOP was observed between the study groups A & B on three months follow up. However, there was no significant difference in raised intraocular pressure after 6 months of the intervention.

However, a randomized controlled study is necessary to further evaluate and confirm this effect.

Author's affiliation

Dr Azizur Rahman

Isra Postgraduate Institute of Ophthalmology
Al-Ibrahim Eye Hospital, Malir, Karachi

Dr Munawer Hussain

Isra Postgraduate Institute of Ophthalmology
Al-Ibrahim Eye Hospital, Malir, Karachi

Dr Muhammad Fayaz

Isra Postgraduate Institute of Ophthalmology
Al-Ibrahim Eye Hospital, Malir, Karachi

Dr Mazharul Hassan

Isra Postgraduate Institute of Ophthalmology
Al-Ibrahim Eye Hospital, Malir, Karachi

Dr Muhammad Nasir Bhatti

Isra Postgraduate Institute of Ophthalmology
Al-Ibrahim Eye Hospital, Malir, Karachi

Dr Asif Mashood Qazi

Isra Postgraduate Institute of Ophthalmology
Al-Ibrahim Eye Hospital, Malir, Karachi

REFERENCE

1. **Popovic SS, Sikic J, Pokupec R.** Intraocular pressure values following vitrectomy with silicone oil tamponade. *Acta Med.Croatica.* 2005; 59: 143-6.
2. **Al-Jazzaf AM, Netland PA, Charlec A.** Incidence and management of elevated ontraocular pressure after silicone oil injection. *J.Glaucoma.* 2005; 14: 40-6.
3. **Soheilian M, Peyman GA, Moritera T, et al.** Experimental retinal tolerance to very low viscosity silicone oil (100 cs) as a

4. **Heidennkummer HP, Kampik A, Thierfelder S.** Experimental evaluation of in vitro stability of purified polydimethylsiloxanes (silicone oil) in viscosity ranges from 1000 to 5000 centistokes. *Retina.* 1992, 12: 828-32.
5. **De Juan E Jr, McCuen B, Tiedman J.** Intraocular tamponade and surface tension. *Surv Ophthalmol.* 1985, 30: 47-51.
6. **Crisp A, De Juan E, Tiedman J:** Effect of silicone oil viscosity on emulsification. *Arch Ophthalmol.* 1987, 105: 546-50.
7. **Parrel JM.** Silicone oil: physiochemical properties. In *Retina Volume 3.* Edited by: Glaser BM, Michels RG. St. Louis: CV Mosby. 1989: 261-77.
8. **Gallemore RP, McCuen BW.** Silicone oil in vitreoretinal surgery. In: Ryan SJ, editor. *Retina.* 3rd ed. St. Louis: Mosby. 2001; 2195- 220.
9. **Allingham RR.** *Shield's text book of Glaucoma.* 5th ed. Philadelphia: Lippincott, Williams and Wilkins. 2005: 410-33.
10. **Azen SP, Scott IU, Flynn Jr HW, et al.** Silicone oil in the repair of complex retinal detachments. A prospective observational multicenter study. *Ophthalmology.* 1998; 105: 1587-97.
11. **Honavar SG, Goyal M, Majji AB, et al.** Glaucoma after pars plana vitrectomy and silicone oil injection for complicated retinal detachments. *Ophthalmology.* 1999; 106: 169-76.
12. **Henderer JD, Budenz DL, Flynn HW, et al.** Elevated intraocular pressure and hypotony following silicone oil retinal tamponade for complex retinal detachment: incidence and risk factors. *Arch Ophthalmol.* 1999; 117: 189-95.
13. **Barr CC, Lai MY, Lean JS, et al.** II Postoperative intraocular pressure abnormalities in the Silicone Study. *Silicone Study Report 4.* *Ophthalmology.* 1993; 100: 1629-35.
14. **Nguyen QH, Lloyd MA, Heuer DK, et al.** Incidence and management of glaucoma after silicone oil injection for complicated retinal detachment. *Ophthalmology.* 1992; 99: 1520-6.
15. **Valine J Jr, McCarthy M.** Emulsified anterior chamber silicone oil and glaucoma. *Ophthalmology.* 1994; 101: 1908-12.
16. **Billington BM, Leaver PK.** Vitrectomy and fluid/silicone oil exchange for giant retinal tears: Results at 18 months. *Graefes Arch Clin Exp Ophthalmol.* 1986; 224: 7-10.