

Assessment of the Complications Secondary to Silicone Oil Injection after Pars Plana Vitrectomy in Rhegmatogenous Retinal Detachment in Early Post Operative Phase

Mazhar-ul-Hassan, Asif Kazi, Umair Qidwal, Aziz ur Rehman, Nasir Bhatti

Pak J Ophthalmol 2011, Vol. 27 No. 2

See end of article for authors affiliations

Correspondence to:
Mazhar-ul-Hassan
Isra Postgraduate Institute of Ophthalmology, Al-Ibrahim Eye Hospital, Malir, Karachi

Submission of Paper
August ' 2010

Acceptance for publication
May' 2011

Purpose: To assess the postoperative complications of silicone oil injection after pars plana vitrectomy in rhegmatogenous retinal detachment.

Materials And Method: The study was carried out at vitreo-retinal unit of Al-Ibrahim Eye Hospital, from January 2009 to June 2009. 100 eyes with rhegmatogenous retinal detachment according to inclusion and exclusion criteria were included in the study.

Results: Out of 100 patients included in the study, 43 had raised intraocular pressure, while the rest of 57 patients did not show any rise in intraocular pressure after three months of follow up, all 100 (100%) patients developed some form of change in their refractive status, only 6 (6%) patients developed band keratopathy till 3rd month of follow up, while only 8 (8%) had silicone oil emulsification in their eye in 3 month follow ups.

Conclusion: Raised intraocular pressure and change in refractive status were the two most common complications seen in our study; both of these complications can be managed easily.

The silicone oil is a useful tamponading material used in complex vitreoretinal surgery¹. It is transparent, lighter than water (specific gravity of 0.97) and has a refractive index of 1.404. The silicone oil has a surface tension with water of 40 mN/m, which is less than that of a gas bubble.² Primary vitrectomy for rhegmatogenous retinal detachment is fast becoming a procedure of choice.³ The silicone oil is most frequently indicated in rhegmatogenous retinal detachments for cases complicated by proliferative vitreoretinopathy, giant retinal tears, rhegmatogenous or combined retinal detachment due to proliferative diabetic retinopathy, ocular trauma, retinal detachment complicated by iris neovascularization, patient noncompliance with positioning and postoperative fluid - gas exchange and need for air travel by patient. The use of silicone oil as an endo-tamponade for the treatment of

complicated retinal detachment is common, but post operative complications can occur.⁴

Post Operative complications are increased intraocular pressure (40.57%), changes in refractive status (100%), band keratopathy (21.73%), silicone oil emulsification (56%). To prevent these complications, the silicone oil has to be removed from eye after 3 to 6 months of injection.⁵⁻⁷

This study is useful to determine the magnitude of the problems in series of cases in our setup, as local data and studies are not available. Strategies could be made to minimize or cut down the complications.

Objective

To assess the postoperative complications of silicone oil injection after pars plana vitrectomy in rhegmatogenous retinal detachment.

MATERIALS AND METHOD

The study was a descriptive case series and it was carried out at vitreoretinal unit of Al-Ibrahim Eye Hospital, from January 2009 to June 2009. 100 eyes with rhegmatogenous retinal detachment according to inclusion and exclusion criteria were included in the study. Non-probability, purposive sampling was done. Patients with rhegmatogenous retinal detachment, age above 25 years and ability to comply with study protocol were included. While, patients with previous surgery for rhegmatogenous retinal detachment, patients with non-rhegmatogenous retinal detachment, patients with previously diagnosed glaucoma, patients with uveitis and patients with band keratopathy or bullous keratopathy and any other corneal pathology were excluded from the study.

Patients for the study were selected from our outpatient department of vitreoretinal unit and after being diagnosed clinically (by indirect ophthalmoscopy), were enrolled according to the inclusion and exclusion criteria. In order to control confounding variables, exclusion criteria were strictly followed.

Purpose, procedure, benefits and risks of the silicon oil injection and pars-plana vitrectomy was explained to the patient and informed consent was taken. A proforma was filled which consisted of postoperative details either yes or no. Ocular examination included best corrected visual acuity, refractive status, anterior segment examination with slit lamp, intraocular pressure measurement with Goldman applanation tonometer and funduscopy with slit lamp using 90D lens as well as indirect ophthalmoscopy using 20D lens. Investigation included fundus photograph with fundus camera in eyes with clear media.

Consultants having minimum 5 year surgical experience performed pars plana vitrectomy. It was undertaken in local (retrobulbar and facial anesthesia) or general anesthesia. Silicone oil 1000 cs (Micromed Co.) was injected in all eyes for prolonged intraocular tamponade.

Postoperative follow up was of 3 months. On each follow up, patients were examined for best corrected visual acuity, anterior segment examination with slit lamp, intraocular pressure measurement with Goldman applanation tonometer and funduscopy with slit lamp using 90 D lens as well as indirect ophthalmoscopy using 20 D lens with special

emphasis on silicone oil related complications in rhegmatogenous retinal detached eyes including, increased intraocular pressure, changes in refractive status, band keratopathy, silicone oil emulsification. Recognized postoperative complications of silicone oil were measured either Yes or No.

Statistical analysis was done on SPSS version 10.0 on computer. Frequency and percentages were computed for qualitative variables including gender increased intra ocular pressure, band keratopathy change in refractive status, emulsification and type of complications due to silicone oil. Mean and standard deviation were computed for quantitative variables including age of patient. Stratification was done with respect to grades of rhegmatogenous retinal detachment to see in put and outcome.

RESULTS

Out of 100 patients included in the study, 54 (54%) were males, while 46 (46%) were females.

Mean age in our study was 58.33 years. Minimum age was 45 years while maximum age was 83 years with standard deviation of 7.12.

Frequencies of silicone oil related complications

1. Raised intra ocular pressure

Out of 100 patients included in the study, 43 had raised intraocular pressure; while the rest of 57 patients did not show any rise in intraocular pressure after three months of follow up (figure 1).

2. Change in refractive status

Out of 100 patients included in the study, all 100 (100%) patients developed some form of change in their refractive status.

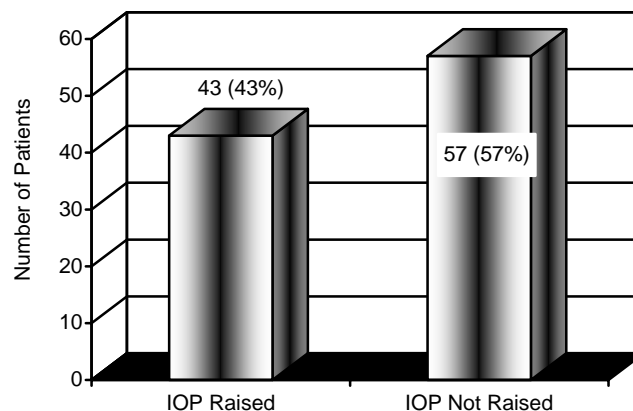


Fig. 1: Increased intraocular pressure n = 100
IOP = intraocular pressure (in mm Hg)

3. Band keratopathy

Out of 100 patients included in our study, only 6 (6%) patients developed band keratopathy by 3rd month of follow up (figure 2).

4. Silicone oil emulsification

Out of 100 patients included in the study, only 8 (8%) had silicone oil emulsification in their eye in 3 month follow up (figure 3).

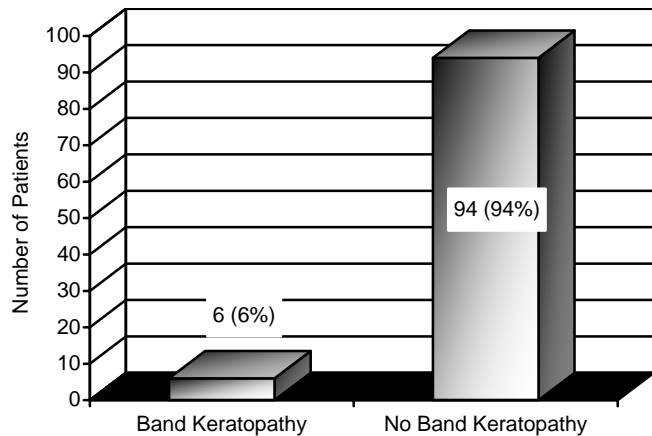


Fig. 2: Band Keratopathy n = 100

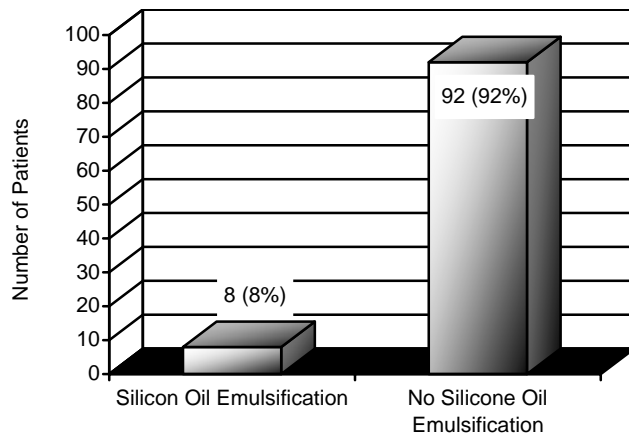


Fig. 3: Silicone oil emulsification n = 100

Grades of rhegmatogenous retinal detachment

Out of 100 patients included in the study, 20 had PVR Grade B, while rest of the 80 patients had PVR Grade C.

Frequencies of different complications in relation to grades of retinal detachments are shown in (figures 4-7).

DISCUSSION

Since the introduction of silicone oil, there have been multiple controversies concerning the safety of silicone

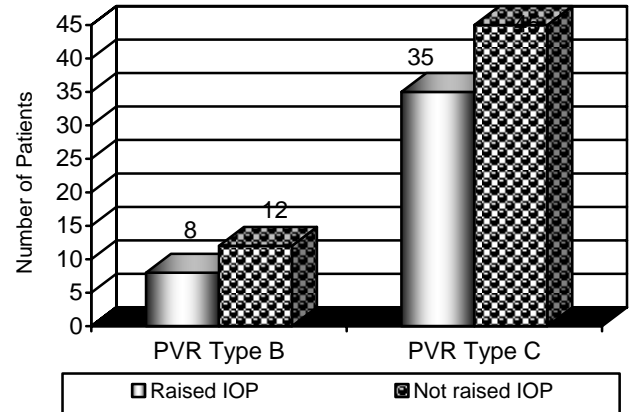


Fig. 4: Increased in intraocular pressure in different grades of rhegmatogenous retinal detachment
IOP = intraocular pressure
PVR = Proliferative vitreo-retinopathy (type B and C)

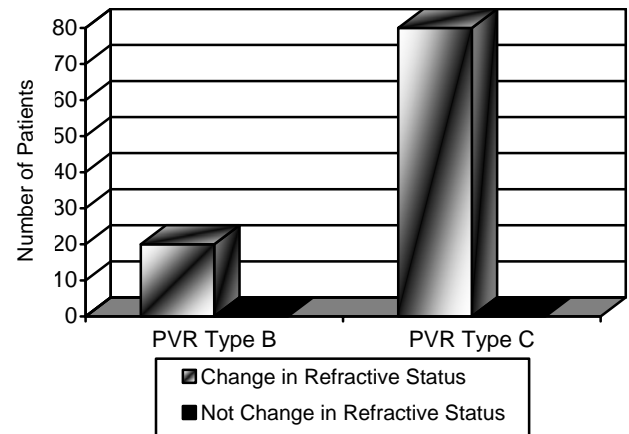


Fig. 5: Change in refractive status in different grades of rhegmatogenous retinal detachment
PVR = Proliferative vitreo-retinopathy (type B and C)

oil for intraocular use.^{8,9} For of these reasons, removal of silicone oil is typically advocated. Prolonged silicone oil tamponade has been demonstrated to induce multiple anterior segment complications, including cataract, glaucoma, and keratopathy.⁹

Our study has shown the risk of many complications such as raised intraocular pressure, silicone oil emulsification and band keratopathy after silicone oil injection. Similarly, one study also showed that silicone oil injection is associated with a high risk of complications⁹. Close analysis of their findings shows that the improvement in visual function associated with successful reattachment of the retina by this method is maintained in the majority of cases,

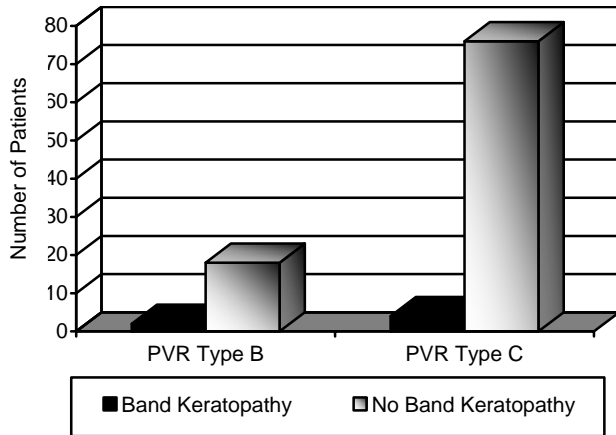


Fig. 6: Band keratopathy in different grades of rhegmatogenous retinal detachment
PVR = Proliferative vitreo-retinopathy (type B and C)

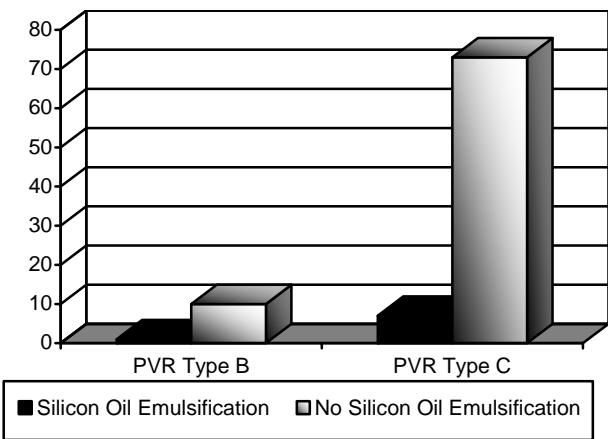


Fig. 7: Silicone oil emulsification in different grades of rhegmatogenous retinal detachment
PVR = Proliferative vitreo-retinopathy (type B and C)

and that complications, when they occur, do not necessarily cause progressive visual loss. In our study, we did not notice any lens related complications but many studies have reported cataract, as the commonest late complication of silicone oil injection but the lens changes are not usually dense enough to cause loss of navigational vision^{9,10}. Our study has reported a high risk of raised intra ocular pressure after silicone oil injection, while in another study the presence of silicone oil particles in the angle structures was a common finding but the incidence of raised intraocular pressure was not high and did not usually appear to be related to the presence of oil in the angle,¹⁰ on the other hand another study reported that

raised IOP was associated with the presence of oil particles within the anterior chamber¹¹, One study reported this finding, as common in phakic as it is in aphakic eyes and it seems that presence of large number of such particles could lead to trabecular meshwork obstruction.¹⁰ Exact cause of this increase in pressure was not studied as it was beyond the scope of our study.

Our study also reported the risk of band keratopathy after silicone oil injection, similarly, in one study it was noted that in a few aphakic eyes in which there was a dehiscence in the vitreous remnant a large globule of silicone fluid came forward into the anterior chamber after surgery, causing a severe and often painful keratopathy.¹⁰

Our study has shown changes in refractive power in almost all the patients. One study regarding the changes in refractive power after pars plana vitrectomy shows the hypermetropic shift in phakic or pseudophakic eyes included in the study.¹²

The main limitations of our study were that we used only one type of silicone oil that is 1000 cs, because of its use in our setup. Results can vary with the use of other type (5000 cs) of silicone oil. Similarly our follow up time was short, so complication that may occur later didn't appear in this follow up time.

We conclude that, while the technique of silicone oil injection is associated with a high risk of medium term complications, particularly raised intraocular pressure, band keratopathy and change in refractive status, but even then the usefulness of silicone oil as a tamponade cannot be denied. These complications can be managed by prescribing glasses for change in refractive status and giving medicine to control intraocular pressure or removal of oil from anterior chamber to prevent band keratopathy.

CONCLUSION

Use of silicone oil after vitrectomy in patients with rhegmatogenous retinal detachment, can be associated with multiple complications, of which change in refractive status and raised intra-ocular pressure were the most frequent complications.

Author's affiliation

Mazhar Ul Hassan
Isra Postgraduate Institute of Ophthalmology
Al-Ibrahim Eye Hospital, Malir
Karachi

Asif Kazi
Isra Postgraduate Institute of Ophthalmology
Al-Ibrahim Eye Hospital, Malir
Karachi

Umair Qidwal
Isra Postgraduate Institute of Ophthalmology
Al-Ibrahim Eye Hospital, Malir
Karachi

Aziz ur Rehman
Isra Postgraduate Institute of Ophthalmology
Al-Ibrahim Eye Hospital, Malir
Karachi

Nasir Bhatti
Isra Postgraduate Institute of Ophthalmology
Al-Ibrahim Eye Hospital, Malir
Karachi

REFERENCE

1. **De Silva DJ, Lim KS, Schulenburg WE.** An experimental study on the effect of encircling band procedure on silicone oil emulsification. *Br J Ophthalmia.* 2005; 89: 1348-50.
2. **Janet R, Chang S.** Vitreous substitution. 2nd ed. Albert DM JF, editor: Philadelphia: W.B. Saunders; 2000.
3. **Rehman N.** Primary vitrectomy for uncomplicated Aphakic and pseudophakic retinal detachment. *Pak J Ophthalmol.* 2000; 16: 148-52.
4. **Light DJ.** Silicone oil emulsification in the anterior chamber after vitreoretinal surgery. *Optometry.* 2006; 77: 446-9.
5. **Popovic SS, Sikic J, Pokupec R.** Intraocular pressure values following vitrectomy with silicone oil tamponade. *Acta Med Croatica.* 2005; 59: 143-6.
6. **Quintyn JC, Genevois O, Ranty ML, et al.** Silicone oil migration in the eyelid after vitrectomy for retinal detachment. *Am J Ophthalmol.* 2003; 136: 540-2.
7. **Danker DL, Parodies D, Moy CM, et al.** Blepharoptosis and upper eyelid swelling due to lipogranulomatous inflammation caused by silicone oil. *Am J Ophthalmol.* 2005; 140: 934-6.
8. **Cibis P, Becker B, Okun E, et al.** The use of liquid silicone in retinal detachment surgery. *Arch Ophthalmol.* 1962; 68: 590-9.
9. **Okun E.** Intravitreal surgery utilizing liquid silicone: a long-term follow-up. *Transactions of the Pacific Coast Oto-Ophthalmological Society.* 1968; 49: 141-59.
10. **Leaver PK, Grey RH, Garner A.** Silicone oil injection in the treatment of massive preretinal retraction. II. Late complications in 93 eyes. *Br J Ophthalmol.* 1979; 63: 361-7.
11. **Watzke RC.** Silicone retinopexis for retinal detachment: a long-term clinical evaluation. *Archives of Ophthalmology.* 1967; 77: 185-96.
12. **Gao Q, Chen X, Ge J, et al.** Refractive Shifts in Four Selected Artificial Vitreous Substitutes Based on Gullstrand-Emsley and Liou-Brennan Schematic Eyes. *Investigative Ophthalmology and Visual Science.* 2009; 50: 3529-34.