

Corneal Graft in Children

Munira Shakir, Syeda Aisha Bokhari, Shakir Zafar, Zeeshan Kamil, Syed Fawad Rizvi

Pak J Ophthalmol 2012, Vol. 28 No. 2

See end of article for authors affiliations

Correspondence to:
Munira Shakir
House No. 61
L.R.B.T Free Base Eye
Hospital, Karachi
Korangi 2^{1/2}, Karachi.
Postal Code- 74900

Purpose: To share our experience of penetrating keratoplasty in children at a tertiary care hospital

Material and Methods: In this study, records of pediatric keratoplasty performed on 90 eyes in 85 children of less than 14 years of age at the Pediatric Department of LRBT Free Base Eye Hospital Karachi, for the period of 3 years from January 2006 to December 2008 were reviewed.

Results: Out of 85 patients, 45 (52.94%) were boys and 40 (47.05%) were girls. Indications were scarring after keratitis in 16 (17.7%) eyes, traumatic corneal scarring in 16 (17.7%), corneal dystrophies 22 (24.4%), keratoconus and hydrops in 26 (28.8%), chemical injury in 8 (8.8%) and congenital glaucoma in 2 (2.2%). Total 65 out of 90 (72%) eyes showed clear cornea at final follow up. Grafts performed for keratoconus were the most successful in terms of graft survival, which accounted for 23 out of 26 (88.46%) eyes. Improvement in visual acuity was recorded in 64 out of 90 (71.11%) eyes. Best corrected visual acuity of 6/24 or better was achieved in 22 out of 90 (24.44%) patients.

Conclusion: In conclusion, our experience of keratoplasty in pediatric age group yielded promising results.

Keratoplasty is one of the world's most widely practiced human organ and tissue transplantation method¹. Corneal grafting is usually indicated for optical reason to restore vision occasionally it may be performed for cosmetic appearance of the eye².

Modern day success in transplantation is attributed to eye banking, storage techniques, ocular pharmacology, equipment and modern surgical techniques³. Paediatric keratoplasty is a difficult undertaking, which presents a wide range of challenges pre-operatively, intra-operatively and post-operatively⁴. Successful restoration of vision with paediatric keratoplasty has only been achieved in the past two to three decades⁵. Previously pediatric corneal transplantation was considered contraindicated in children,⁶ because of the technical challenges in pediatric anterior segment surgery created by low scleral rigidity and forward displacement of lens-iris diaphragm. In children, the potential for post-surgical anterior segment inflammation may lower scleral rigidity which increases the likelihood of significant refractive errors

after corneal transplantation. The underlying disease process will also influence the timing of surgery,⁵ presence of amblyopia, associated ocular pathology, and greater severity of the diseased may significantly limit visual outcome⁴.

The upper age limit used to define the pediatric population varies among experts and may include adolescents up to the age of 21 which is consistent with the definition found in several well-known sources^{7,8}.

The surgical procedure is technically more complex owing to the decreased rigidity and increased elasticity of the infant cornea and sclera, the smaller size of the infant eye, the increased intraoperative fibrin formation and the positive vitreous pressure⁴. Postoperative follow up and management may be more complicated, and graft rejection is often difficult to detect and treat⁴.

MATERIAL AND METHODS

This retrospective case series reviewed 90 eyes of 85 patients, who underwent penetrating keratoplasty

from January 2006 to December 2008 in Pediatric Department LRBT Free Base Eye Hospital, Karachi. Out of 85 patients, 45 (52.94%) were boys and 40

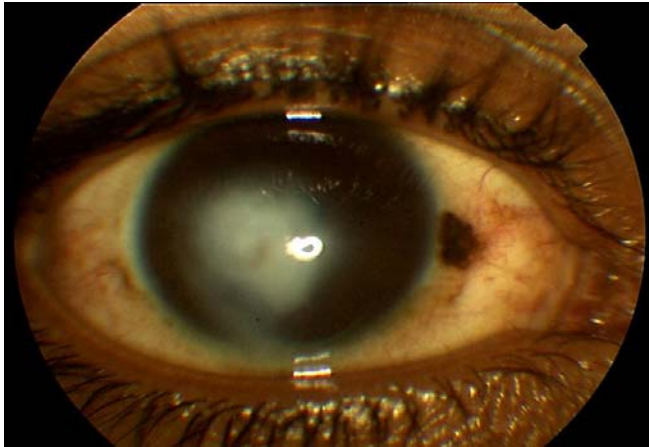


Fig. 1

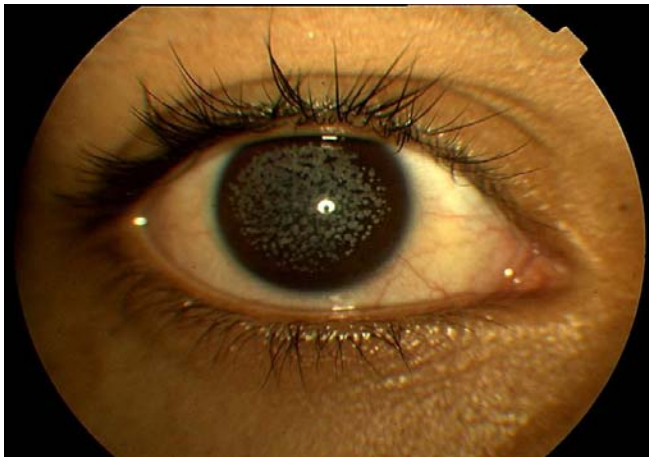


Fig. 2:

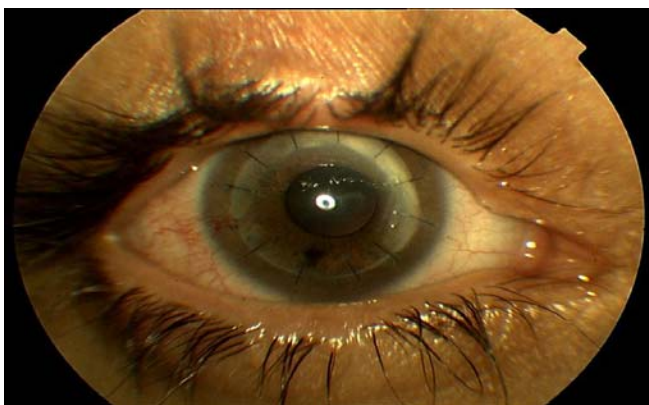



Fig. 3:



Pre graft photograph



Post graft photograph

Fig. 4:

(47.05%) were girls. Inclusion criteria included patients with age ranging from 6 to 14 years with no sex predilection; patients diagnosed with traumatic corneal scarring, corneal dystrophies, keratoconus and hydrops, chemical injury and congenital glaucoma. Exclusion criteria included combined non-corneal procedures, herpetic keratitis, patients with age below 6 years and patients who were lost to follow up. Minimum follow up was 6 months while mean follow up was 15 months. Preoperatively all patients underwent a complete ocular examination which included visual acuity assessment, intraocular pressure measurement, slit lamp and dilated fundus examination, A and B scan if needed. At the end of surgery all patients received systemic and topical steroids to decrease inflammatory reaction. Topical cycloplegics, steroids and antibiotic eye drops were administered postoperatively. Follow up examinations were performed consisting of visual acuity assessment and slit-lamp examination, intraocular pressure, fundus examination and if needed ultrasonic examinations. In the eyes with amblyopia, occlusion or atropinization of the good eye was conducted postoperatively. Early optical correction with spectacles or contact lenses was pursued as aggressively as possible.

Data was analysed on SPSS (version 13). Frequency and percentages were calculated for age, gender, best corrected visual acuity, graft survival and failure. Chi-square test and Fisher exact test were applied to calculate p-value and $p < 0.005$ was taken as statistically significant.

SURGICAL TECHNIQUE

All penetrating keratoplasty surgeries were done by the same surgeon, under general anesthesia. Standard

Table 1: Graft failure and survival in different groups and their statistical significance (p<0.005)

Disease	Number n	Graft survival n	Graft failure n	p-value
Keratitis	16	8	8	0.016
Corneal scarring	16	12	4	1
Dystrophies	26	16	10	0.088
Keratoconus	26	25	1	0.0014
Congenital glaucoma	2	1	1	0.4566
Chemical injury	6	3	3	0.181
Total	88	65	23	

surgical technique was used throughout. Source of graft was from eye bank of Canada. Prior to surgery donor's cornea were stored in Mc Carey Kaufman storage medium. The donor corneal button was trephined from the endothelial surface of the corneal scleral button. The diameter of the corneal button was 0.25-0.5mm larger than that of the recipient bed. The donor cornea was sutured to the recipient cornea with 10-0 nylon interrupted sutures. The mean diameter of the donor corneal button was 7.5mm (range 7.0-8.0 mm), and the mean diameter of the recipient bed was 7.0mm (range 6.5-7.5 mm). The mean time of sutures removal after keratoplasty was 10±4 months. Earlier suture removal was performed in case of loosening of the sutures and increased vascularization of the host cornea.

RESULTS

This study included 90 eyes of 85 patients out of which, 45 (52.94%) were boys and 40 (47.05%) were girls. The mean age at the time of penetrating keratoplasty was 10 years (ranged from 6 to 14 years). Minimum follow up was 6 months while mean follow up was 15 months. Preoperative best corrected visual acuity ranged from light perception and hand movement to 6/60. Postoperative visual acuity improvement was recorded in 64 (71%) out of 90 eyes. Visual acuity improvement ranged from counting finger to 6/12 partial. Twenty two (24.44%) out of 90 patients achieved a best corrected visual acuity of 6/24 or better. Graft failures was defined as irreversible loss of corneal clarity. Overall 65 (72.22%) out of 90 eyes showed clear cornea at final follow up. Most grafts failed because of allograft rejection that is 13 (56.52%) out of 23, secondary infection was noted in 08(34.78%)

out of 23 and secondary glaucoma was found in 2 (8.69%) out of 23. Two patients were lost to follow up. Graft survival was seen in a total of 65 (73.86%) out of 88 patients of which 8 (50%) out of 16 patients were of keratitis, 12 (75%) out of 16 patients were of corneal scarring, 16 (61.5%) out of 26 patients were of dystrophies, 25 (96.15%) out of 26 patients were of keratoconus, 1 (50%) out of 2 patients were of congenital glaucoma and 3 (50%) out of 6 patients were of chemical injury. Grafts performed for keratoconus were most successful in terms of graft survival 23 (88.46%) out of 26 (p=0.0014), table 1.

Intraoperative complications were raised intraocular pressure seen in 4 (4.44%) eyes, iris injury in 1 (1.11%), bleeding from vascularized cornea 2 (2.22%) and decentration in 1 (1.11%) eye. Postoperative complications were suture related corneal infiltrates in 6 (6.66%) eyes, acute uveitis in 1 (1.11%) case post traumatic adherent leucoma 1 (1.11%) eye, peripheral anterior synechiae in 2 (2.22%) eyes, secondary glaucoma was noted in 4 (4.44%), persistent epithelial defect in 5 (5.55%) and development of cataract in 2 (2.22%) eyes.

DISCUSSION

Corneal grafting is a simple surgical procedure, which is most of the time straight forward. However, the rehabilitation time after surgery is long because of a slow healing process and many of the factors that affect visual outcome are uncertain. It is therefore; especially important with this procedure to try to understand more about what may be achieved in the long term. The success rate of penetrating keratoplasty in children is not as high as it is in adults. The reasons

for the poorer prognosis are technically difficult surgery and irreversible amblyopia⁹.

Penetrating keratoplasty in children is generally considered a high risk procedure, because surgery in a small eye can lead to a sclera collapse. Moreover, the iris is more adherent and the vitreous more tenacious in children than in adults⁹. Improved results have been attributed in part to the advantages in surgical technique, improved donor-storage media and development of viscoelastics. Therefore, the rate of intraoperative complications has been significantly declined.⁹ Despite all the developments, the incidence of inflammatory reaction and immunological rejection is still significant. The prognosis for graft clarity in children is poorer because of the high bioreactivity and healing potential of a child's eye, which is very rapid and causes sutures to loosen quickly¹⁰.

In this series overall graft survival at the end of follow up was 65 out of 90 (72.22%). Graft performed for keratoconus were most successful in terms of graft survival which was seen in 23 out of 26 (88.46%). Gabric N et al reported 64% graft survival in their series of corneal transplantation, with best prognosis in graft for keratoconus and congenital dystrophy¹¹. Overall 5-year graft survival was 82%, with keratoconus and corneal dystrophy as reported by Rehman I et al¹². Dandona L et al also reported 46.5% graft survival in their study, with highest rate of graft survival for keratoconus¹³. Patel HY, documented 82% graft survival at the end of one year¹⁴.

In this study postoperative visual acuity improvement was recorded in 64 out of 90 (71.11%) eyes. Visual acuity improvement ranged from counting finger to 6/12 partial. 22 out of 90 (24.44%) patients achieved a best corrected visual acuity of 6/24 or better. McClellan et al reported improvement in visual acuity better than 6/60 in only 14% of cases¹⁵. Xu-Jia H et al reported improvement in visual acuity by 6/18 or better in 13% of cases¹.

CONCLUSION

In this study 72.22% eyes showed clear cornea post-operatively with improvement in visual acuity seen in 71.11%. Most successful results were seen in eyes with keratoconus in which graft survival was observed in 88.46% cases. Keeping the above findings in view, we conclude that keratoplasty is a safe and effective treatment in pediatric age-group. Further clinical trials are required to establish these findings.

Author's affiliation

Dr. Munira Shakir
Consultant Ophthalmologist
L.R.B.T Free Base Eye Hospital, Karachi
Korangi 2^{1/2}, Karachi.
Postal Code- 74900

Dr. Syeda Aisha Bokhari
Associate Ophthalmologist
L.R.B.T Free Base Eye Hospital, Karachi
Korangi 2^{1/2}, Karachi.
Postal Code- 74900

Dr. Shakir Zafar
Consultant Ophthalmologist
L.R.B.T Free Base Eye Hospital, Karachi
Korangi 2^{1/2}, Karachi.
Postal Code- 74900

Dr. Zeeshan Kamil
Associate Ophthalmologist
L.R.B.T Free Base Eye Hospital, Karachi
Korangi 2^{1/2}, Karachi
Postal Code- 74900

Dr. Syed Fawad Rizvi
Chief Consultant Ophthalmologist
L.R.B.T Free Base Eye Hospital, Karachi
Korangi 21/2, Karachi
Postal Code- 74900

REFERENCE

1. **Xu HJ, Jiang XJ, Jie SM, et al.** Pediatric penetrating keratoplasty in shanghai: a retrospective multiple centre study from 2003 to 2007. *Chin Med J.* 2008; 121: 1911-4.
2. Corneal and refractive surgery. In: Kanski JJ. *Clinical ophthalmology a systemic approach.* London: Butterworth Heineman: 2011. 239-50.
3. **Mc Neill JI.** Penetrating keratoplasty: preoperative considerations, indications and outcomes. In Krachker JH, Mannis MJ, Holland EJ (eds). *Mosby: Cornea, St Louis.* 1997; 3: 1551-61.
4. **Vajpayee RB, Ramu M, Panda A et al.** Oversized grafts in children. *Ophthalmology.* 1999; 106: 829-32.
5. Pediatric penetrating keratoplasty. In: Krachmer JH, Mannis MJ, Holland EJ, *Cornea: surgery of the cornea and conjunctiva.* St Louis: Mosby Year Book. 1997; 1731-56.
6. **Leigh AG.** Corneal grafting. *Br J Clin Pract.* 1958; 12: 329.
7. **Berham RE, Kliegman R, Arvin AM, et al.** *Nelson Textbook of pediatrics, 15thed,* Philadelphia: W.B Saunders company; 1996.
8. **Rudolph AM.** *Rudolph's Pediatrics, 21st Ed.* NY: McGraw-Hill; 2002.
9. **Stulting RD.** Penetrating keratoplasty in children. In: Brightbill, F.S., (Ed.): *Corneal surgery.* (Mosby St. Louis, Missouri, 1993).
10. **Dana, MR, Schaumberg DA, Moyes AL, et al.** *Gomes JAP, Ophthalmology.* 1997; 104: 1580.

11. **Gabric N, Dekaris I, Vojnikovic B, et al.** Corneal transplantation in children. *Coll Antropol* 2001; 25: 17-22.
12. **Rahman I, Carley F, Hillarby C, et al.** Penetrating keratoplasty: indications, outcomes, and complications. *Eye*. 2009; 23: 1288-94.
13. **Dandona L, Naduvilath T, Janarthanan M, et al.** Survival analysis and visual outcome in a large series of corneal transplants in india.
14. **Patel HY, Ormonde S, Brookes NH, et al.** The indications and outcome of paediatric corneal transplantation in New Zealand: 1991-2003. *Br J Ophthalmol*. 2005; 89: 404-8.
15. **McClellan K, Lai T, Grigg J, et al.** Penetrating keratoplasty in children: visual and graft outcome. *Br J Ophthalmol*. 2003; 87: 1212-4.