

Modified Scleral Buckling Technique Using Endoillumination and Non Contact Wide Angle Viewing System

Haroon Tayyab, Muhammad Ali Haider, Sana Jahangir, Bilal Zaheer Qureshi

Pak J Ophthalmol 2014, Vol. 30 No. 2

See end of article for authors affiliations

Correspondence to:
HaroonTayyab
House # SUH-24, Askari XI
Cobbe Lane
Near Qasim Market
Rawalpindi Cantt

Purpose: To assess feasibility and surgical outcome of a new scleral buckling technique for rhegmatogenous retinal detachment using endo illumination and noncontact wide angle viewing system.

Material and Methods: Eleven eyes of 11 patients underwent modified scleral buckling for rhegmatogenous retinal detachment. A custom modified 23 G endo illuminator and noncontact wide angle viewing system was utilized instead of binocular indirect ophthalmoscope to visualize fundus intra operatively.

Results: The mean age of patients was 45.3 years. Out of 11 patients, 9 patients (82%) achieved retinal reattachment while 2 patients had to undergo pars plana vitrectomy with silicone oil tamponade due to development of proliferative vitreoretinopathy. 8 (72%) patients achieved stabilization / improvement in visual acuity. 2 patients had minimal subretinal hemorrhage at the time of subretinal fluid drainage.

Conclusion: Combining wide angle viewing system and microsurgery with scleral buckling provides a useful and safe alternative for viewing fundus during retinal reattachment surgery.

Scleral buckling and cryopexy has been a time tested and valuable surgical technique for repairing rhegmatogenous retinal detachments (RD)¹. Although there has been increasing trend towards Pars Plana Vitrectomy (PPV) and internal tamponade as a primary treatment for rhegmatogenous RD, still, high success rates of functional and anatomic outcomes can be achieved with scleral buckling procedures².

The steps in conventional scleral buckling include limbal conjunctiva peritomy, recti muscle bridle sutures, localization and cryotherapy to retinal breaks, application of scleral exopiants, subretinal fluid drainage and injection of gas or air in vitreous cavity in case of superior breaks³.

It is important that surgeon should be very efficient and comfortable with indirect ophthalmoscopy when performed intra-operatively for precise application of cryotherapy and placement and

adjustment of position and height of scleral exopiants.

However, indirect ophthalmoscopy presents the surgeon with a reverse and inverted image of fundus which can cause significant difficulty in performing retinal procedures and observing fundus at the same time.⁵ Also, indirect ophthalmoscopy becomes less yielding in terms of details and accuracy in cases of hazy media. Repeated use of indirect ophthalmoscopy also makes the procedure inconvenient⁵.

Owing to advanced fundal viewing systems and improved microincisional vitrectomy instruments, surgeons have recently tried to evaluate the feasibility of viewing fundus using contact and noncontact lens during scleral buckling procedures with excellent results.⁶ In this series, we have performed modified scleral buckling procedures utilizing noncontact fundal viewing system and endoillumination; thus alleviating the need of using indirect ophthalmoscope intra operatively.

MATERIAL AND METHODS

This prospective interventional study was conducted in Vitreoretinal section of Al Ehsan Welfare Eye Hospital, Lahore, Pakistan (a tertiary care and registered ophthalmic facility) from May 2013 to November 2013. A total of 11 patients belonging to all age groups and gender with rhegmatogenous RD and up to Grade B Proliferative Vitreoretinopathy (PVR) were enrolled in this study. All patients underwent detailed fundal examination on slit lamp (wide field noncontact lens and triple mirror contact lens) and with indirect ophthalmoscope; all breaks were localized and extent of RD was documented on specially designed RD charts. All patients were phakic or had undergone uncomplicated cataract surgery. Patients with breaks in multiple quadrants or breaks posterior to equator were not included in this study. All surgeries were performed under general anesthesia and by a single surgeon. Anatomic success was defined as reattachment of retina and functional success was defined as stabilization or improvement of best corrected visual acuity (BCVA) after 2 months of follow up. A detailed informed consent about the nature of disease and type of surgical procedure was obtained from all patients. Approval for this study was sought from hospital's ethical committee.

Limbal conjunctival peritomy was performed with 2 radial relaxing incisions 180° apart avoiding the quadrants where final placement of scleral explant was planned. After peritomy, all 4 recti muscles were engaged with squint hooks and bridle sutures were passed underneath them using 4 - 0 silk suture. After consulting the RD diagrams of patient, a 23 G Autoseal PMS cannula (Oertli® Instruments AG, Switzerland) (Figure 1) was introduced 3.5 mm away from limbus (4 mm in phakic patients), using 1 step 23 G trocar (Oertli® Instruments AG, Switzerland). Placement of cannula was 120° away from the meridian of retinal break (or a location that afforded maximum globe maneuvering while keeping the distance between cannula and break at least 3 clock hours). A self retaining custom modified (Chandelier type) 23 G endoilluminator (Figure 2) was inserted in the Autoseal cannula.

Next, fundus was viewed through the aid of surgical microscope equipped with Oculus Stereoscopic Diagonal Inverter (OCULUS® Surgical, Inc. FL, USA) and Oculus Binocular Indirect Ophthalmoscope (BIOM®) with Oculus noncontact wide field enhanced lens (120° field of view). After adjusting the image inverter, position of

retinal break was accurately marked on sclera. While viewing retina in the same way, cryotherapy burns were applied at marked site. Endoilluminator was then removed and circumferential solid silicone tyre/radial silicone sponge was secured with sclera using mattress sutures with 5-0 Ethibond. Endoilluminator was again inserted in vitreous cavity and final position and height of scleral explant was adjusted while viewing retina through BIOM®. Subretinal fluid was drained when needed in conventional manner and fundus was evaluated with scleral indentation and for adequate retinal perfusion while observing central retinal artery patency. Endoilluminator was removed along with 23 G cannula and the site was secured with 6-0 Vicryl suture when needed. Isovolumetric concentration of SF6 gas was injected in vitreous cavity through pars plana where indicated. The surgery was completed by closing conjunctiva with 6-0 Vicryl suture.

RESULTS

Out of 11 patients, 6 (54%) were male and 5 (46%) were females. 7 (63%) patients had RD in right eye and 4 (36%) had RD in left eye. Range of age of patients was from 23 to 64 years with mean age of 45.3 years. 5 (45%) patients had solitary break whereas 6 (54%) patients had more than one break. Distribution of breaks according to quadrants is shown in Fig 3. 4 (36%) patients underwent radial silicone sponge whereas 7 (64%) patients underwent solid silicone tyre with 360° silicone band. Anatomic success was achieved in 82% of patients and functional success was achieved in 72% of patients as shown in Figure 4. BCVA of all patients is depicted in Table 1.

One patient had failed scleral bucking on first post operative day with persistent inferior subretinal fluid.




Fig. 1. 23 G Auto Seal PMS Cannula with self sealing membrane.



Fig. 2. Self retaining custom modified 23 G Endo Illuminator.

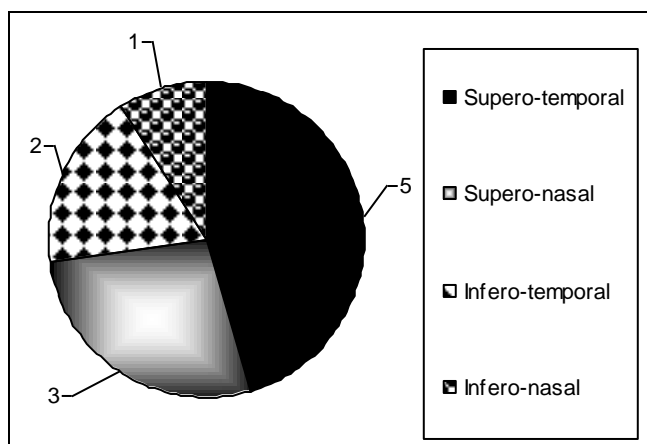


Fig. 3: Quadrant wise Distribution of Retinal Breaks

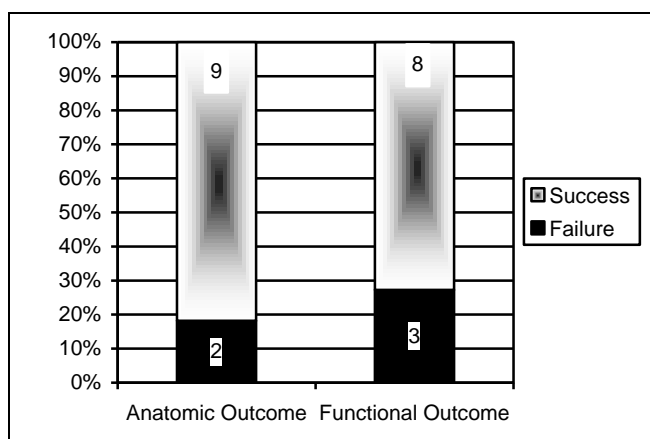


Fig. 4: Anatomic and Functional outcome after 2 month follow up

One patient had RD with grade C PVR 3 weeks post surgery. Both patient had to undergo PPV and silicone oil tamponade to reattach the retinas. One patient had deterioration of BCVA despite retinal reattachment. Her reason for progressively declining BCVA was extensive epimacular membrane. This patient lost to follow up after 2 months. 2 patients had minimal subretinal hemorrhage immediately after draining subretinal fluid without any long term complications.

DISCUSSION

Helmholtz is credited with invention of first ophthalmoscope in 1850 that could be effectively used for viewing retina⁷ and accurate description of retinal breaks was made possible after 2 years by Coccius⁸ and von Graefe⁹. Over the next century, various instruments for viewing retina rose to horizon before Schepens¹⁰ introduced the first clinically effective binocular indirect ophthalmoscope in 1947; and indirect ophthalmoscope has changed little since Schepens classic description.

The concept of modern scleral buckling (post Jules Gonin era) started with Custodis¹¹ when he became the first surgeon to perform scleral buckling using episcleralexoplant (polyviol) in 1949. His methods of scleral buckling underwent various advancements in terms of materials used for scleral exoplants and in methods of retinopexy before Lincoff introduced cryopexy and silicone exoplants; thus introducing the basis of modern scleral buckling¹². This technique demands an efficient use of binocular indirect ophthalmoscope while viewing a reverse and inverted fundus image. Also its use is considerably inconvenient and time consuming when it comes to performing cryopexy while viewing fundus at same time; thus demanding a considerable degree of expertise.⁵ Repeated surgical maneuvers needed while performing intra-operative indirect ophthalmoscopy may also render the media hazy; thus compounding the problem of accurate retinal break localization and its cryopexy.

Recently, surgeons have utilized various instruments used in modern day PPV to assist them in conventional scleral buckling to overcome the drawbacks mentioned above. First of many such reports came from Kumar where he used endo light pipe to localize subretinal fluid drainage site while performing scleral buckling in hazy ocular media.¹³ Nam⁵ recently reported a series of 12 cases where he successfully reattached retinas through sclera

Table 1: Pre and Post Operative Best Corrected Visual Acuity (BCVA)

Serial #	Age	Pre-Operative BCVA	1 Week Post Operative BCVA	1 Month Post Operative BCVA	2 Months Post Operative BCVA
Case 1	45	Counting Fingers	Counting Fingers	2/60	6/60
Case 2	51	Counting Fingers	Counting Fingers	6/60	6/36
Case 3	60	Hand Movement	Counting Fingers	Perception of light	Hand Movement
Case 4	23	Perception of light	Counting Fingers	Hand Movement	6/36p
Case 5	50	Perception of light	Hand Movement	1/60	4/60
Case 6	64	Hand Movement	Hand Movement	Perception of light	Perception of light
Case 7	38	6/60	6/60	6/60	6/18
Case 8	30	Hand Movement	Hand Movement	Counting Fingers	6/36
Case 9	49	3/60	5/60	6/60	3/60
Case 10	60	Counting Fingers	Counting Fingers	Hand Movement	Hand Movement
Case 11	28	6/60	Hand Movement	6/60	6/24

buckling with the help of 25-G Chandelier light (Alcon, Chandelier lighting system, Fort Worth, TX, USA) and wide - field contact lens (Mini Quad; Volk, Mentor, OH). He concluded that endoillumination systems are much easier to use while doing scleral buckling when compared to conventional methods of viewing fundus intra operatively. Nawrocki et al¹⁴ performed scleral buckling on 7 patients using Optic Fiber Free Intravitreal Surgical System (OFFISS®, Topcon Inc, Paramus, NJ, USA). He reported superior magnification and more precise control of surgery using OFFISS® with lesser intra-operative complications. Aras et al¹⁵ concluded that using a 25-G Torpedo light (Alcon Laboratories, Fort Worth, TX, USA) and a noncontact wide angle viewing system enhanced visualization and surgical precision in his study of 16 patients.

We conducted a similar series on 11 patients using custom modified 23-G endoilluminator compatible with Faros™ Vitrectomy machine (Oertli® Instruments AG, Switzerland) and BIOM®. We used 23-G valved cannula that did not require a metal plug when endoilluminator was removed from vitreous cavity whereas Nam⁵ used 25-G non valved cannula needing metal plugs to avoid vitreous escaping the cavity. Although using a larger gauge cannula, our results are comparable in terms of success and complication profile to Nam and his colleagues. But it is worth mentioning that we needed to secure the

scleral entry sites for 23-G cannula in 2 cases where as Nam's 25-G system was self sealing in all of his cases. We also preferred using noncontact wide field viewing system as opposed to surgical contact lens because noncontact system afforded better eye maneuverability when indenting and rotating the globe while keeping fundal view clear and focused at the same time. Similarly, in the series conducted by Aras et al¹⁵ who used 25-G Torpedo light, we preferred using 23-G modified self retaining endoilluminator. This was because firstly, Torpedo light can always damage lens when the eye ball is being moved and secondly, since Torpedo light needs a blade assisted vertical incision in sclera for its insertion, its removal can lead to vitreous escape.

Our anatomic and functional success rate was comparable as well. We achieved retinal attachment in 9 (82%) of our cases when compared to Aras et al¹⁵ (81%) and Nawrocki et al¹⁴ (87%). We did not encounter any scleral perforation during indentation where as Aras¹⁵ reported 2 such cases. We experienced mild subretinal hemorrhage in 2 (13%) of our cases which was comparable to Aras et al¹⁵.

CONCLUSION

Overall, in our experience, this modified method of scleral buckling using wide field retinal viewing systems and endoillumination is safe, more precise

and controlled operative technique when compared to conventional method of scleral buckling using binocular indirect ophthalmoscope; especially for intraoperative RD evaluation and cryopexy. We leave the choice of wide field viewing system (contact vs non contact) to individual surgeons but recommend use of “Chandelier Type” self retaining endoillumination for this surgery.

Author's Affiliation

Dr. Haroon Tayyab

Consultant Ophthalmologist

Al-Ehsan Welfare Eye Hospital, Lahore

Dr. Muhammad Ali Haider

Consultant Ophthalmologist

Al-Ehsan Welfare Eye Hospital, Lahore

Dr. Sana Jahangir

Assistant Professor of Ophthalmology

Sharif Medical and Dental College, Lahore

Dr. Bilal Zaheer Qureshi

Visiting Eye Surgeon

Al Ehsan Welfare Eye Hospital, Lahore

REFERENCES

1. **Nemet AY, Ferencz JR, Segal O, Meshi A.** Orbital cellulitis following silicone-sponge scleral buckles. *ClinOphthalmol.* 2013; 7: 2147-52.
2. **Ma J, Lin J, Yao K.** A new sclera locator for marking the retinal tears on the sclera during scleral buckling. *Retina.* 2013; 33:1086-7.
3. **Oluleye Ts, Ibrahim O, Olusanya B.** Scleral buckling for retinal detachment in Ibadan, Sub-Saharan Africa: anatomical and visual outcome. *ClinOphthalmol.* 2013; 7: 1049-52.
4. **Liu W, Li C, Huang S, Wu Q.** A new microsurgical technique to correct retinal detachment. *Yan Ke Xue Bao.* 2006; 22: 4-13.
5. **Nam KY, Kim WJ, Jo YJ, Kim JY.** Scleral buckling technique using a 25-gauge chandelier endoilluminator. *Retina.* 2013; 33: 880-2.
6. **Ohji M, Tano Y.** Vitreoretinal surgery with slit lamp illumination combined with a wide angle viewing contact lens. *Am J Ophthalmol.* 2004; 137: 955-6.
7. **Helmholtz H.** Beschreibungeines ophthalmoscope for exam of retinal eye disease patients living in Berlin. *A forstner'sche Verlagsbuchhandlung.* 1851.
8. **Coccia A.** New Ophthalmoscope application information, one with Leipzig instrument. *Immanuel Muller.* 1853; 131.
9. **Wilkinson CP, Rice TA.** History of Retinal Detachment Surgery. *Michels Retinal Detachment 2nd edition.* St Louis. Mosby; 1997. 251-333.
10. **Schepens CL.** A new ophthalmoscope demonstration, *Trans Am Acad Ophthalmol Otolaryngol.* 1947; 51:298.
11. **Custodis E.** Treatment of retinal detachment by circumscribed diathermal coagulation and by scleral depression in the area of tear caused by imbedding of a plastic implant. *Klin Monbl Augenheilkd Augenarztl Fortbild* 1956; 129: 476.
12. **Lincoff HA, Baras I, Mclean J.** Modifications to the Custodis procedure for retinal detachment. *Arch Ophthalmol* 1965; 73: 160-3.
13. **Kumar A, Prakash G, Garg P.** Endo-lightpipe to localise the site of SRF drainage in retinal reattachment surgery with hazy ocular media. *Indian J Ophthalmol.* 2002; 50: 247.
14. **Nawrocki J, Michalewska Z, Michalewski J.** Optic Fibre Free Intravitreal Surgical System (OFFISS) in retinal detachment surgery. *Ophthalmic Surg Lasers Imaging.* 2008; 39: 466-70.
15. **Aras C, Ucar D, Koytak A, Yetik H.** Scleral buckling with a non-contact wide - angle viewing system. *Ophthalmologica.* 2012; 227: 107-10.