

# How Cataract Extraction Helps in Improving Aqueous Outflow?

Hafiza Sadia Imtiaz, Irfan Qayyum Malik, Farhan Ali

*Pak J Ophthalmol 2018, Vol. 34, No. 4*

See end of article for authors affiliations

Correspondence to:  
Correspondence to:  
Hafiza Sadia Imtiaz,  
PGR II, Ophthalmology  
DHQ, UTH, Gujranwala  
Email: sadiaimtiaz69@gmail.com

**Purpose:** To assess changes in Anterior Chamber angle depth and width induced by phacoemulsification and intraocular lens implantation in normal population using anterior segment optical coherence tomography (AS-OCT).

**Study Design:** Quasi experimental study.

**Study Place and Duration:** Eye Department of DHQ-Teaching Hospital Gujranwala, from January, 2018 to June 2018.

**Material and Methods:** All patients of both genders with senile cataract, having uneventful cataract surgery were randomly included in this study. After routine ophthalmic examination, pre-operative intraocular pressure (IOP) using Goldmann applanation tonometer along with anterior segment OCT for measuring angle parameters was done in the temporal quadrant of respected eye at the time of admission. Post-operatively the same procedure was repeated at the time of discharge. A P-value  $\leq 0.05$  was considered to be statistically significant.

**Results:** Out of 82 patients, 44 (53.7%) were male and 38 (46.3%) were female. Mean Axial length recorded was  $23 \pm 1.2$  mm with mean IOL power of  $22.0 \pm 3.2$ D. Mean Pre-op Trabecular Iris Angle (TIA) was  $41.5 \pm 8.7^\circ$  that widened to  $48.6 \pm 8.3^\circ$  post-operatively while Mean pre-op Angle opening distance (AOD-500  $\mu\text{m}$ ) recorded was  $447.5 \pm 149.8$   $\mu\text{m}$  that increased to  $609.5 \pm 169.8$   $\mu\text{m}$  post-operatively. Similarly, Mean pre-op IOP recorded was  $16.8 \pm 2.8$  mm Hg that reduced to  $15.1 \pm 2.9$  mm Hg post-operatively. P-value of all three parameters turned out significant ( $< 0.05$ ).

**Conclusions:** Cataract extraction and IOL implantation causes an increase in anterior chamber angle depth and width along with a reduction in intra-ocular pressure which is a direct evidence of improved aqueous outflow.

**Key Words:** Anterior chamber, Trabecular Meshwork, Angle, Optical coherence tomography.

In cataract surgery, cloudy crystalline lens is removed and replaced by clear artificial lens called intra-ocular lens. There are various methods for cataract extraction and most recent and efficient one is phacoemulsification and intra-ocular lens implantation<sup>1</sup>. In phacoemulsification, ultrasonic vibrations are used to break the crystalline opaque lens into pieces which are then removed by aspiration.

Cataract extraction and IOL implantation causes

change in anterior chamber configuration<sup>2</sup> that includes an increase in anterior chamber depth (ACD), increase in anterior chamber angle (ACA) with increase in angle depth and width. These changes in anterior chamber configuration ultimately lead to fall in intra-ocular pressure<sup>3</sup>.

There are various methods to determine anterior chamber details that include Gonioscopy for anterior chamber angle details, ultrasound Biomicroscopy

(UBM), that gives high resolution images of anterior chamber<sup>4,5,6</sup> and anterior segment OCT.

The most recent one is anterior segment optical coherence tomography (AS-OCT) that uses light of longer wavelength and is superior being non-contact and non-invasive, having less inter-observer and intra-observer variability, rapid and easy to perform, providing efficient storage capacity for images that can be visualized at any time<sup>7</sup>.

The rationale of our study was to study how much angle is widened after cataract extraction with resultant decrease in intra-ocular pressure (IOP) in our local population. The purpose of this study is the quantitative measurement of change in anterior chamber angle depth and width after uneventful phacoemulsification and intra-ocular lens implantation in normal population using anterior segment optical coherence tomography (AS-OCT).

**MATERIAL AND METHODS**

After approval from hospital ethical committee, a written informed consent with demographic information was collected from each patient before participating in this study. Patients of both genders, between 50-70 years of age, with senile cataract, having uneventful cataract surgery were randomly included in this study. Glaucoma patients, patients with previous intra-ocular surgery and with optic nerve or retinal dysfunction were excluded from this study. This study included 82 patients (sample size

$$\frac{Z_{1-\alpha/2}^2 \sigma^2}{d^2 \mu^2}$$

was calculated using formula and values taken from Junejo, et al., 2016 study). It was conducted at eye department of DHQ-Teaching Hospital Gujranwala from January 2018 to June 2018.

All patients underwent routine ophthalmic examination including unaided visual acuity (UVA), visual acuity with pinhole (PH), best corrected visual acuity (BCVA), Slit lamp Biomicroscopy and Fundus evaluation. Biometry of the respected eye was done to determine axial length and IOL power. Gonioscopy was done by experienced examiner in dark to exclude patients with angle closure glaucoma. Goldmann applanation tonometry and anterior segment optical coherence tomography (Optovue; Model iVue 500) of respected eye was done pre-operatively and 2 days post-operatively in non-dilated eye under dark conditions. While performing AS-OCT the patient was

asked to sit comfortably with forehead touching the forehead rest and fixate on the green indicator. Focusing was done manually. One examiner, masked to the results of clinical findings performed AS-OCT in temporal quadrant of respected eye under standardized dark conditions. Scans were manually centered on pupil and auto-adjusted to obtain best quality images. One best image was selected among all with no motion or artifact due to eyelid movements. These images were finally processed using customized software by the same experienced observer. The only input of examiner was to determine the location of the scleral spurs. The algorithm then automatically calculated the anterior segment parameters. Among all parameters, Trabecular iris angle (TIA) and Angle opening distance at 500 (AOD-500) were included in this study.

Two surgeons performed all cataract surgeries using phacoemulsification under retro-bulbar anaesthesia with 1% lignocaine and 0.5% bupivacaine followed by 10 minutes of external ocular massage. Temporal clear corneal incision was given that was not sutured at the end of surgery. Uneventful phacoemulsification and foldable IOL implantation was done. If accidentally any case met a per-op or post-op complication, then it was excluded from this study. Patients were discharged on second post-op day after repeating IOP and AS-OCT of respected eye.

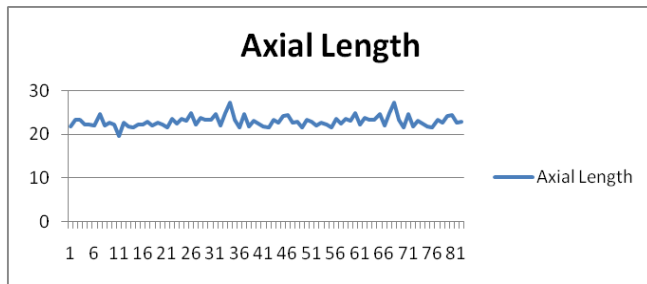
Data was analyzed using SPSS version 23.0. Results were expressed as mean ± SD and ranges. Comparison between pre-operative and post-operative angle parameters was done using a paired t-test. A P-value ≤0.05 was considered to be statistically significant.

**RESULTS**

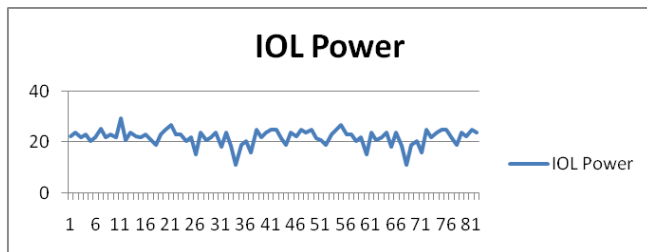
82 patients were included in this study. Out of which 38 (46.3%) were female and 44 were male (53.7%). Right eye was involved in 42 cases (51.2%) and left one in 40 cases (48.8%). Average age noted was 60.7 ± 6.5 (range 50-70) years. 50 patients (61%) were below 60 years of age and 32 patients (39%) were above 60 years of age.

Demographic Variables	Study Population(n=50)
Age:	Mean ± SD 60.7 ± 6.5
Gender	Male/Female 53.7% (44)/46.3%(38)
Laterality:	Right/Left 51.2% (42)/48.8%(40)

- Mean IOL power recorded was  $22 \pm 3.2$  with Range of 11-29.5 D and Mean Axial length recorded was  $23 \pm 1.2$  with Range of 16.6-27.3 mm.



**Fig. 1a:** Axial length readings. X-axis showing no of pts. and y-axis showing Axial length in mm.



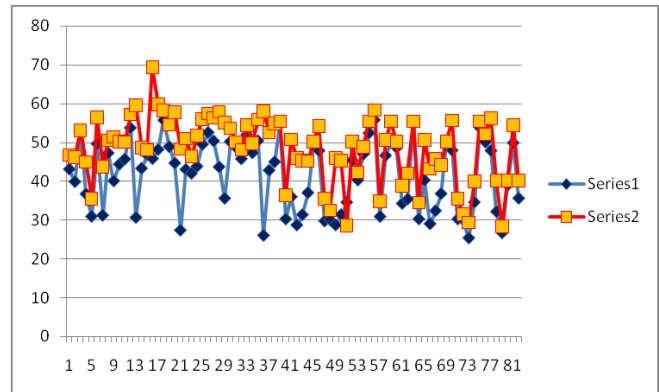
**Fig. 1b:** IOL power readings. X-axis showing no of pts. and y-axis showing IOL Power in Diopters.

- Only foldable intra-ocular lenses were being used during phaco surgery. Various types of foldable IOL with their frequencies are given in following table;

Types ee of Intraocular Cataract Lenses	Frequency	Percent
Alcon	7	8.5
BF	16	19.5
Focus Force	25	30.5
I-stream	24	29.3
Phys IOL	3	3.7
Zeiss	7	8.5
Total	82	100.0

- Mean Pre-op TIA recorded was  $41.5 \pm 8.7^\circ$  that widened to  $48.6 \pm 8.3^\circ$  post-operatively with significant p-value of 0.0001 ( $< 0.05$ ).

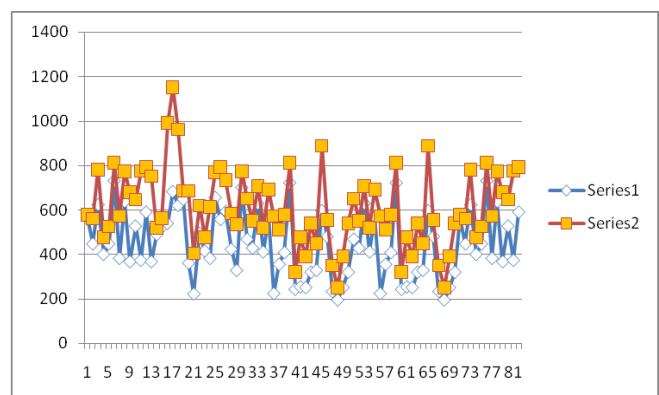
Trabecular Iris Angle (TIA)	Mean	n	Std. Deviation	p-value
Pre-op TIA	41.5	82	8.7	0.0001
Post-op TIA	48.6	82	8.3	



**Fig. 2:** Pre and post op TIA. X-axis showing no of pts. and y-axis showing TIA in°

- Mean pre-op Angle opening distance (AOD-500  $\mu\text{m}$ ) recorded was  $447.5 \pm 149.8 \mu\text{m}$  that increased to  $609.5 \pm 169.8 \mu\text{m}$  post-operatively with significant p-value of 0.0002 ( $< 0.05$ ).

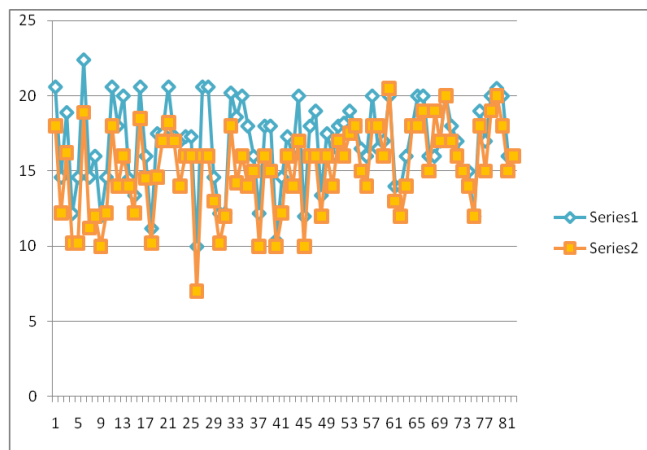
Anterior Chamber (AOD-500 $\mu\text{m}$ )	Mean	n	Std. Deviation	p-value
Pre-op (AOD-500 $\mu\text{m}$ )	447.5	82	149.8	0.0002
Post-op (AOD-500 $\mu\text{m}$ )	609.5	82	169.8	



**Fig. 3:** Pre and post op AOD. X-axis showing no of pts. and y-axis showing AOD-500 in  $\mu\text{m}$ .

- Mean Pre-op IOP recorded using Goldmann Applanation Tonometer was  $16.8 \pm 2.8$  mm Hg that declined to  $15.1 \pm 2.9$  mmHg post-operatively with significant p-value of 0.00001 ( $< 0.05$ ).

Intraocular Pressure (IOP)	Mean	n	Std. Deviation	p-value
Pre-IOP	16.8	82	2.8	0.00001
Post-IOP	15.1	82	2.9	



**Fig. 4:** Pre and post op IOP. X-axis showing no of pts. and y-axis showing IOP in mmHg.

**DISCUSSION**

This study is based on a simple question, “Does cataract extraction improve aqueous outflow or not?” To prove this, we conducted this study. For which, we included patients with senile cataract having uneventful cataract surgery while excluding glaucoma patients and patients with previous intra-ocular surgery to minimize confounding factor. Anterior chamber angle parameters were being studied pre and post-operatively using AS-OCT.

Various studies have been done in glaucomatous as well as non-glaucomatous eyes to determine changes in anterior chamber configuration after cataract surgery. In glaucoma patients, it makes the basis for clear lens extraction and IOL implantation to reduce intra-ocular pressure (IOP)<sup>8</sup>.

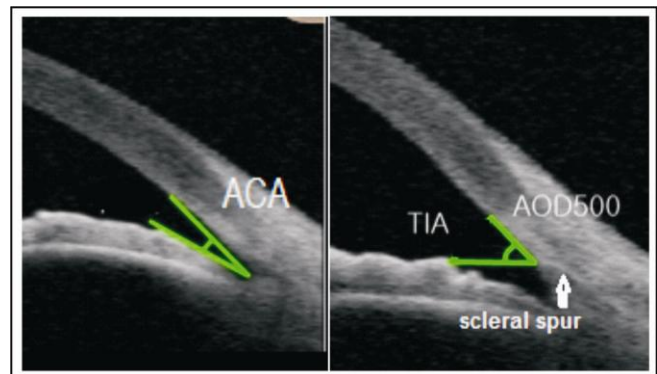
In a study published by Kim et al 11 eyes of 11 patients with angle closure glaucoma (ACG) and 12 eyes of 12 patients with open angle glaucoma (OAG) were included. The results showed that central ACD and angle parameters as measured by AS-OCT

increased significantly in eyes with glaucoma ( $p < 0.05$ ) after cataract extraction. Before surgery, mean central ACD in the ACG group was approximately 1.0 mm smaller than that in the OAG group ( $p < 0.001$ ). After surgery, mean ACD of the ACG group was still significantly smaller than that of the OAG group. In the ACG group, postoperative IOP at the final visit was significantly lower than preoperative IOP ( $p = 0.018$ )<sup>9</sup>.

Another study compared the role of cataract surgery in normal population with only cataract and in patients with both cataract and normal tension glaucoma (NTG) using swept source-optical coherence tomography (SS-OCT). And they concluded that angle parameters remarkably increased in both groups but IOP changes were only statistically significant in patients with normal tension glaucoma<sup>10</sup>.

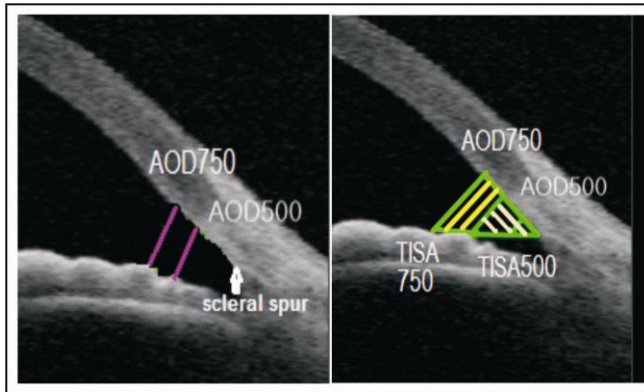
A study published by Junejo et al showed the effect of uneventful cataract surgery on anterior chamber depth (ACD) using ultrasonography A-Scan in 74 healthy eyes. Results showed that the mean ACD after 1 day of cataract surgery was  $3.46 \pm 0.44$ mm after 1 week of surgery was  $3.64 \pm 0.46$ mm and after 1 month of surgery was  $3.81 \pm 0.46$ . mm Significant increase of  $0.73 \pm 0.58$  mm ( $p < 0.0001$ ) in the mean ACD was seen after 1 month of uneventful cataract surgery<sup>11</sup>.

There are various angle parameters which include



**Fig. 1:** Anterior chamber angle (ACA) is the angle between the iris anterior surface and that of the posterior corneal surface with its apex in the angle recess. Trabecular Iris angle (TIA) is the angle that is measured with its apex in the scleral spur and the arms 500 μm from the scleral spur passing through a point on the trabecular meshwork and a perpendicular point on the iris.

ACA, TIA, AOD-500, AOD-750, TISA-500, TISA-750 which are being discussed in following paragraph along with diagrammatic illustrations.

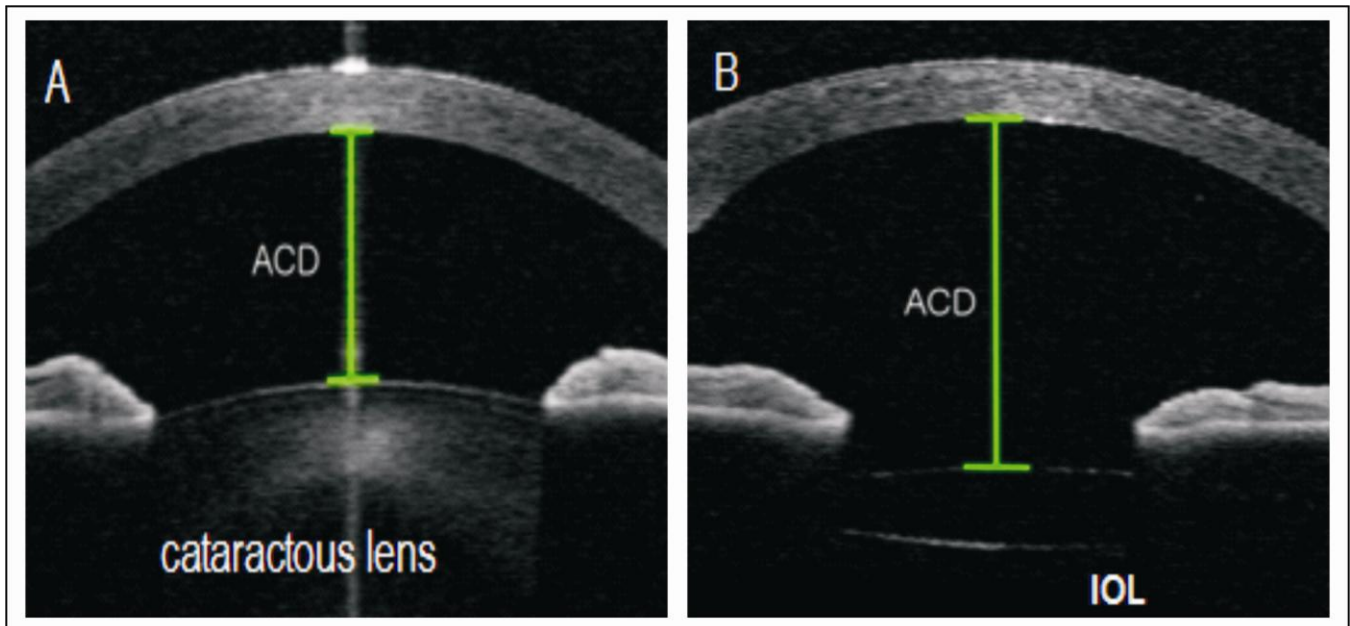


**Fig 2:** Angle opening distance at 500  $\mu\text{m}$  (AOD-500) and 750  $\mu\text{m}$  (AOD-750) is the distance from the corneal endothelium to the anterior surface of iris just perpendicular to a line drawn along the trabecular meshwork at 500 and 750  $\mu\text{m}$  from scleral spur. Trabecular-iris space areas (TISA) defined as the areas bounded by the corneal endothelium, trabecular meshwork, and anterior iris surface out to a distance of 500  $\mu\text{m}$  or 750  $\mu\text{m}$  from the scleral spur.

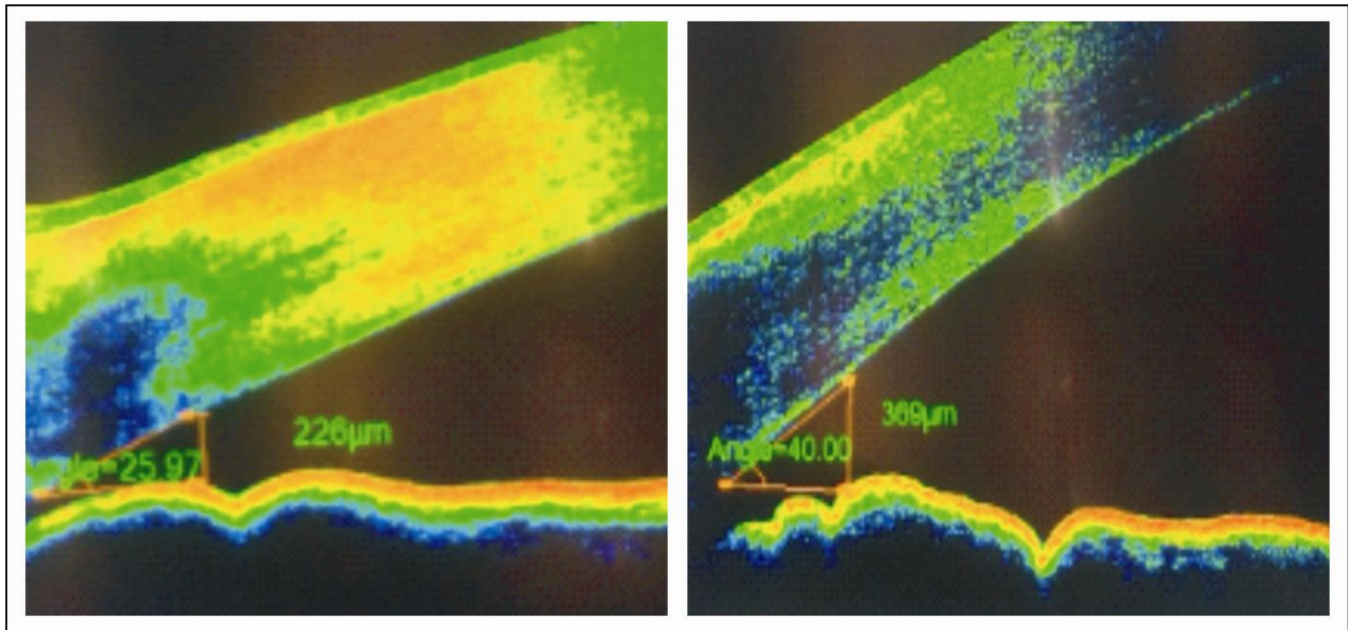
In this study, we included Trabecular iris angle (TIA) and Angle opening distance at 500 $\mu\text{m}$  (AOD500). Both of these actually specify ACA depth and width and are standardized as well. Reason not to include ACA is that it was difficult to identify proper angle recess in many patients and thus it can lead to reduced study sensitivity. It is important to note that ACA depth is different from Anterior chamber depth (ACD) and this study doesn't include ACD that is the distance from corneal endothelium at the center of cornea to the anterior surface of lens<sup>12</sup>. Though previous studies included ACD change that can be well explained on this fact that thick cataractous lens is replaced with a thin intra-ocular lens that will ultimately deepen the AC<sup>13</sup>. Another limitation for this parameter is that it includes some portion of posterior chamber when measured in eyes with intra-ocular lens while we are only concerned about anterior chamber.

It was very surprising to note that after cataract surgery, anterior chamber angle depth and width increased when examined via Anterior segment OCT(AS-OCT) giving quantitative proof by measuring TIA and AOD500 pre and post-operatively as documented in some previous studies as well.

In this study, we included surgeries with only foldable intra-ocular lenses to eliminate confounding factor, single piece IOL's with an optic diameter of 6.0



**Fig 3:** A) ACD with thick cataractous lens.  
 B) ACD with thin IOL. Note that little part of post. Chamber is also included in ACD measurement when IOL is present.



**Fig 4:** A) Pre-op TIA of 25.97° and Pre-op AOD-500 of 226µm in temporal quadrant of Left eye.  
 B) Post-op TIA being 40.00° and Post-op AOD-500 being 369 µm showing an increase in anterior chamber angle depth and width.

mm, though of different manufacturing companies. No statistically significant difference was found in study parameters among different types of IOL's. This is exactly in accordance with previous studies.

Anterior segment OCT (AS-OCT) being non-contact makes it very feasible for patient as well as for observer to use and gives instant best quality high resolution images<sup>14</sup> which can be stored and reproduced afterwards. It uses infrared radiations which are absorbed by posterior pigment epithelium of ciliary body thus reliable view of ciliary body and of posterior structures can't be obtained.<sup>15</sup> Initially OCT machine was designed to see status of macula, retina and optic disc but now it's been largely used for anterior segment configuration. Many studies used AS-OCT to sub-classify angle closure glaucoma<sup>16,17,18</sup>, to differentiate phacomorphic angle closure from acute angle closure eyes<sup>19</sup> and also from mature cataract not causing phacomorphic glaucoma.<sup>20</sup> So recent studies are using AS-OCT in a very novel way even to see responses of treatment modalities such as to evaluate changes over time in anterior chamber angle anatomy following laser peripheral iridotomy (LPI)<sup>21</sup> and many more. In our study, we proved that anterior chamber angle depth and width increases after cataract surgery thus increasing aqueous outflow and reducing intra-ocular pressure(IOP) which makes

basis for clear lens extraction in uncontrolled angle closure glaucoma<sup>22,23,24</sup> due to intumescent cataract.

## CONCLUSIONS

In the light of above mentioned results and discussion, it is concluded that cataract extraction and intra-ocular lens implantation causes widening of anterior chamber angle (ACA) along with increasing anterior chamber angle depth (ACA-D) thus lowering intra-ocular pressure which is a direct evidence of improved aqueous outflow. And also that anterior segment OCT is an efficient method for determining anterior chamber angle changes.

## Author's Affiliation

Hafiza Sadia Imtiaz,  
 PGR II, Ophthalmology  
 DHQ, UTH, Gujranwala

Dr. Irfan Qayyum Malik  
 Associate Professor, Ophthalmology  
 DHQ, UTH, Gujranwala

Farhan Ali  
 Assistant professor, Ophthalmology  
 DHQ, UTH, Gujranwala

**Role of Authors**

Hafiza Sadia Imtiaz

Manuscript writing, Data collection.

Dr. Irfan Qayyum Malik

Supervisor, Surgeon.

Dr. Farhan Ali

Data collection, Surgeon.

**REFERENCES**

1. **Jaggernath J, Gogate P, Moodley V, Naidoo K.** Comparison of Cataract Surgery Techniques: Safety, Efficacy, and Cost-Effectiveness. *European Journal of Ophthalmology*, 2014; 24 (4): 520-526.
2. **Baxant A, Hornová J.** Anterior Chamber Morphometry before and after Cataract Surgery. *Journal of Clinical & Experimental Ophthalmology*, 2016; 07 (02).
3. **Cetinkaya S, Dadaci Z, Yener H, Acir N, Cetinkaya Y, Saglam F.** The effect of phacoemulsification surgery on intraocular pressure and anterior segment anatomy of the patients with cataract and ocular hypertension. *Indian Journal of Ophthalmology*, 2015; 63 (9): 743.
4. **Cui S, Zou Y, Li Q, Li L, Zhang N, Liu X.** Gonioscopy and Ultrasound Biomicroscopy in the Detection of Angle Closure in Patients with Shallow Anterior Chamber. *Chinese Medical Sciences Journal*, 2014; 29 (4): 204-207.
5. **Alfarhan H, Al Mutairi R.** Anterior segment biometry using ultrasound biomicroscopy and the Artemis-2 very high frequency ultrasound scanner. *Clinical Ophthalmology*, 2013; 7: 141-147.
6. **Salcan I, Aykan U, Yildirim O, Kanik A.** Quantitative ultrasound biomicroscopy study of biometry of the lens and anterior chamber. *European Journal of Ophthalmology*, 2011; 22 (3): 349-355.
7. **Kim M, Park K, Kim T, Kim D.** Changes in Anterior Chamber Configuration after Cataract Surgery as Measured by Anterior Segment Optical Coherence Tomography. *Korean Journal of Ophthalmology*, 2011; 25 (2): 77.
8. **Hsia Y, Moghimi S, Coh P, Chen R, Masis M, Lin S.** Anterior segment parameters as predictors of intraocular pressure reduction after phacoemulsification in eyes with open-angle glaucoma. *Journal of Cataract & Refractive Surgery*, 2017; 43 (7): 879-885.
9. **Kim M, Park K, Kim T, Kim D.** Anterior Chamber Configuration Changes after Cataract Surgery in Eyes with Glaucoma. *Korean Journal of Ophthalmology*, 2012; 26 (2): 97.
10. **Lee W, Bae H, Kim C, Seong G.** The change of anterior segment parameters after cataract surgery in normal-tension glaucoma. *International Journal of Ophthalmology*, 2017; 10 (8): 1239-1245.
11. **Junejo M, Chaudhry T.** Anterior Chamber Depth Changes after Uneventful Phacoemulsification. *Pakistan Journal of Ophthalmology*, 2016; 32 (1): 31-35.
12. **Lubis Z, Dewi M, Delfi.** Change in Anterior Chamber Depth and Intraocular Pressure after Phacoemulsification Surgery of Senile Cataract. *International Journal of Scientific and Research Publications (IJSRP)*. 2018; 8 (8).
13. **Engren A, Behndig A.** Anterior chamber depth, intraocular lens position, and refractive outcomes after cataract surgery. *Journal of Cataract & Refractive Surgery*, 2013; 39 (4): 572-577.
14. High resolution anterior segment OCT and lamellar corneal surgery. *Acta Ophthalmologica*. 2017; 95.
15. **Guzman C, Gong T, Nongpiur M, Perera S, How A, Lee H et al.** Anterior Segment Optical Coherence Tomography Parameters in Subtypes of Primary Angle Closure. *Investigative Ophthalmology & Visual Science*, 2013; 54 (8): 5281.
16. **Kwon J, Sung K, Han S, Moon Y, Shin J.** Subclassification of Primary Angle Closure Using Anterior Segment Optical Coherence Tomography and Ultrasound Biomicroscopic Parameters. *Ophthalmology*, 2017; 124 (7): 1039-1047.
17. **Li F, Zhang X. Re: Kwon et al.** Subclassification of primary angle closure using anterior segment optical coherence tomography and ultrasound biomicroscopic parameters (*Ophthalmology*, 2017; 124: 1039-1047). *Ophthalmology*, 2017; 124 (10): e79.
18. **Nouri-Mahdavi K.** Anterior segment optical coherence tomography in subtypes of angle closure glaucoma. *Journal of Current Ophthalmology*, 2016; 28 (4): 159-160.
19. **Moghimi S, Ramezani F, He M, Coleman A, Lin S.** Comparison of Anterior Segment-Optical Coherence Tomography Parameters in Phacomorphic Angle Closure and Acute Angle Closure Eyes. *Investigative Ophthalmology & Visual Science*, 2015; 56 (13): 7611.
20. **Mansouri M, Ramezani F, Moghimi S, Tabatabaie A, Abdi F, He M et al.** Anterior Segment Optical Coherence Tomography Parameters in Phacomorphic Angle Closure and Mature Cataracts. *Investigative Ophthalmology & Visual Science*, 2014; 55 (11): 7403.
21. **Zhekov I, Pardhan S, Bourne R.** Ocular coherence tomography-measured changes over time in anterior chamber angle and diurnal intraocular pressure after laser iridotomy: IMPACT study. *Clinical & Experimental Ophthalmology*, 2018.
22. **rown R, Zhong L, Lynch M.** Clear lens extraction as treatment for uncontrolled primary angle-closure glaucoma. *Journal of Cataract & Refractive Surgery*, 2014; 40 (5): 840-841.
23. **Potop V, Corbu C.** The role of clear lens extraction in angle closure glaucoma. *Romanian Journal of Ophthalmology*, 2017; 61 (4): 244-248.
24. **Sung K, Lee J, Kim J.** Clear lens extraction as the first line treatment of primary angle closure/primary angle closure glaucoma. *Annals of Eye Science*, 2017; 2: 6-6.