

Anterior Chamber Depth Changes after Uneventful Phacoemulsification

Mustafa Kamal Junejo, Tanveer Anjum Chaudhry

Pak J Ophthalmol 2016, Vol. 32, No. 1

See end of article for authors affiliations

Correspondence to:
Mustafa Kamal Junejo
Instructor Ophthalmology
Section of Ophthalmology,
Department of Surgery
Aga Khan University, Karachi,
Pakistan
E-mail: mkjunejo@yahoo.com
Received: October 30, 2015
Accepted: April 10, 2016.

Purpose: To measure changes in anterior chamber depth (ACD) after uneventful cataract surgery through phacoemulsification along with intraocular lens (IOL) implantation in healthy eyes using ultrasonography (Amplitude Scan).

Study Design: Prospective observational clinical case series.

Place and duration of Study: Section of Ophthalmology, department of surgery, Aga Khan University Hospital Karachi Pakistan from September 2011 to March, 2012.

Material and Methods: Seventy Four eyes (74 patients) underwent Ultrasonography A Scan to evaluate anterior chamber configuration before, 1 day after, 1 week after and 1 month post-operative. We measured central ACD. Pre-operative and post-operative data was compared by using paired t tests.

Results: A total of 74 subjects were enrolled in this study. There were 42 males (56.8%) and 32 females (43.2%). Before surgery, overall mean anterior chamber depth (mm) ACD was 3.02 ± 0.43 ; in males was 3.07 ± 0.43 and in females was 2.96 ± 0.43 . Overall, the mean ACD after 1 day of cataract surgery 3.46 ± 0.44 , after 1 week of surgery was 3.64 ± 0.46 , and after 1 month of surgery was 3.81 ± 0.46 . Significant increase of 0.73 ± 0.58 mm ($p < 0.0001$) in the mean ACD was seen after 1 month of surgery. However, mean difference in ACD after 1 month of surgery between male and female groups was 0.11 ± 0.09 ; which was not statistically significant ($p = 0.42$). After uneventful phacoemulsification along with IOL implantation, the anterior chamber angle depth increased markedly.

Conclusion: Following uneventful phacoemulsification along with Intraocular lens implantation, the ACD markedly increased which, was statistically significant. Ultrasound A Scan is simple and easily available tool for obtaining quantitative data about anterior chamber depth.

Keywords: Cataract, Anterior Chamber Depth, Phacoemulsification, Ultrasonography A Scan.

INTRODUCTION

Cataract surgery is the most common surgical procedure done worldwide. In phacoemulsification cataractous lens is extracted after lens is crushed by ultrasound waves and then suctioned out of the capsule and intraocular lens (IOL) is implanted in capsule to obtain good visual acuity post operatively.¹

Theoretical formulas for the calculation of axial length, IOL power calculation and Anterior chamber depth measurements has been evolving for the better outcomes of cataract surgery. SRK/T being one of the older formulas measures only axial Length (AL), keratometry and Anterior Chamber depth (ACD) which is calculated from the corneal curvature as compared to newer formulas which involve

measurements of anterior chamber depth preoperatively which, predicts the postoperative effective lens position (ELP) and postoperative refraction indirectly.^{1,2} Cataract extraction with intraocular lens (IOL) implantation results in widening of the anterior chamber angle and depth to deepen in healthy and especially in glaucomatous eyes.³ Advanced imaging studies have proven that crystalline lens pushes the peripheral iris anteriorly and hence causes narrowing of anterior chamber angle particularly in cataractous lenses.⁴ Several methods have been used in previous studies to calculate anterior chamber depth after cataract surgery.

The object of this study was to measure changes in the anterior chamber depth after uneventful phacoemulsification with IOL implantation in healthy eyes using A Scan. We gathered quantitative data from normal Pakistani eyes as measured by A Scan Ultrasound and standardized parameters of anterior chamber were compared.

MATERIALS AND METHODS

This prospective observational clinical case series study conducted at section of Ophthalmology, department of surgery, Aga Khan University Hospital Karachi Pakistan from September 2011 to March, 2012 comprised of 74 eyes from 74 consecutive patients who underwent cataract surgery from September 2011 to December 2011. Patients Age, Gender and Eye whether right or left were kept under consideration for the study. Axial lengths were obtained using A-Scan. Single examiner took measurements of all patients on different visits. Anterior chamber depth measurements were taken on once pre-operative visit and thrice on post-operative visits i.e. 1 day, 1 week and 1 month post-operatively. Verbal consent was taken from all patients who participated in this study.

Patients who consented for procedure. Those whose Intra ocular lens was implanted in the capsular bag and those patients who completed all postoperative follow up visits were included in this study.

A thorough eye examination was performed pre operatively. The visual acuity was measured using the Snellen's chart. Nuclear grading (1 to 4) was performed using a cobalt blue filter light and the type of cataract (cortical, nuclear, posterior sub capsular and polar) was noted by slit lamp biomicroscopy. Keratometric values were measured with a Javal keratometer, and mean of 2 values taken from the

main axis was calculated. The axial length was measured with A-scan ultrasonography and IOL power calculation by the SRK T and Holladay formulas corresponding to respective axial lengths. Posterior segment examination was done with +90.0 diopter lens in eyes without dense cataract. B-scan ultrasonography was used in those patients whose posterior segment examination was not possible due to their dense cataracts. The ACD was measured by A-scan ultrasonography the day before surgery and 1 day, 1 week, and 1 month postoperatively by same examiner. Average of the four consecutive measurements was calculated and used in the study.

Surgery was performed using topical anaesthesia with propacaine hydrochloride (63 eyes; 85%) and retrobulbar anaesthesia with xylocaine 2% (11 eyes; 15%). The same surgeon performed all surgeries. A 3 - plane clear corneal incision was made in the steep meridian. A capsulorrhexis ranging from 4.0 mm to 5.0 mm was made with cystotome, and cortical-cleaving, hydro dissection and hydro delineation were performed. The nucleus was sculpted and emulsified through Stop-and-Chop and Divide and Conquer techniques. After cortical clean up, an injectable acrylic aspheric IOL with a 6.0 mm optic and 12.5 mm haptic diameter was implanted in the bag. The incisions were not sutured. Postoperatively, patients were prescribed topical antibiotics and topical steroids as 01 hourly on the day of surgery, 02 hourly on 1st post-operative day and tapered down in 4 weeks on weekly basis as QID, TID and BID, then stopped.

Statistical Analysis was done on SPSS version 19.0 for Windows. Frequencies and percentages were calculated for categorical variables like gender and age groups; and median were computed for numerical variables like age. Tables and charts were used to present the results. Paired t-test was used to compare means pre and post operatively. Independent t -test was performed to compare ACD changes between gender groups. $P < 0.05$ was considered to be statistically significant.

RESULTS

Total of 74 eyes were recruited in this study {male= 42 (56.8%), female = 32 (43.2%)}. 64.9% eyes were of right side with frequency and percentage of 48 and 64.9%, remaining one (left sided) with frequency and percentage of 26 and 35.1%. 51 patients (68.9%) of our study population were myopic and remaining 23 patients (31.0%) were hypermetropic (Table 1).

Table 1: Characteristics of the study population
n= No. of Eyes.

Age (years)	Frequency	Percent
Mean 59.7 ± 7.9	n = 74	100%
Gender		
Male	42	56.8
Female	32	43.2
Eye		
Right	48	64.9
Left	26	35.1
Refractive Error		
Myopia	51	68.9
Hypermetropia	23	31.0

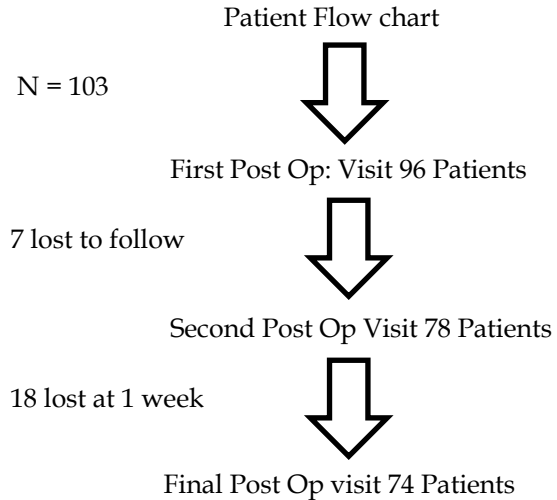


Figure 1: Flow chart of Patients showing number of patients who lost to follow during postoperative visits.

Table 2: Mean anterior chamber depth (ACD) after cataract surgery (n = 74 eyes).

AC Depth (mm)	Gender	Mean	Std. Deviation	Number of subjects
Before surgery	Male	3.07	0.43	42
	Female	2.96	0.43	32
	Overall	3.02	0.43	74
1 day after surgery	Male	3.45	0.48	42
	Female	3.47	0.40	32
	Overall	3.46	0.44	74
1 week after surgery	Male	3.67	0.51	42
	Female	3.60	0.39	32
	Overall	3.64	0.46	74
1 month after surgery	Male	3.83	0.49	42
	Female	3.77	0.43	32
	Overall	3.81	0.46	74

According to **table 2** mean and standard deviation were measured gender wise. Mean anterior chamber depth (ACD) before surgery, 1 day after surgery, 1 week after surgery and 1 month after surgery in male was 3.07 ± 0.43, 3.45 ± 0.48, 3.67 ± 0.51 and 3.83 ± 0.49. Similarly Mean anterior chamber depth in females was 2.96 ± 0.43, 3.47 ± 0.40, 3.60 ± 0.39 and 3.77 ± 0.43 with overall Mean of 3.02 ± 0.43, 3.46 ± 0.44, 3.64 ± 0.46 and 3.81 ± 0.46.

There was statistically significant increase in the mean ACD, from 3.02 ± 0.43mm preoperatively to 3.81 ± 0.46mm 1 month after surgery (p < 0.0001); an increase of 0.73 ± 0.58mm. However, when mean ACD one month after surgery was compared between male (3.83 ± 0.49 mm) and female (3.77 ± 0.43mm) groups, no statistically significant difference was found (p = 0.42).

DISCUSSION

According to this study uneventful Phacoemulsification with in the bag injectable intraocular lens implantation widens the anterior chamber angle and increases anterior chamber depth by pushing back the iris lens diaphragm.

Advantage of anterior chamber depth after phacoemulsification with intra ocular lens implantation surgery is that deep postoperative anterior chamber facilitates aqueous drainage more as compared to anterior chamber with normal lens in human eyes. Most of the subjects with ocular hypertension before cataract surgery absolutely get normal IOP levels after cataract surgery and doesn't require management anymore.¹⁻⁴

In this prospective clinical case series study 103 patients were enrolled for the study but only 74 patients followed till last visit. It means 103 patients got measured their anterior chamber depth preoperatively and lost to follow up were 29 patients. To the best of author's knowledge no one has conducted this study in Pakistani population and the purpose of this study is to calculate that how much percent anterior chamber depth increases after uneventful phacoemulsification and IOL implantation.

The overall increase in mean anterior chamber depth of 74 patients after 4 weeks of surgery was 790 microns which is evident with other studies as well^{1,2}. There was increase in overall anterior chamber depth of 440 microns 1 day after surgery, 620 microns one week after surgery, followed by overall increase in anterior chamber depth of 740 microns after one month of surgery (table 2).

Other studies have demonstrated increase in anterior chamber depth in normal population after phacoemulsification by measuring depth by different methods like Scheimpflug or ultrasound biomicroscope imaging methods.⁴ Hayashi et al found out by Scheimpflug imaging that width and depth of anterior chamber angle increased significantly i.e. 39.7% after cataract extraction followed by IOL implantation.⁴⁻⁸

However increase in Anterior chamber depth in this study is somehow less i.e. 26.1% than reported by other investigators which may be possibly that our group of patients were more myopic than others as it has been reported that hypermetropes show more change in anterior chamber depth than myopes. Difference between our study and study conducted by

Dooley et al, is that refractive status of patients were not measured in our study but mean age of most of the patients in both the studies was 69 years, other major difference between the two studies is of ethnic groups that in our study all patients are Asians as compared to white Caucasians in the study of Dooley et al.⁵⁻¹²

Nonaka et al, reported that lens plays important role in pathogenesis of primary angle closure glaucoma because of its anatomic features like lens thickness which increases with age, with cataractous changes and relatively its anterior positioning, hence he proved that lens extraction would widen the anterior chamber angle and therefore resolve pupillary block glaucoma.^{4,6-8}

Postoperative capsular shrinkage and IOL positioning also alters anterior chamber depth. Previous studies have shown change in anterior chamber depth with different types of IOL designs and types.⁹⁻¹²

Matsuura et al in 1989 also have reported that anterior chamber depth increased after cataract extraction and IOL implantation. Some other investigators reported rather shallowing of anterior chamber (Yoshida et al 1989).^{10,17}

Thill - Schwaninger and Giers in 1989 suggested that anterior chamber depth depends upon different shapes of IOL haptics.^{10,20}

Other techniques should be used to calculate change in anterior chamber depth and complete morphology.

We only measured Anterior chamber depth through Ultrasound A scan so this is being the limitation of our study because for proper Anterior chamber assessment we need to assess all the parameters such as anterior chamber angle, volume, central and peripheral depths and last but not the least complete corneal topography through Anterior SegmentOCT.

CONCLUSION

This study proves that anterior chamber depth increases approximately 26% after uneventful cataract surgery with intra ocular lens in capsular bag implantation which, helps in aqueous drainage by pushing back iris lens diaphragm and widening the anterior chamber angle, hence prevents improper diagnosis and unnecessary treatment of glaucoma entities.

Author Affiliation

Dr. Mustafa Kamal Junejo
Instructor Ophthalmology Section of Ophthalmology,
Department of Surgery, Aga Khan University,
Karachi, Pakistan

Dr. Tanveer Anjum Chaudhry
Section Head of Ophthalmology
Department of Surgery, Aga Khan University Hospital
Karachi, Pakistan

Role of Author

Mustafa Kamal Junejo
Data collection, Manuscript writing and Statistics.

Tanveer Anjum Chaudhry
Data collection.

REFERENCES

1. **Arai M, Ohzuno I, Zako M.** Anterior chamber depth after posterior chamber intraocular lens implantation. *Actaophthalmologica.* 1994; 72 (6): 694-7.
2. **Doganay S, Bozgul Firat P, Emre S, Yologlu S.** Evaluation of anterior segment parameter changes using the Pentacam after uneventful phacoemulsification. *Actaophthalmologica.* 2010; 88 (5): 601-6.
3. **Dooley I, Charalampidou S, Malik A, Loughman J, Molloy L, Beatty S.** Changes in intraocular pressure and anterior segment morphometry after uneventful phacoemulsification cataract surgery. *Eye,* 2010; 24 (4): 519-27.
4. **Engren AL, Behndig A.** Anterior chamber depth, intraocular lens position, and refractive outcomes after cataract surgery. *J Cataract Refract Surg.* 2013; 39 (4): 572-7.
5. **Hayashi K, Hayashi H, Nakao F, Hayashi F.** Changes in anterior chamber angle width and depth after intraocular lens implantation in eyes with glaucoma. *Ophthalmology,* 2000; 107 (4): 698-703.
6. **Huang G, Gonzalez E, Peng P-H, Lee R, Leeungurasatien T, He M, et al.** Anterior chamber depth, iridocorneal angle width, and intraocular pressure changes after phacoemulsification: narrow vs. open iridocorneal angles. *Archives of ophthalmology,* 2011; 129 (10): 1283-90.
7. **Kim M, Park KH, Kim T-W, Kim DM.** Changes in anterior chamber configuration after cataract surgery as measured by anterior segment optical coherence tomography. *Korean Journal of Ophthalmology,* 2011; 25 (2): 77-83.
8. **Nonaka A, Kondo T, Kikuchi M, Yamashiro K, Fujihara M, Iwawaki T, et al.** Angle widening and alteration of ciliary process configuration after cataract surgery for primary angle closure. *Ophthalmology,* 2006; 113 (3): 437-41.
9. **Norn M.** Depth of anterior chamber after cataract extraction. *British Journal of Ophthalmology,* 1978; 62 (7): 474-7.
10. **Simsek A, Ciftci S.** Evaluation of ultrasonic biomicroscopy results in anterior eye segment before and after cataract surgery. *Clinical ophthalmology (Auckland, NZ).* 2012; 6: 1931.
11. **Uçakhan ÖÖ, Özkan M, Kanpolat A.** Anterior chamber parameters measured by the Pentacam CES after uneventful phacoemulsification in normotensive eyes. *Actaophthalmologica.* 2009; 87 (5): 544-8.
12. **Wirtitsch MG, Findl O, Menapace R, Kriechbaum K, Koepl C, Buehl W, et al.** Effect of haptic design on change in axial lens position after cataract surgery. *Journal of Cataract and Refractive Surgery,* 2004; 30 (1): 45-51.
13. **Dawczynski J, Koenigsdoerffer E, Augsten R, Strobel J.** Anterior segment optical coherence tomography for evaluation of changes in anterior chamber angle and depth after intraocular lens implantation in eyes with glaucoma. *Eur J Ophthalmol* 2007; 17 (3): 363 - 367
14. **Kusano M; Tsuiki E; Uematsu M; Fujikawa A; Kumagami T; Suzuma K; Kitaoka T.** Changes In Anterior Chamber Depth And Refractive Power After Cataract Surgery With Or Without Simultaneous Vitreous Surgery. *Investigative Ophthalmology and Visual Science* March, 2012; Vol. 53: 6657.
15. **Melancia D, Pinto LA, Neves CM.** Cataract Surgery and Intraocular Pressure Departments of a Pharmacology and Neurosciences and Ophthalmology, Faculty of Medicine, Lisbon University, Lisbon , Portugal. *Ophthalmic Res.* 2015; 53: 141-148 DOI: 10.1159/000377635.
16. **Bilak S, Simsek A, Capkin M, Guler M, and Bilgin B.** Biometric and Intraocular Pressure Change after Cataract Surgery. *Optometry and Vision Science,* Vol. 92, No. 4, April 2015.
17. **Rękas M, Kucia KB, Konopińska J, MariakZ and Żarnowski T.** Analysis and Modeling of Anatomical Changes of the Anterior Segment of the Eye After Cataract Surgery with Consideration of Different Phenotypes of Eye Structure. *Current Eye Research* 2015; Volume 40, Issue 10: pages 1018-1027.
18. **Watanabe A, Shibata T, Ozaki M, Okano K, Kozaki K, and Tsuneoka H.** Department of Ophthalmology, The Jikei University School of Medicine, Tokyo, Japan. Change in Anterior Chamber Depth Following Combined Pars Plana Vitrectomy, Phacoemulsification, and Intraocular Lens Implantation Using Different Types of Intraocular Lenses. *Jpn J Ophthalmol.* 2010; 54: 383-386 DOI 10.1007/s10384-010-0840
19. **MirafTAB M, Hashemi H, Fotouhi A, Khabazkhoob M, Rezvan F, Asgari S.** Effect of anterior chamber depth on the choice of intraocular lens calculation formula in patients with normal axial length. *Middle East African Journal of Ophthalmology,* 2014; Volume 21, Issue 4: Page: 307-311.

20. **Shin HC, Subrayan V, Tajunisah I.** Changes in anterior chamber depth and intraocular pressure after phacoemulsification in eyes with occludable angles. J Cataract Refract Surg. 2010; 36: 1289 - 1295 Q 2010 ASCRS and ESCRS.