

# Orbital Rhabdomyosarcoma – A Case Series from North – West Pakistan

Ibrar Hussain<sup>1</sup>, Tajamul Khan<sup>2</sup>, Zaman Shah<sup>3</sup>, Zulfiqar Ali<sup>4</sup>

Department of Ophthalmology, <sup>1-3</sup>Khyber Teaching Hospital, Peshawar, <sup>4</sup>Teaching Hospital, Abbottabad

## ABSTRACT

**Purpose:** To find out the demographic characteristics, clinical behavior and outcome of Rhabdomyosarcoma in North West Pakistan.

**Study Design:** Retrospective case series.

**Place and Duration of Study:** Department of Ophthalmology, Khyber Teaching Hospital Peshawar Pakistan, from 2015 to 2019.

**Methods:** All patients with Orbital Rhabdomyosarcoma consulting our department were registered and a self-designed proforma was used to document demography, clinical features, management, and follow-up of all cases. At the end of study, the data was analyzed using SPSS version 25 and results compiled.

**Results:** Twelve patients with “Orbital Rhabdomyosarcoma” were included in the study with mean age of  $7.2 \pm 1.6$  years. Majority of patients presented with mass in upper lid with proptosis. CT-Scan and/or MRI orbit proved that in seven (58.3%) cases the mass was occupying the superior orbit, in 3 (25%) cases inferior orbit and in 2 (16.6%) cases the tumor was advanced enough to occupy the whole orbit. Biopsy showed embryonic type (66.7%), alveolar type (25%) and undifferentiated (8.3%) tumour. All patients received chemotherapy and radiotherapy with excision of tumor in 16.7% and exenteration in 41.7% patients. The course of follow-up extended from 7 to 24 months. Five (41.7%) patients felt well at the end of last follow-up and four (33.3%) developed recurrence. At the end of follow-up, 3 (25%) patients died of tumor.

**Conclusion:** In North West Pakistan patients with Orbital Rhabdomyosarcoma present late and the prognosis is poor due to not following the proper protocol for follow-up.

**Key Words:** Rhabdomyosarcoma, Orbital rhabdomyosarcoma, IRS Staging.

**How to Cite this Article:** Hussain I, Khan T, Shah Z, Ali Z. Orbital Rhabdomyosarcoma – A Case Series from North – West Pakistan. Pak J Ophthalmol. 2020; **36 (4)**: 396-401.

**Doi:** <https://doi.org/10.36351/pjo.v36i4.1075>

---

## INTRODUCTION

Orbital rhabdomyosarcoma (RMS) is a rare malignancy of childhood.<sup>1</sup> However, it is the most

common primary malignant tumor of the orbit in children.<sup>2</sup> The tumor arises from undifferentiated mesenchymal cells that have the capacity to differentiate into striated muscle.<sup>3</sup> It usually presents in the first decade of life with relatively sudden unilateral proptosis that may be associated with lid swelling. There is a male preponderance and the tumor has the tendency to involve the supero-medial part of the orbit.<sup>4</sup> Posteriorly located tumors may press upon the optic nerve thereby causing disc swelling and dimness of vision. Most common histological type of Rhabdomyosarcoma is “embryonal” type, which has better prognosis than other types.<sup>5</sup> Treatment of RMS

---

*Correspondence: Ibrar Hussain  
Department of Ophthalmology  
Khyber Teaching Hospital, Peshawar  
Email: dribrab@hotmail.com*

---

*Received: June 6, 2020  
Accepted: September 1, 2020*

is a combination of chemotherapy and external beam radiation with or without surgery.

Purpose of this study was to review the demographic features, clinical presentation, management and follow-up of patients of RMS presenting to a tertiary care hospital of North Western part of Pakistan.

## METHODS

It was a retrospective case series where the record of 12 patients, with orbital Rhabdomyosarcoma was evaluated and analyzed. These patients were admitted in "Orbit and Oculoplastics" department of Khyber Teaching Hospital, Peshawar Pakistan between 2015 and 2019. A proforma was designed in which age, gender, presenting symptoms, duration of symptoms, amount of proptosis and dystopia (where possible) was noted. After detailed history and examination, each patient underwent CT-Scan and/or MRI orbit, chest x-ray, abdominal ultrasound and complete blood examination. Incisional biopsy was done in all patients and sample was sent for histopathology. After confirmation of diagnosis, each patient consulted oncologist where most patients received chemotherapy and radiotherapy while others were sent back to our department for surgical management. Surgical excision of the tumor was carried out in two cases and exenteration in five cases. Few patients also needed chemotherapy and/or radiotherapy post-operatively, for which they consulted oncologist after surgery. The follow-up period of the patients was 7 months to 2 years.

Various variables including age, gender, visual acuity, amount of proptosis, histological type, treatment modality and post-treatment improvement at last follow-up was analyzed using SPSS-version 25.

## RESULTS

Twelve patients were included in this case series, out of which 8 (66.7%) were males and 4 (33.3%) were females. Mean age of all patients was  $7.2 \pm 1.6$  years and median age was 6 years. One patient presented at the age of one week with upper lid mass (Figure 1).

Seven (58.3%) patients presented with mass in upper lid with 5 (51.7%) having associated proptosis, 3 (25%) patients with swelling of lower lid and proptosis, 1 (8.3%) patient with proptosis and no lid swelling and finally one (8.3%) patient presented with

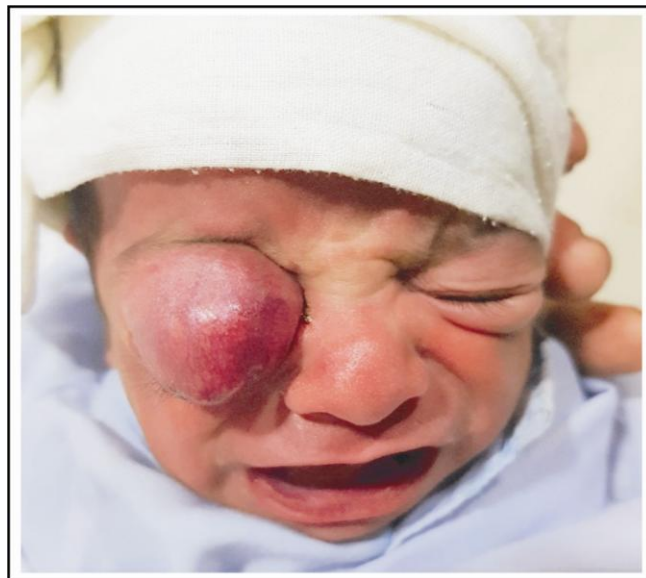

Fig. 1: Patient with Rhabdomyosarcoma.

marked proptosis and swelling of both upper and lower lids. Amount of proptosis could be measured in 6 (50%) patients and the mean difference of proptosis between affected and non-affected eye was  $5.8 \pm 3.9$  mm. CT-Scan and/or MRI of orbit proved that in seven (58.3%) cases the mass was occupying the superior orbit, in 3 (25%) cases inferior orbit and in 2 (16.6%) cases the tumor was advanced enough to occupy the whole orbit. At presentation, bony erosion was seen on CT-Scan in one (8.3%) case but during the course of follow-up, 2 (16.7%) other patients who developed recurrence, had bony erosions and extension of tumor into cranial cavity and ethmoidal sinuses. Incisional biopsy proved the diagnosis of RMS in all cases with embryonic type in 8 (66.7%), alveolar type in 3 (25%) and undifferentiated in 1 (8.3%) case. As far as Intergroup Rhabdomyosarcoma Study (IRS) group staging system is concerned, 2 (16.7%) of our cases fell into "Group II", 9 (75%) into "Group III" and 1 (8.3%) into "Group IV". None of our patients fell into "Group I".

All patients consulted oncologist. Four (33.3%) patients received chemotherapy (Vincristine, Actinomycin-D, Cyclophosphamide (VAC) and radiotherapy. Two patients underwent excision of the mass followed by chemotherapy (VAC) and radiotherapy. Five (41.7%) patients with huge tumors received chemotherapy (VAC) followed by exenteration. The course of follow-up extended from 7 to 24 months. Five (41.7%) patients felt well at the end

**Table 1:** Demography, Clinical Features, Management and Outcome of all patients. (F = Female, LL = Lower Lid, M = Male, Radio = Radiotherapy, UL = Upper Lid, VAC = Vincristin, Actinomycin-D, Cyclophosphamide).

S/N	Age (Year)	Gender	Laterality	Presentation	Tumor Location in Orbit	Histology	Treatment	Ultimate Outcome
1.	6	M	R	UL swelling with Proptosis	Superior	Embryonal	VAC + Exentration + Radio	Passed away in 2 years
2.	19	M	R	UL swelling with Proptosis	Superior	RMS Undifferentiated	VAC + Exentration	Recurrence under treatment
3.	9	F	R	LL swelling with Proptosis	Inferior	Embryonal	Excisional biopsy + VAC	Ok till last follow-up
4.	12	M	R	UL swelling with Proptosis	Superior	Embryonal	VAC + Radio	Ok till last follow-up
5.	4	F	R	UL & LL swelling with Proptosis	Whole orbit	Alveolar	VAC + Exentration	Died after 2 years
6.	6	F	R	UL swelling with Proptosis	Superior	Alveolar	VAC + Exentration + Radio	Recurrence under treatment
7.	3	M	L	Proptosis	Inferior	Embryonal	VAC + Radio	Recurrence Under treatment
8.	4	M	R	LL swelling with Proptosis	Inferior	Embryonal	Excisional biopsy + VAC	Ok till last follow-up
9.	0.1	M	R	UL mass since birth	Upper Lid	Embryonal	Refused treatment	
10.	6	M	L	UL swelling	Superior	Embryonal	VAC + Radio	Ok till last follow-up
11.	15	M	L	Ulcerative LL mass with Proptosis	Inferior	Alveolar	Exentration + Radio	Recurrence Passed away after 1 year
12.	2	F	L	LL swelling with Proptosis	Inferior	Embryonal	VAC + Radio	Ok till last follow-up

of last follow-up, four (33.3%) developed recurrence for which surgical excision/debulking of the tumor was performed followed by radiotherapy. At the end of follow-up, 3 (25%) patients died of tumor. Table 1 represents demography, clinical features, management and outcome of all patients.

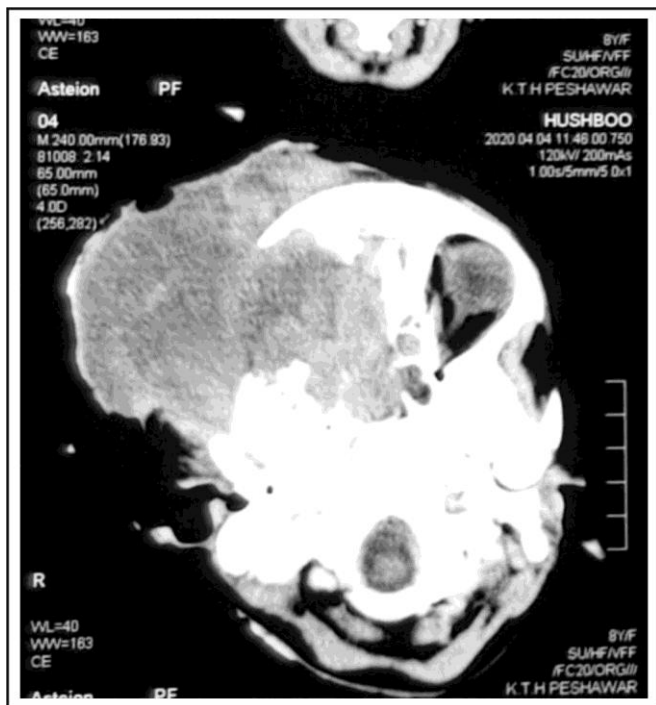
## DISCUSSION

Orbital rhabdomyosarcoma is a rare malignancy of childhood; however, it is the most common primary malignant tumor of the orbit. In a study from Punjab (Pakistan), RMS constituted 6.3% of total malignant orbital tumors.<sup>6</sup> In our case-series, the mean age of the patients was  $7.2 \pm 1.6$  years. In a study from South Pakistan (Karachi) the mean age for embryonal RMS was 10.4 years.<sup>7</sup> One of our patients had congenital rhabdomyosarcoma (embryonal type). Few case reports of congenital RMS have been mentioned in the literature.<sup>8</sup> Sueters M et al, described a unique case of fetal RMS detected in 3<sup>rd</sup> trimester of pregnancy by ultrasound examination.<sup>9</sup> After birth histopathological examination confirmed RMS with sparse alveolar

element. RMS is more common in boys and this is true for our cases where two third of the patients were boys.<sup>10</sup>

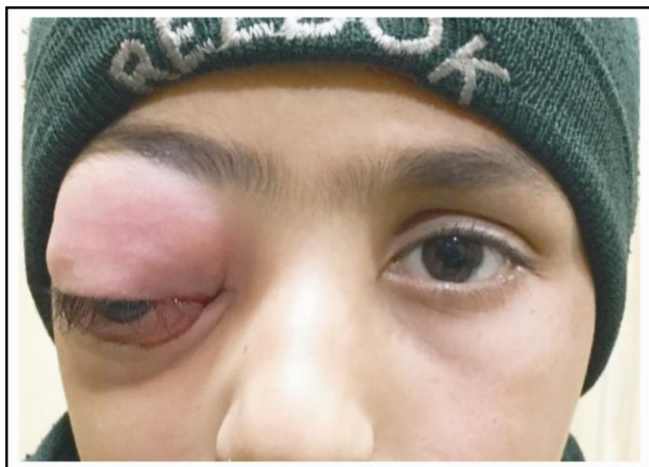Due to rapid growth of tumor in the orbit, presentation in most of the cases is in the form of relatively rapid proptosis. Ten (83.3%) of our patients presented with progressive proptosis for 2 – 4 months. In 2 (16.7%) cases there was no proptosis because of anteriorly located tumor in the upper orbit. Both of these cases presented with hard swelling in the upper lid. Posterior tumors, in addition to proptosis, tend to cause optic disc edema, choroidal folds and some degree of ophthalmoplegia. CT and MRI orbit are important for preoperative evaluation and to know the extent of tumor and also for follow-up.<sup>11</sup> CT scan helps in detecting bone involvement.<sup>12</sup> In our case series there was one case with bone erosion into maxillary sinus at presentation. Moreover, in the course of follow-up bony erosion with extension to cranial cavity and ethmoidal sinuses was found in 2 cases of recurrence (Figure 2).

Karcioglu ZA et al, stated in their research that



**Fig. 2:** CT-Scan showing Bony erosion in a huge recurrent Rhabdomyosarcoma.

there was correlation between location in the orbit and histology. Embryonal subtype was more frequently seen in superior orbit whereas alveolar subtype was more common in inferior orbit.<sup>3</sup> In our study out of 7 tumors involving the superior orbit, 5 (71.4%) were embryonal (Figure 2).



**Fig. 3:** Superior orbital Rhabdomyosarcoma with upper lid swelling.

The embryonal subtype is the most frequently observed subtype in children, accounting for approximately 60% to 70% of childhood

rhabdomyosarcomas.<sup>13</sup> Approximately 30% of children with rhabdomyosarcoma have the alveolar subtype. An increased frequency of this subtype is noted in adolescents.

Following biopsy, the tumor is staged according to "Intergroup Rhabdomyosarcoma Study."<sup>14,15</sup> This grouping is as follows:

Group I: Localized disease completely resected (excisional biopsy).

Group II: Microscopic disease remaining after biopsy.

Group III: Gross residual disease remaining after biopsy.

Group IV: Distant metastasis present at onset.

This classification is useful for treatment strategy and for prognosis prediction.<sup>10,16</sup>

Current management includes surgery, chemotherapy and radiotherapy.<sup>17,18</sup> Group I are treated with chemotherapy only VA (Vincristine and Actinomycin-D). Group II are treated with combination of chemotherapy (VA plus cyclophosphamide: VAC) and radiotherapy (36 Gy). Group III are treated with combination of chemotherapy (VAC) and radiotherapy (45 Gy). Group IV are treated with a combination of intensive chemotherapy and radiotherapy.<sup>7</sup>

In our case series no patient was included in group I. Two patients (16.7%) were in group II, nine (75%) patients had group III and one (8.3%) was in group IV at presentation. Due to multiple socio-economic factors in developing countries like ours, exact above mentioned international protocol for treatment of different groups could not be followed. Two patients with group II stage underwent excisional biopsy followed by chemotherapy (VAC) and were doing well at the end of their follow-up of about one and a half year. Eight patients with group III underwent chemotherapy (VAC) and radiotherapy but most of them received patchy therapy and did not complete the course. Therefore, four (50%) of those eight patients later presented with recurrence and they underwent exentration, followed by radiotherapy. Two of those patients passed away during the course of follow-up. In one patient with congenital RMS (group III), the treatment was refused by the parents. One patient in Group IV, underwent exentration followed by chemotherapy and radiotherapy to the orbit but passed away in three months. He had metastasis in the chest at presentation.

In good centers of the world where proper protocols for the treatment of orbital RMS is followed, overall survival is excellent for group I, II and III i.e., 95% at 5 years.<sup>4,19,20</sup> In our study the poor outcome seems to be due to late presentation and taking irregular treatment on the part of the patient due to multiple socioeconomic reasons including poverty and late approach to the centers, where treatment facilities are available. The patients also take irregular or no treatment due to the “myth” that cancer is untreatable.

Overall behavior of RMS is the same as other parts of the world. Advances in chemotherapy and radiotherapy have improved survival rates of patients with orbital RMS in developed countries.

Limitation of our study was the sample size as it is a rare disease. Multicenter study is needed to further study the pattern of disease across the country.

## CONCLUSION

In our set up overall prognosis is poor due to ignorance and non-adherence to the proper protocol for treatment by the patients. This can be improved by liaison between orbital surgeon and oncologist and proper education and counselling of the patient/parents about the treatment strategy and its importance. Moreover, governmental supporting agencies and NGOs working for cancer patients should come forward to support these patients.

## REFERENCES

1. **Malu KN, Ngbea JA, Mohammand H.** Primary orbital rhabdomyosarcoma in an 11-year-old boy: A management challenge in a resource limited environment. *J Med Trop.* 2015; **17**(1): 37.
2. **Bajaj MS, Pushker N, Chaturvedi A, Betharia SM, Kashyap S, Balasubramanya R, et al.** Orbital space occupying lesion in Indian children. *J Pediatr Ophthalmol Strabismus.* 2007; **44**: 106-111.
3. **Karcioglu ZA, Hadjistilianou D, Rozans M, DeFrancesco S.** Orbital rhabdomyosarcoma. *Cancer Control.* 2004; **11** (5): 328-333.
4. **Rootman J.** Neoplasia. Diseases of the orbit: a multidisciplinary approach, 54. Philadelphia: Lippincott Williams and Wilkins; 2003: p. 262–268.
5. **Olivier Pascual N, Calvo JM, Abelairas Gómez JM.** Orbital rhabdomyosarcoma: difficulties with European treatment protocol. *Arch Soc Esp Oftalmol.* 2005; **80**: 331–338.
6. **Khan AA, Sarwar S, Sadiq MA, Ahmad I, Tariq N.** Analysis of orbital malignancies presenting in a Tertiary Care Hospital in Pakistan. *Pak J Med Sci.* 2017; **33** (1): 70.
7. **Bhurgri Y, Mazhar A, Bhurgri H, Usman A, Malik J, Bhurgri A, et al.** Orbital Embryonal Rhabdomyosarcomain Karachi (1998-2002). *J Pak Med Assoc.* 2004; **54** (11): 561.
8. **Bentefouet TL, Dieng M, Keita A, Thiam I, Wane A.** Primitive Neonatal Orbital Rhabdomyosarcoma about a Case and Literature Review. *Austin Pathol.* 2019; **2** (1): 1007.
9. **Sueters M, Peek AM, Ball LM, Hogendoorn PC, Scherjon SA, de Keizer RJ, et al.** Prenatal detection of orbital rhabdomyosarcoma. *Arch Ophthalmol.* 2005; **123** (2): 276-279.
10. **Shields JA, Shields CL.** Rhabdomyosarcoma: Review for the ophthalmologist. *Surv Ophthalmol.* 2003; **48**: 39-57.
11. **Staibano S, Franco R, Tranfa F, Mezza E, Lo Muzio L, Strianese D, et al.** Orbital rhabdomyosarcoma: relationship between DNA ploidy, p53, bcl-2, MDR-1 and Ki67 (MIB1) expression and clinical behavior. *Anticancer Res.* 2004; **24**: 249–257.
12. **Terezakis SA, Wharam MD.** Radiotherapy for rhabdomyosarcoma: indications and outcome. *Clin Oncol.* 2013; **25**: 27–35.
13. **Parham DM, Ellison DA.** Rhabdomyosarcomas in adults and children: an update. *Arch Pathol Lab Med.* 2006; **130** (10): 1454-1465.
14. **Arndt C, Tefft M, Gehan E, Anderson J, Jenson M, Link M, et al.** A feasibility, toxicity, and early response study of etoposide, ifosfamide, and vincristine for the treatment of children with rhabdomyosarcoma: a report from the intergroup rhabdomyosarcoma study (IRS) IV pilot study. *J Pediatr Hematol Oncol.* 1997; **19**: 124–129.
15. **Blank LE, Koedooder K, van der Grient HN, Wolffs NA, van de Kar M, Merks JH, et al.** Brachytherapy as part of the multidisciplinary treatment of childhood rhabdomyosarcomas of the orbit. *Int J Radiat Oncol Biol Phys.* 2010; **77**: 1463–1469.
16. **Ruymann FB, Vietti T, Gehan.** Cyclophosphamide dose escalation in combination with vincristine and actinomycin D (VAC) in gross residual sarcoma: a pilot study without hematopoietic growth factor support evaluating toxicity and response. *J Pediatr Hematol Oncol.* 1995; **17**: 331–337.
17. **Breneman J, Meza J, Donaldson SS, Raney RB, Wolden S, Michalski J, et al.** Local control with reduced-dose radiotherapy for low-risk rhabdomyosarcoma: a report from the children’s oncology group D9602 study. *Int J Radiat Oncol Biol Phys.* 2012; **83**: 720–726.
18. **Tyl JW, Blank LE, Koornneef L.** Brachytherapy in orbital tumors. *Ophthalmology.* 1997; **104**: 1475–1479.

19. **Sohaib SA, Moseley I, Wright JE.** Orbital Rhabdomyosarcoma-the radiological characteristics. *Clin Radiol.* 1998; **53**: 357–362.
20. **Mazzoleni S, Bisogno G, Garaventa A, Cecchetto G, Ferrari A, Sotti G.** Outcomes and prognostic factors after recurrence in children and adolescents with nonmetastatic rhabdomyosarcoma. *Cancer*, 2005; **104**: 183–190.

### **Authors' Designation and Contribution**

Ibrar Hussain; Professor: *Concepts, Design, Literature search, Data acquisition, Data analysis, Statistical analysis, Manuscript preparation, Manuscript editing, Manuscript review.*

Tajamul Khan; Associate Professor: *Design, Literature search, Data acquisition, Data analysis, Statistical analysis.*

Zaman Shah; Associate Professor: *Literature search, Data acquisition, Manuscript preparation, Manuscript editing, Manuscript review.*

Zulfiqar Ali; Professor: *Literature search, Data analysis, Statistical analysis, Manuscript review.*

