

Incidental finding of microfilaria in a case of lymphoma-leukaemia

Gowardhan Vidula¹, Karmarkar Pragati², Wilkinson Anne², Maimoon Sabiha³

¹Assistant Professor, ²Associate Professor, ³Additional Professor- Department of Pathology, NKPSIMS & RC, Digdoh Hills, Hingna Road, Nagpur -440019.
v_gowardhan@rediffmail.com

Abstract:

Filariasis is a common health problem in developing countries like India. Microfilariae have been incidentally detected in FNAC (Fine needle aspiration cytology) of various lesions in clinically unsuspected cases of filariasis with absence of microfilariae in the peripheral blood. We report a case where patient was asymptomatic for the filarial disease, which was incidentally detected on cytological smears. There are only a few reported cases in cytology literature documenting association of microfilaria with lymphoma. Careful screening of FNAC smears might be helpful in detecting microfilariae, even in asymptomatic patients, especially in highly endemic areas.

Introduction:

Filariasis is a common health problem in developing countries like India. *Wucheria bancrofti* is responsible for 90% cases of filariasis (1). It causes disease by blocking lymphatic vessels. The diagnosis is conventionally made by demonstrating microfilariae in peripheral blood smear. However, microfilariae have been incidentally detected in FNAC (Fine needle aspiration) of various lesions in clinically unsuspected cases of filariasis with absence of microfilariae in the peripheral blood. Microfilaria have been detected by FNAC (Fine needle aspiration cytology) at different sites like breast, thyroid, lymph node, liver, lungs, bone marrow, body fluids and subcutaneous nodules (2). They have also been reported in association with various benign and malignant tumours although the role in tumorigenesis is controversial.

There are only a few reported cases in cytology literature documenting association of microfilaria with

lymphoma.

Case Report:

A 55-year-old female presented with abdominal lump and body ache. On examination, there was hepatosplenomegaly with axillary (0.5x0.5cm) and inguinal lymphadenopathy (2x2cm). FNAC from right inguinal lymph node was done.

Cytological findings:

The cytological findings were suggestive of Non-Hodgkin's lymphoma. Microfilaria was also present. It was identified to be *Wucheria Bancrofti* by the presence of a hyaline sheath, granules extending from the head to tail and the tail tip free of nuclei (Fig. 1 & 2).

Figure 1:
FNAC smear from left inguinal lymph node-Microfilaria of *Wucheria bancrofti* (tail tip free of nuclei) in a clear background (Papanicolaou stain X1000)

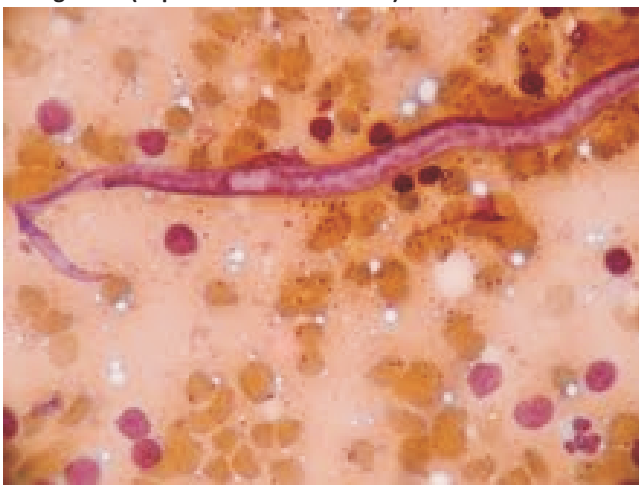
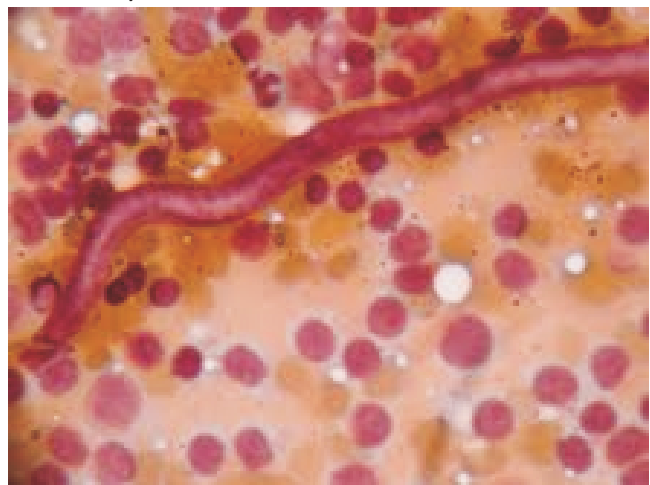


Figure 2:
FNAC smear from left inguinal lymph node. A microfilaria surrounded by neoplastic lymphoid cells. (Papanicolaou stain X1000)



Case Report

Peripheral smear findings:

Haematological features were suggestive of chronic lymphoid leukaemia. There was no eosinophilia. Microfilaria was not seen in Peripheral smear.

Discussion:

Filariasis presents with a wide spectrum of clinical manifestations, however a significant number of infected individuals in endemic areas remains asymptomatic throughout their life (3). They are an important source of infection in the community. Thus the disease and infection do not necessarily accompany each other (4). FNAC is valuable in detection of asymptomatic and clinically unsuspected cases of filariasis, though microfilaria in cytological smears is considered as incidental findings (5). In the study done by Walter A et al (6), the initial diagnosis was made from the cytological smear in all 35 cases; none had clinical filariasis. Microfilariae have been reported in association with neoplastic lesions such as squamous cell carcinoma of maxillary antrum, Ewing's sarcoma of bone, transitional cell carcinoma of bladder, Non-Hodgkin's lymphoma, and meningioma (7). In our case, microfilaria was incidentally found associated with leukemia – lymphoma.

The FNA smears revealed sheathed microfilaria, *Wucheria bancrofti* was confirmed by both cephalic end and tail tip free of nuclei (8). An association of microfilariae with Non-Hodgkin's lymphoma is known, as observed in our case. The patient was asymptomatic for the filarial disease, which was incidentally detected on cytological smears. The presence of microfilaria in association with tumors of lymph nodes and lymphatics can be explained as they are the normal habitation for the filarial organism (9). Various authors have expressed the opinion that because these parasites circulate in the vascular and lymphatic systems, their appearance in tissue fluids and exfoliated surface material would possibly occur under conditions of obstruction by scars or tumors and damage due to inflammation, trauma or stasis. In tumors, the rich blood supply could possibly encourage the concentration of parasite at that site (10). Their presence can also be explained by the fact that larvae may be present in the vasculature and aspiration may lead to the rupture of vessels resulting in hemorrhage and release of microfilariae (7).

Conclusion:

Although microfilariae in cytological material are considered incidental findings, this cases illustrate the value of routine fine needle aspiration cytology in the detection of asymptomatic and clinically unsuspected cases of bancroftian filariasis. Absence of microfilariae in the peripheral blood does not exclude filarial infection. Careful screening of FNAC smears might be helpful in detecting microfilariae, even in asymptomatic patients, especially in highly endemic areas.

References:

1. Varghese R, Raghuvver C, Pai MR, Bansal R. Microfilariae in cytologic smears: A Report of six cases. *Acta Cytol* 1996; 40 (2):299-301.
2. Valand AG, Pandya BS, Patil YV, Patel LG. Subcutaneous filariasis: An unusual case report. *Indian J Dermatol* 2007; 52: 48-9.
3. Jha A, Shrestha R, Ayal G, Pant AD, Adhikari RC, Sayami G. Cytological diagnosis of bancroftian filariasis in lesions clinically anticipated as neoplastic. *Nepal Med Coll J* 2008; 10 (2): 108-114.
4. Pahua R, Arora VM. Microfilaria in cytology smears from upper arm swelling. *J Cytol* 2010; 27(4): 155.
5. Sivakumar S. Role of fine needle aspiration cytology in detection of microfilariae; report of 2 cases. *Acta Cytol* 2007 Sept-Oct; 51(5): 803-6.
6. Walter A, Krisnaswami H, Cariappa A. Microfilariae of *Wucheria bancrofti* in Cytologic smears. *Acta Cytol* 1983 Jul-Aug; 27 (4): 432-6.
7. Gupta S, Sodhani P, Jain S, Kumar N. Microfilariae in association with neoplastic lesions: report of five cases. *Cytopathology* 2001; 12: 120-126.
8. Gutierrez Y. Filariæ of Lymphatics. *Diagnostic Pathology of Parasitic Infections with Clinical Correlation* 1990; 284-285.
9. Agrawal PK, Shrivastava AN, Agrawal N. Microfilaria in association with neoplasms. A report of six cases. *Acta Cytol* 1982; 26: 480-90.
10. Sinha BK, Prabhakar PC, Kumar A, Salhotra M. Microfilaria in a fine needle aspirate of breast carcinoma: An unusual presentation. *J Cytol* 2008; 25:117-8.