



Case Report

Pulmonary hydatidosis presenting as pyopneumothorax in a 15 year old male

Gaurang Aurangabadkar^{1,*}, Saood Ali¹, Ulhas Jadhav¹, Ajay Lanjewar¹

¹Dept. of Respiratory Medicine, Jawaharlal Nehru Medical College, Wardha, Maharashtra, India



ARTICLE INFO

Article history:

Received 10-11-2020

Accepted 06-02-2021

Available online 25-08-2021

Keywords:

Hydatid cyst

Pyopneumothorax

Albendazole

Pleural effusion

ABSTRACT

Pulmonary hydatid cyst is an exceptional cause of pyopneumothorax⁶ that should be considered in countries where hydatid disease is endemic. The documented rates of simple pneumothorax in patients with pulmonary hydatidosis ranges from 2.4-6.2%. Hydatidosis is a parasitic zoonosis of the genus *Echinococcus* that infects herbivores and humans in its larvae stage (hydatid) and in paediatric population, generally presents as pulmonary hydatidosis. Misdiagnosis of this condition as tubercular in origin can cause treatment and prognostic delays for the patient.

We report a case of a 15 year old male presenting with complaints of breathlessness (Grade 2 MMRC) since 3 months and dry cough, low grade fever with chills since 3 months. He had previously received AKT therapy and IV antibiotics. His blood investigations were normal. His sputum for AFB, CBNAAT was negative. His initial chest xray was suggestive of right sided hydropneumothorax. CECT Thorax revealed features suggestive of hydatid cyst in right posterobasal segment lower lobe with loculated pyopneumothorax with collapsed and consolidated right lung with mediastinal lymphadenopathy. After admission, Intercostal chest drainage tube was inserted on the right side and connected to underwater seal and pleural fluid was drained. Pleural fluid investigations revealed exudative effusion by Lights criteria, ADA was 150, culture and sensitivity revealed no growth and cytology revealed features of empyema.

The patient was started on IV Piperacillin+Tazobactam, IV Metronidazole and Tab Albendazole for 14 days along with AKT considering raised pleural fluid ADA levels as suggestive of tubercular pleural effusion. The patients hydatid serology (*Echinococcus* IgG Antibody ELISA- 0.88) came out to be positive which confirmed our diagnosis of hydatidosis. After repeat chest x ray, there was resolution noted in effusion and ICD tube was removed and the patient was discharged on oral antibiotics for 14 days and Tab Albendazole for 3 months.

This is an Open Access (OA) journal, and articles are distributed under the terms of the Creative Commons Attribution-NonCommercial-ShareAlike 4.0 License, which allows others to remix, tweak, and build upon the work non-commercially, as long as appropriate credit is given and the new creations are licensed under the identical terms.

For reprints contact: reprint@ipinnovative.com

1. Introduction

Pulmonary hydatid cyst is a rare cause of pneumothorax with the incidence of simple pneumothorax in the paediatric population as a result of pulmonary hydatidosis is around 2.4 to 6.2% of the patients. Due to the presence of chest xray findings, it has the potential of being misdiagnosed as a case of tubercular pleural effusion or empyema. Pulmonary

hydatid cyst (PHC) may rupture into the pleural cavity or bronchus. In such cases, PHC may be misdiagnosed with other common pulmonary diseases like tuberculosis and thus patients may not be receiving appropriate treatment. For example, misdiagnoses of PHC may even lead to major lung resection or pneumonectomy.

2. Case History

We present a case of a 15 year old male who presented to the Respiratory Medicine OPD in AVBRH, Sawangi, Wardha

* Corresponding author.

E-mail address: gaurangabadkar712@gmail.com (G. Aurangabadkar).

in view of possible surgical intervention and Pulmonologist opinion with chief complaints of fever, breathlessness, right sided chest pain and history of loss of weight and appetite. The initial chest x ray was done which was suggestive of hydropneumothorax and ICD tube insertion was done after which approximately 500ml of yellowish purulent pleural fluid was drained along with air removed. The patient was initially suspected to be suffering from tubercular pleural effusion and was started on AKT from outside. His blood investigations were normal and pleural fluid analysis revealed exudative effusion by Lights criteria, pleural fluid ADA levels were 150 and culture/sensitivity revealed no growth, pleural fluid cytology revealed empyema like nature of effusion with pleural fluid TLC/DLC suggestive of lymphocytic effusion, pleural fluid AFB and CBNAAT were negative for mycobacterium tuberculosis. The patients Sputum for AFB and CBNAAT were also negative. The patient had significant history of contact with dogs and cattle as the family was in the dairy business and hence to investigate further Echinococcus IgG Antibody ELISA was sent which came to be positive (Value- 0.88- Reference values >0.5- Positive) which confirmed the diagnosis of pulmonary hydatidosis.

2.1. General examination

On examination, the patient was afebrile, PR- 110/min, RR- 24/min, BP- 110/60 mm Hg, Spo2- 98% on room air, pallor/icterus/cyanosis and clubbing was absent. There was no palpable lymphadenopathy present.

2.2. On Respiratory examination

On Inspection- Chest wall bilaterally symmetrical, trachea appears central in position, On Palpation- Trachea central in position, no deviation noted, On Percussion- Right sided dull notes heard, On Auscultation- Right sided decreased breath sounds, right sided succussion splash was heard.

2.3. Other systems

Cardiovascular system-Heart sounds normal, no murmurs heard, Gastrointestinal system- P/A soft, non-tender, no hepatosplenomegaly, Central Nervous system- No focal neurological deficit noted, all reflexes normal

2.4. Provisional diagnosis

On the basis of history and clinical examination, a provisional diagnosis of right sided pyopneumothorax was made.

2.5. Routine investigations

The patients routine blood investigations were within normal limits

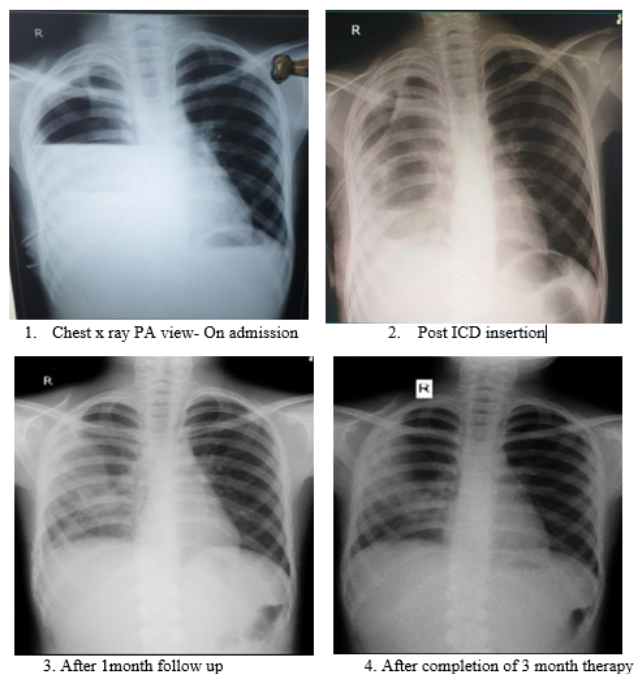


Fig. 1: Follow- up chest x rays showing resolution of pleural effusion and consolidation

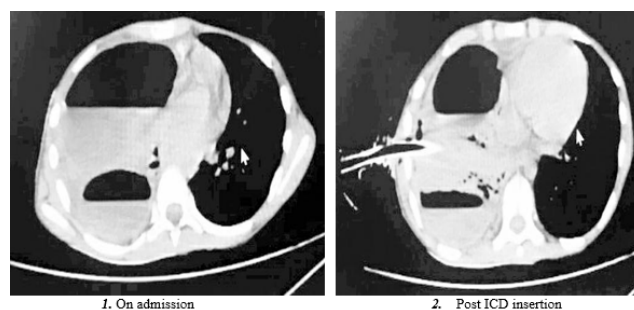


Fig. 2: CECT Thorax suggestive of multiple cavities with air fluid levels

After much diagnostic deliberations, pulmonary hydatidosis was considered as a possible diagnosis and the patients Echinococcus IgG Antibody ELISA was sent which came to be positive (Value- 0.88- Reference values >0.5- Positive) and the patient was started on Tab Albendazole 200mg BD for 3 months. The patient was later discharged after 1 month after removal of ICD tube and was advised to continue anti-echinococcal therapy for 3 months and regular reviews every month in the OPD. His serial chest x rays were done at every OPD visit, which clearly showed resolution of the pleural effusion and consolidation.

3. Discussion

Hydatid cyst is a parasitic infection caused by the larval form of Echinococcus granulosus complex, E. multilocularis

or *E. Vogeli*.¹ Canines are the definitive hosts and humans are the accidental hosts and infection is acquired after consumption of food contaminated with eggs.² *E. granulosus* causes cystic echinococcosis and is the most common species to cause the human disease. Although *E. multilocularis* is rare, it is the most virulent species and causes alveolar echinococcosis. *E. vogeli* and *E. oligarthrus* cause polycystic echinococcosis.²

Hydatid disease involves the lungs by various mechanisms. Humans acquire the infection by ingestion of eggs mixed with uncooked or contaminated food, drinking water or direct contact with animals. Gastric and enteric digestion of eggs facilitates the release of embryos. Embryos subsequently attach to the duodenal or jejunal wall by their hooklets and penetrate the intestinal wall after which they reach the liver via the portal circulation. Most of the embryos are stuck in the liver sinusoids but embryos with diameters less than 0.3 mm may pass through the hepatic sinusoids and through the hepatic vein and IVC, enter the right heart and finally settle in the lungs. Embryos can also enter the thoracic duct via lymphatics of the small intestine and then through the IJV enter the right side of the heart and finally the lungs.^{3–5}

The most common sites of these cysts are the liver and the lungs. Pulmonary cysts can rupture into the mediastinum, bronchial tree or peritoneal cavity and can present with cough, abdominal pain, hemoptysis or chest pain.

Rupture is the most frequent complication of pulmonary hydatid disease occurring in 49% patients.¹ The cyst may rupture intrabronchially or into the pleural cavity.⁶

Surgical intervention is the treatment of choice in selected patients.⁷ Medical therapy for pulmonary hydatid cyst includes benzimidazoles group of drugs (mebendazole, albendazole). Indications for chemotherapy includes smaller cysts and patients with contraindications for surgery. Albendazole is preferred as it has better bioavailability, requires a minimum contact period of 11 days to have a significant response and should be given for a minimum period of 3–6 months. Continuous therapy is more efficacious as it achieves higher drug levels on a sustained basis and do not allow the metacestodes to gradually recover.

4. Conclusion

Hydatid cysts in lung are common in endemic area. In the present report, we described details of ruptured pulmonary hydatid cyst in a boy with fever and breathlessness, as the most prominent symptoms. The disease was misdiagnosed clinically, as pulmonary tuberculosis but hydatid serology

gave us the diagnosis of pulmonary hydatidosis in this case. After definitive diagnosis, the patient was given anti-echinococcal therapy with Tab Albendazole for 3 months. Patient was discharged with good and stable vital signs. This report emphasizes that the ruptured Pulmonary hydatid cyst should be considered in the differential diagnosis of tuberculosis especially in endemic areas for both infections.

5. Conflict of Interest

The authors declare that there are no conflicts of interest in this paper.

6. Source of Funding

None.

References

1. Sebit S, Tunc H, Gorur R, Isitmangil T, Yildizhan A, Us MH, et al. The Evaluation of 13 Patients with Intrathoracic Extrapulmonary Hydatidosis. *J Int Med Res.* 2005;33(2):215–21. doi:10.1177/147323000503300209.
2. Eckert J, Deplazes P. Biological, Epidemiological, and Clinical Aspects of Echinococcosis, a Zoonosis of Increasing Concern. *Clin Microbiol Rev.* 2004;17(1):107–35. doi:10.1128/cmr.17.1.107-135.2004.
3. Sarkar M, Pathania R, Jhobta A, Thakur BR, Chopra R. Cystic pulmonary hydatidosis. *Lung India.* 2016;33(2):179–91. doi:10.4103/0970-2113.177449.
4. Zhang W, Li J, McManus DP. Concepts in Immunology and Diagnosis of Hydatid Disease. *Clin Microbiol Rev.* 2003;16(1):18–36. doi:10.1128/cmr.16.1.18-36.2003.
5. Özkan S, Erer O, Yalçın Y, Yuncu G, Aydoğdu Z. Hydatid cyst presenting as an eosinophilic pleural effusion. *Respirology.* 2007;12(3):462–4. doi:10.1111/j.1440-1843.2007.01054.x.
6. Pfefferkorn U, Viehl CT, Barras JP. Ruptured Hydatid Cyst in the Right Thorax: Differential Diagnosis to Pleural Empyema. *Thorac Cardiovasc Surg.* 2005;53(4):250–1. doi:10.1055/s-2005-837643.
7. Agha RA, Fowler AJ, Saetta A, Barai I, Rajmohan S, Orgill DP, et al. for the SCARE Group The SCARE statement: consensus-based surgical case report guidelines. *Int J Surg.* 2016;34:180–6.

Author biography

Gaurang Aurangabadkar, Junior Resident

Saood Ali, Assistant Professor

Ulhas Jadhav, Professor and HOD

Ajay Lanjewar, Associate Professor

Cite this article: Aurangabadkar G, Ali S, Jadhav U, Lanjewar A. Pulmonary hydatidosis presenting as pyopneumothorax in a 15 year old male. *Panacea J Med Sci* 2021;11(2):357-359.