



Ventricular dyssynchrony as a cause of structural disease in the heart of Dorper sheep

J. KER¹, E.C. WEBB² and C.F. VAN DER MERWE³

ABSTRACT

KER, J., WEBB, E.C. & VAN DER MERWE, C.F. 2004. Ventricular dyssynchrony as a cause of structural disease in the heart of Dorper sheep. *Onderstepoort Journal of Veterinary Research*, 71: 197–202

Ventricular dyssynchrony is a disturbance of the normal, organized electromechanical coupling of the two ventricles. This condition has many causes, such as left bundle branch block, ventricular pre-excitation, right ventricular pacing and right ventricular premature ventricular complexes (PVCs). Ventricular dyssynchrony has many adverse haemodynamic effects on the left ventricle and we wanted to know whether these adverse haemodynamic effects might have any structural consequences on the left ventricles of such hearts.

Six healthy Dorper wethers were subjected to numerous right ventricular PVCs to induce ventricular dyssynchrony in order to determine whether any structural consequences will occur in the left ventricles of these hearts. Myocarditis in the musculature of the left ventricles of all six these hearts was seen.

Keywords: Dorper sheep, premature ventricular complexes, ventricular dyssynchrony

INTRODUCTION

In 1925 Wiggers observed that, if ventricular activation proceeds from the ventricular epicardium instead of from the atrium, the consequence will be a lower peak left ventricular pressure as well as a lower dP/dt. He also concluded that the normal sequence of ventricular activation is essential for optimum ventricular function (Varna & Camm 2001).

In the mammalian heart, cardiac activation is initiated in the atria and proceeds to the ventricles via the specialized conduction system (SCS). This SCS consists of the His bundle, the left and right bundle branches with their major fascicles and the peripheral Purkinje network (Van Dam 1989). The terminal ramifications of this Purkinje network merge into the ventricular myocardium at sites of Purkinje-myocardial coupling. Proximal to these sites the SCS has no functional connections with the myocardium because of a thin, collagenous sheath (Van Dam 1989).

Ventricular dyssynchrony can be defined as an abnormality of the normal, organized electromechanical coupling of the ventricles and this disturbance is the consequence of an interventricular conduction delay (Aranda & Schofield 2002). Ventricular dyssynchrony is not an uncommon clinical problem and has numerous causes, such as left bundle branch

¹ Department of Physiology, Faculty of Medicine, University of Pretoria, P.O. Box 24318, Gezina, Pretoria, 0031 South Africa. E-mail: james.ker@med.up.ac.za

² Department of Animal and Wildlife Sciences, Faculty of Natural and Agricultural Sciences, University of Pretoria, Pretoria, 0002 South Africa

³ Department of Microscopy and Microanalysis, University of Pretoria, Pretoria, 0002 South Africa

block (Littmann & Symanski 2000), right ventricular pacing (Badke & Boinay 1980; Grover & Glantz 1983; DiCarlo & Morady 1987; Rosenqvist & Isaaq 1991), ventricular pre-excitation (Sutherland & Kukulski 2000) and premature ventricular complexes (Sutherland & Kukulski 2000).

During periods of ventricular dyssynchrony, right ventricular activation begins and is completed before the initiation of left ventricular activation (Dunn 1987). Right ventricular depolarization is then followed by a reversed activation sequence of the interventricular septum, proceeding from right to left, which is then followed by a parallel, rather than radial, spread of depolarization towards the left ventricular free wall (Dunn 1987). This delayed activation of the left ventricle, more specifically the lateral wall of the left ventricle, has several important haemodynamic consequences (Aranda & Schofield 2002):

- There is delayed contraction of the posteromedial papillary muscle, which leads to systolic mitral regurgitation.
- The delayed activation of the left ventricle leads to a delay in the onset of early diastolic ventricular filling, but atrial activation proceeds normally. The result is that early, passive diastolic filling of the left ventricle and atrial contraction occur simultaneously. This has been demonstrated by the merging of the E and A waves on mitral Doppler inflow patterns in these hearts.
- Atrial activation during the early, passive diastolic filling phase of the left ventricle decreases the total transmitral flow which results in a diminished preload of the left ventricle.
- The delayed activation of the posteromedial papillary muscle also leads to diastolic mitral regurgitation.
- The interventricular septum is a crucial structure for the maintenance of interventricular dependence. However, with delayed activation of the left ventricular lateral wall, left ventricular systolic pressure will be increased well after depolarization of the interventricular septum is completed. The consequence is septal dyskinesis, with the septum moving away from the left ventricular wall during left ventricular contraction. The result is a decreased septal contribution to left ventricular stroke volume.

Ventricular dyssynchrony is a common clinical problem and has been shown to occur in approxi-

mately 30 % of humans with chronic heart failure, both of ischaemic and idiopathic origin (Barold 2001; Abraham & Fisher 2002).

The objective of this investigation was to determine if ventricular dyssynchrony *per se* can cause structural heart disease, instead of it always being considered a *consequence* of such structural disease of the heart.

MATERIALS AND METHODS

Six clinically normal Dorper wethers, all between the ages of 9 and 12 months and weighing between 35 and 40 kg, were used in this study. They were fed lucerne hay *ad libitum*, received 300 g per day of pelleted concentrate (10 MJ ME/kg DM with 14 % crude protein) and had free access to water at all times.

Right ventricular premature ventricular complexes (PVCs) were used to induce ventricular dyssynchrony. Right ventricular PVCs were induced in each wether as previously described by Ker & Webb (2003): A spring-wire guide, diameter 0.81 mm and length 600 mm, was advanced into the right ventricle via the left internal jugular vein, using the Seldinger technique. The position of the wire was confirmed in every case by an X-ray. Right ventricular PVCs were induced by mechanical movement of the spring-wire guide inside the right ventricle.

These right ventricular PVCs were induced on a daily basis in every wether for variable periods. Thus PVCs were induced in sheep 1 for 15 days, in sheep 2 for 36 days, in sheep 3 for 28 days, in sheep 4 for 16 days, in sheep 5 for 53 days and in sheep 6 for 34 days.

On completion of each series of PVCs, each wether was subsequently slaughtered and their hearts subjected to histological examination. Only the musculature of the left ventricles were examined histologically as the right ventricles were subjected to mechanical trauma by the spring-wire guides used to induce the right ventricular PVCs and therefore some histological changes in the musculature of the right ventricles are to be expected. However, because the left ventricle is isolated from the right by the interventricular septum the wire will have no direct histological effects on the left ventricle.

Left ventricular dissection

- The musculature of each left ventricle (LV) was dissected into three regions: Two transverse in-

cisions were made, one at the level of the base and the other at the level of the apex of the posteromedial papillary muscle. This divides the LV into three regions: base, mid-region and apex.

- Each of these three regions were then dissected into four parts: anterior, posterior, septal and lateral.
- In this way every LV was dissected into 12 pieces, representing the musculature of the entire LV, which were subsequently all subjected to histological examination.
- These 12 segments were numbered as follows:
 - A = Anterior part of base
 - B = Anterior part of mid region
 - C = Anterior part of apex
 - D = Septal part of base
 - E = Septal part of mid region
 - F = Septal part of apex
 - G = Lateral part of base
 - H = Lateral part of mid region
 - I = Lateral part of apex
 - J = Posterior part of base
 - K = Posterior part of mid region
 - L = Posterior part of apex

Histological evaluation

Tissue blocks from the 12 sites were fixed in 10 % buffered formalin and paraffin-embedded sections for light microscopy were prepared using routine histological procedures. They were stained with hematoxylin and eosin (HE). All the sections were evaluated for the following:

1. Myocardial cellular abnormalities and/or
2. Myocardial interstitial abnormalities.

Histologic categories

On the basis of the morphological findings each of the 12 specimens was assigned to one of four categories:

1. Normal
2. Myocardial cellular abnormalities
3. Myocardial interstitial abnormalities
4. Both myocardial cellular and interstitial abnormalities.

The heart of a normal Dorper wether, of similar age and mass, served as a histological control (see Fig. 1).

RESULTS

No sheep in this study showed any signs of infection as a result of the spring-wire guide during the entire study period. The induction of PVCs was possible throughout the study period in all the animals.

Histologic abnormalities

As compared to the histological control (Fig. 1) we observed histological changes in all six of the experimental animals. These changes consisted of both myocardial cellular and interstitial abnormalities in the musculature of the left ventricle (Table 1). According to the Dallas criteria (Hare & Baughman 1994; Kühl, Noutsias, Seeberg & Schultheiss 1996; Pisani, Taylor & Mason 1997; Feldman & McNamara 2000) these observed myocardial cellular and interstitial changes are indicative of myocarditis.

Relation between the PVC load and number of abnormal left ventricular segments

We found no relation between the PVC load, as well as the number of days subjected to PVCs, and the number of abnormal left ventricular segments (Table 2).

Location of left ventricular histologic abnormalities

The location of these histologic abnormalities in the left ventricles of the experimental animals was evenly distributed between the anterior, posterior, septal and lateral wall (Table 3).




FIG. 1 Longitudinal section through the musculature of the left ventricle of a normal Dorper wether heart

TABLE 1 Histologic outcomes

Sheep	Histologic abnormalities in left ventricle
1	Myocardial interstitial abnormalities* in segments C, D, E, F, G, H, I, J, K
2	Myocardial interstitial abnormalities in segments B, C, D, E, I, J, K, L Myocardial cellular abnormalities** in segments B, E, K Fibrosis in segments B, K
3	Myocardial interstitial abnormalities in segments A, B, D, G, K Myocardial cellular abnormalities in segments A, D, G
4	Myocardial cellular abnormalities in segments A, C
5	Myocardial interstitial abnormalities in segments A, B, D, E, H, I, K Myocardial cellular abnormalities in segment A Fibrosis in segments D, F, I
6	Myocardial interstitial abnormalities in segments D, I

* Myocardial interstitial abnormalities consist of an infiltration of white blood cells (> 5 WBCs/high power field)

** Myocardial cellular abnormalities consist of myocytolysis

TABLE 2 Days subjected to PVCs, PVC load and number of abnormal left ventricular segments

Days subjected to PVCs	PVC load*	Number of abnormal left ventricular segments
53	902	8
36	575	8
34	908	2
28	371	5
16	1 887	2
15	221	9

* The spring-wire guides were left *in situ* in the right ventricles and electrocardiography was done once daily. Therefore, the number of actual PVCs may be much higher than the number of PVCs counted

TABLE 3 Location of left ventricular histologic abnormalities

Location of abnormal left ventricular segments	Number of abnormal left ventricular segments (total of 6)
Anterior	5
Posterior	4
Septal	5
Lateral	5

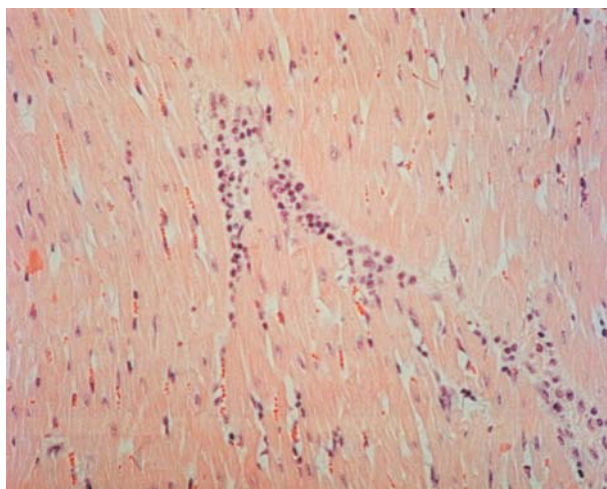


FIG. 2 Infiltration of the left ventricular interstitium by a mixed inflammatory cell infiltrate, a feature of myocarditis

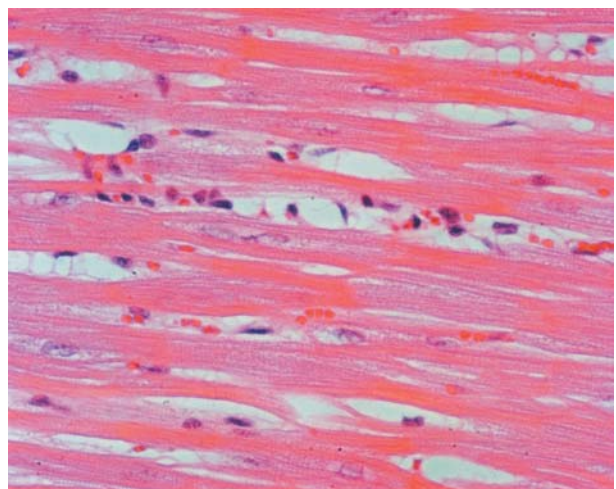


FIG. 3 Myocytolysis in the left ventricle, another feature of myocarditis

DISCUSSION

Any alteration in the normal sequence of left ventricular activation, thereby leading to interventricular dyssynchrony, has several important consequences. These include haemodynamic, myocardial and metabolic disturbances (Aranda & Schofield 2002; Van Oosterhout, Prinzen, Arts, Schreuder, Vanagt, Cleutjens & Reneman 1998; Zanco, Desideri, Mobililia, Carguel, Milan, Celegon, Buchberger & Ferlin 2000).

Firstly, haemodynamic consequences are mainly due to delayed activation of the lateral wall of the left ventricle. These include systolic and diastolic mitral regurgitation, a diminished preload of the left ventricle and septal dyskinesis causing a decreased septal contribution to left ventricular stroke volume (Aranda & Schofield 2002).

Secondly, myocardial consequences have been described (Van Oosterhout, Prinzen, Arts, Schreuder, Vanagt, Cleutjens & Reneman 1998). Asynchronous activation of the left ventricle induces asymmetrical left ventricular hypertrophy. When there is a period of asynchronous activation of the left ventricle, as induced by right ventricular pacing or PVCs, this causes regional differences in the workload of the left ventricle. The workload is lower in early than in late-activated regions and as a result the early-activated regions become thinner and the late-activated regions become thicker.

Thirdly, metabolic consequences have been described as well (Zanco, Desideri, Mobililia, Cargnel, Milan, Celegon, Buchberger & Ferlin 2000). There is a reduction of septal glucose uptake and metabolism in the left ventricle during periods of ventricular dyssynchrony.

According to the Dallas criteria (Hare & Baughman 1994; Kühl, Noutsias, Seeberg & Schultheiss 1996; Pisani, Taylor & Mason 1997; Feldman & McNamara 2000) all six of the experimental animals developed myocarditis. Myocarditis has many causes (Feldman & McNamara 2000). Some of these include infectious agents, physical agents, drugs, heavy metals, systemic diseases and various miscellaneous causes, such as snake- and spider bites (Feldman & McNamara 2000).

Furthermore, myocarditis consists of various histopathologic subclasses and these include a lymphocytic, eosinophilic, neutrophilic, giant cell and a granulomatous type (Pisani, Taylor & Mason 1997).

Might it be possible that there is also an immunological consequence of ventricular dyssynchrony,

that presents with myocardial inflammation, as seen in our study? A search of the Medline database from 1966 to the present revealed only two studies where myocarditis occurred in situations of ventricular dyssynchrony.

Basso, Corrado, Rossi & Thiene (2001) examined the hearts of eight human patients who died from Wolff-Parkinson-White (WPW) syndrome and found isolated atrial myocarditis in four (50 %) of these hearts. This syndrome is a condition in which strands of atrial-like muscle form atrioventricular bypass tracts which activate the right ventricle causing right ventricular activation to precede left ventricular activation. It is therefore a cause of ventricular dyssynchrony. The syndrome is a congenital disorder and therefore its relationship to myocarditis is either coincidental or possibly causal.

Because PVCs do not constitute a congenital disorder, but rather a complication of various cardiac and non-cardiac disorders, its possible relation to myocarditis is more complex. Biase, Chiddo, Caruso, Tritto, Marchese & Rizzon (1992) examined ventricular endomyocardial biopsies from 26 human patients with PVCs and found acute myocarditis in 7 % and borderline myocarditis in 3.5 %. However, it is not possible to determine from this data whether PVCs are a consequence or a cause of myocarditis.

We found in this study that the induction of right ventricular PVCs consistently led to the development of myocarditis of the left ventricle in all of the experimental animals. An interesting finding is that there was no relation between the PVC load and the number of abnormal left ventricular segments (see Table 2). As stated before, the spring-wire guides were left *in situ* in the right ventricles and electrocardiography was done once daily. It is therefore possible that the actual number of PVCs may be higher in sheep with less days exposed to PVCs. Alternatively, it is possible that the critical time period for the development of myocarditis is 2 weeks or less and/or that the critical number of PVCs needed to induce myocarditis is 221 or less. Another interesting finding is the distribution of myocardial inflammation (Table 2). The histological manifestations of myocarditis are evenly distributed among the anterior, posterior, septal and lateral walls of the left ventricle of all the experimental animals.

In conclusion, myocarditis was detected in the left ventricles in all of the experimental animals. In this study this was a diffuse process, which involved all

four walls of the left ventricle. We conclude that right ventricular PVCs, a cause of ventricular dyssynchrony, may be a cause of myocarditis in the Dorper wether and that PVCs are not always a complication of myocarditis but that there is a possible causal relationship. Therefore, we propose a fourth consequence of ventricular dyssynchrony, an alteration of the immune system, leading to myocarditis.

REFERENCES

- ABRAHAM, W.T. & FISHER, W.G. 2002. Cardiac resynchronization in chronic heart failure. *New England Journal of Medicine*, 346:1845–1853.
- ARANDA, J.M. & SCHOFIELD, R.S. 2002. Ventricular dyssynchrony in dilated cardiomyopathy: the role of biventricular pacing in the treatment of congestive heart failure. *Clinical Cardiology*, 25:357–362.
- BADKE, F.R. & BOINAY, P. 1980. Effects of ventricular pacing on regional left ventricular performance in the dog. *American Journal of Physiology*, 238:H858–867.
- BAROLD, S.S. 2001. What is cardiac resynchronization therapy? *American Journal of Medicine*, 111:224–232.
- BASSO, C., CORRADO, D., ROSSI, L. & THIENE, G. 2001. Ventricular pre-excitation in children and young adults. Atrial myocarditis as a possible trigger of sudden death. *Circulation*, 103:269–275.
- BIASE, M.D., CHIDDO, A., CARUSO, G., TRITTO, M., MARCHESE, A. & RIZZON, P. 1992. Ventricular premature beats in young subjects without evidence of cardiac disease: histological findings. *European Heart Journal*, 13:732–737.
- DICARLO, L.A. & MORADY, F. 1987. The haemodynamic effects of ventricular pacing with and without atrioventricular synchrony in patients with normal and diminished left ventricular function. *American Heart Journal*, 114:746–752.
- DUNN, M. 1987. Left bundle branch block: variations on a theme. *Journal of the American College of Cardiology*, 10: 81.
- FELDMAN, A.M. & MCNAMARA, D. 2000. Myocarditis. *New England Journal of Medicine*, 343:1388–1398.
- GROVER, M. & GLANTZ, S.A. 1983. Endocardial pacing site affects left ventricular end-diastolic volume and performance in the intact anesthetized dog. *Circulation Research*, 53:72–85.
- HARE, J.M. & BAUGHMAN, K.L. 1994. Myocarditis: current understanding of the etiology, pathophysiology, natural history and management of inflammatory diseases of the myocardium. *Cardiology in Review*, 2:165–173.
- KÜHL, U., NOUTSIAS, M., SEEBERG, B. & SCHULTHEISS, H.P. 1996. Immunohistological evidence for a chronic intramyocardial inflammatory process in dilated cardiomyopathy. *Heart*, 75:295–300.
- LITTMANN, L. & SYMANSKI, J.D. 2000. Haemodynamic implications of left bundle branch block. *Journal of Electrocardiology*, 33(suppl):115–121.
- PISANI, B., TAYLOR, D.O. & MASON, J.W. 1997. Inflammatory myocardial diseases and cardiomyopathies. *American Journal of Medicine*, 102:459–469.
- ROSENQVIST, M. & ISAAZ, K. 1991. Relative importance of activation sequence compared to atrioventricular synchrony in left ventricular function. *American Journal of Cardiology*, 67:148–156.
- SUTHERLAND, G.R. & KUKULSKI, T. 2000. Quantitation of left ventricular asynergy by cardiac ultrasound. *American Journal of Cardiology*, 86:4–9.
- VAN DAM, R.T. 1989. Activation of the heart, in *Comprehensive electrocardiology, theory and practice in health and disease*, edited by P.W MacFarlane. New York: Pergamon Press.
- VAN OOSTERHOUT, M.F.M., PRINZEN, F.W., ARTS, T., SCHREUDER, J.J., VANAGT, W.Y.R., CLEUTJENS, J.P.M. & RENEMAN, R.S. 1998. Asynchronous electrical activation induces asymmetrical hypertrophy of the left ventricular wall. *Circulation*, 98:588–595.
- VARMA, C. & CAMM, A.J. 2001. Pacing for heart failure. *Lancet*, 357:1277–1283.
- ZANCO, P., DESIDERI, A., MOBILIA, G., CARGNEL, S., MILAN, E., CELEGON, L., BUCHBERGER, R. & FERLIN, G. 2000. Effects of left bundle branch block on myocardial FDG PET in patients without significant coronary artery stenoses. *Journal of Nuclear Medicine*, 41:973–977.