

Diagnostic Value of Gynecologic Ultrasonography as A Malignancy Predictor in Children's Ovarian Tumor

Ni Made Putri Suastari^{1*}, Pande Putu Yuli Anandasari¹, Putu Patriawan¹, Ni Nyoman Margiani¹, Firman Parulian Sitanggang¹, I Gde Raka Widiana²

¹Departement of Radiology, Faculty of Medicine, Universitas Udayana, Kampus Bukit, Jl. Raya Kampus Unud Jimbaran, South Kuta, Badung, Bali, Indonesia

²Departement of Internal Medicine, Faculty of Medicine, Universitas Udayana, Kampus Bukit, Jl. Raya Kampus Unud Jimbaran, South Kuta, Badung, Bali, Indonesia

DATE OF ARTICLE:

Received: 01 April 2022

Reviewed: 20 June 2022

Revised: 21 June 2022

Accepted: 29 June 2022

***CORRESPONDENCE:**

putrisuastari@yahoo.co.id

DOI:

10.18196/mmjkk.v22i2.14389

TYPE OF ARTICLE:

Research

Abstract: The incidence of ovarian malignancy is rare in children, with proportions between 16-55%. A gynecologic ultrasonography score is expected to increase accuracy and be able to diagnose malignancy earlier. By using a retrospective cross-sectional study design, this study is a diagnostic test to assess ultrasonography examination as a predictor of malignancy with histopathological examination as the gold standard. The study subjects were 45 children admitted from July 2017 to December 2020. Characteristics of the subjects were obtained from medical records, gynecologic ultrasonography images were accessed from PACS, and histopathological results were obtained from SIMARS. The gynecologic ultrasonography images were scored by two observers using a scoring table. Variables assessed consisted of inner wall structure, wall thickness, septa, morphology, tumor vascularization and ascites. The data will then be analyzed, determining the optimal cut-off score, sensitivity, specificity, accuracy, and positive and negative predictive value. AUC value of 0.92 using a cut-off ≥ 14 obtained 15 malignant subjects and 1 benign subject and resulted in a sensitivity of 78.9%, specificity of 96.2%, a positive predictive value of 93.8%, a negative predictive value of 86.2%, and accuracy of 88.89%. It can be concluded that the diagnostic value of gynecologic ultrasonography examination as a predictor of malignant ovarian tumors in children was remarkable.

Keywords: children; gynecologic ultrasonography score; malignant ovarian tumor; malignancy predictor

INTRODUCTION

Ovarian malignancy is the world's third most common gynecologic malignancy after cervical cancer and uterine corpus.¹ This tumor can affect women of all ages, including children, although the incidence is rare. Worldwide, the incidence of ovarian tumors in children is about 2.6 cases per 100,000 girls per year, of which 50% are malignant masses.² The proportion of malignant ovarian tumors in children varies between 16-55% in different series. To this date, the exact cause of ovarian cancer is still unknown, especially in children.³

Most ovarian cancer patients seeking medical care are at an advanced stage and are referred to as the silent killer. This delay in diagnosis will certainly cause various problems; hence it is important to detect malignant ovarian tumors as early as possible.⁴

Thus far, histopathological examination results are still used as the gold standard for detecting malignancy of ovarian tumors. This examination is an invasive procedure involving examining intact tissue taken by biopsy or surgery. The examination uses a standard technique, paraffin cutting or frozen section, which has long been used and accepted and has high accuracy for clinical use, including gynecological disorders.⁵

One of the most appropriate preoperative diagnostic imaging modalities in children is ultrasonography. This examination is a non-invasive technique with high accuracy, relatively low cost, easy to

find, real-time, mobile device, without radiation exposure and can be useful as a guide for action. However, in most cases, the extreme variation in the macroscopic characteristics of ovarian tumors sometimes makes it quite difficult to make a precise diagnosis from ultrasonography images and is highly operator-dependent. To overcome this limitation, it is recommended to use a scoring system based on ultrasonography images with values according to defined features and cut-off scores to categorize tumors as benign or malignant. In adult patients, many studies have been carried out on ultrasonography examination and scoring in determining the grade of malignant ovarian tumors.^{6 4}

However, to date, similar data in children are still limited, and no scoring system has been developed through ultrasonography images. This study aims to seek the diagnostic value of gynecologic ultrasonography examination as a predictor of malignancy in pediatric ovarian tumors at Sanglah Hospital Denpasar. With the ability to diagnose malignancy earlier, the referral process to more specialized fields is expected to be faster and have higher accuracy for optimal treatment to reduce morbidity and mortality rates and increase child life expectancy.

MATERIAL AND METHOD

This research is a diagnostic test study to assess ultrasonography examination as a predictor of malignancy in pediatric ovarian tumors and histopathological examination as the gold standard, using a retrospective cross-sectional study design. The research subjects were 45 children gathered by consecutive sampling techniques and were sent to the Radiology Installation of Sanglah Hospital Denpasar to undergo a gynecologic ultrasonography examination from July 2017 to December 2020.

Subject characteristics data were obtained from medical records in the form of child's age, age of menarche (categorized <12 years, 12 years, not menarche yet), nutritional status (categorized as undernourished, normal, overweight, obese), and family history of malignancy (categorized as yes or no). The gynecologic ultrasonography images were scored by two observers using a scoring table. Each component of the scoring table indicates whether it is present or not, then given a value (yes = 1 and none = 0) multiplied by score weight based on references from several studies and literature to get a score and then add up each component so that a total score is obtained. Variables assessed consisted of inner wall structure, wall thickness, septa, morphology, tumor vascularization and ascites. The findings of gynecologic ultrasonography examination and the weight of each score were as follows: The score of the structure of the inner wall of the tumor: regular or smooth (1), irregular with a thickness of ≤ 3 mm (2), papillary with a thickness of >3 mm (3) and could not be assessed because the tumor is almost entirely solid; Tumor wall thickness score: thin ≤ 3 mm (2), >3 mm thick (3), and cannot be assessed because the tumor is almost completely solid (4); Tumor septa score: no septa (1), thin septa ≤ 3 mm (2), and thick septa >3 mm (3); tumor morphology scores: unilocular cyst (1), unilocular solid (2), multilocular cyst (1), multilocular solid (2), and solid (3); Tumor vascularity score: no vascularity (1), at the periphery of the mass (1), and mass internal vascularity (4); Ascites score: no ascites (1) and with ascites (3). The results of the histopathological examination were categorized into malignant and benign. The data were then analyzed, namely the interobserver agreement with Bland-Altman, ROC analysis, determining the optimal cut-off of the score as well as sensitivity, specificity, positive predictive value, negative predictive value and accuracy.

Interobserver agreement with Bland-Altman can be used to assess consistency and conformity in the visual assessment of quantitative data at two rates. Afterward, a Receiver Operating Characteristic (ROC) analysis was performed to assess a diagnostic test's ability to detect the disease using the ROC curve. Assessment of the ability of a test was carried out using the Area Under Curve (AUC). The AUC covers the entire area under the curve formed from all the sensitivity and 1-specificity coordinates. The AUC value ranges from 0-1; the wider the AUC is, the better the ability of a test to detect disease will be. The good ability of a test will be reached if the $AUC \geq 0.7$. In addition, ROC analysis was also used to determine the cut point to determine the value of sensitivity, specificity, positive predictive value, negative predictive value and accuracy.

RESULT

45 pediatric patients with suspected malignant ovarian tumors were found during the study period. In subjects with malignant PA results, the dominant age of menarche was under 12 years old (57.9%), good nutritional status (79%) and no history of malignancy in the family (100%) with radiological findings including inner wall structure of the tumor was papillary with thickness >3 mm (52.6%), tumor wall thickness >3 mm (73.6%), septa thickness >3 mm (68.4%), solid tumor morphology (26.2%), internal vascular mass (73.6%) and ascites (84.2%). Characteristics of research subjects and radiological features based on gynecologic ultrasonography scores can be seen in Table 1.

Interobserver reliability test was obtained from the results of gynecologic ultrasonography scores as a predictor of malignancy by two radiologists. With the Pearson correlation, an identical positive correlation value of 0.99 ($p = <0.001$) was obtained. Using the Bland-Altman plot, the mean of observer A was 11.51 ($SD \pm 5.08$), the mean of observer B was 11.51 ($SD \pm 5.07$), and the mean difference was: 0.00 ($SD \pm 0.3$); 95% CI: -0.59 - 0.59. In Pitman's test, $r = 0.04$ and $p = 0.77$ (> 0.05). The distribution of the interobserver plots can be seen in Figure 1, showing a good match between observers A and B.

Table 1. Characteristics of Research Subjects and Radiological Features Based on Gynecologic Ultrasonography Scores with Malignant (N=19) and Benign (N=26) PA result

Characteristics	Malignant PA Result N (%)	Benign PA Result N (%)
Age of menarche		
<12 y.o	11 (57,9%)	17 (65,4%)
≥12 y.o	6 (31,6%)	5 (19,2%)
Not menarche yet	2 (10,5%)	4 (15,3%)
Nutritional status		
Undernourished	1 (5,3%)	1 (3,9%)
Normal	15 (79%)	25 (96,1%)
Overweight	3 (15,8%)	0 (0%)
Obese	0 (0%)	0 (0%)
History of malignancy in family		
Yes	0 (0%)	2 (7,7%)
None	19 (100%)	24 (92,3%)
Radiological Findings		
Inner Wall Structure		
Regular or smooth	0 (0%)	9 (34,6%)
Irregular with thickness ≤3 mm	4 (21%)	11 (42,3%)
Papillary with thickness >3 mm	10 (52,6%)	6 (23,1)
It cannot be assessed because the tumor is almost completely solid	5 (26,4%)	0 (0%)
Tumor Wall Thickness		
Thin (≤3 mm)	0 (0%)	2 (7,7%)
Thick (>3 mm)	14 (73,6%)	24 (92,3%)
It cannot be assessed because the tumor is almost completely solid	5 (26,4%)	0 (0%)
Tumor Septa		
No septa	5 (21%)	5 (19,2%)
Thin Septa (≤3 mm)	2 (10,5%)	14 (53,8%)
Thick Septa (>3 mm)	13 (68,4%)	7 (27%)
Tumor Morphology		
Unilocular cyst	4 (21,1%)	12 (46,2%)
Unilocular solid	3 (15,8%)	1 (3,8%)
Multilocular cyst	4 (21,1%)	12 (46,2%)
Multilocular solid	3 (15,8%)	1 (3,8%)
Tumor solid	5 (26,2%)	0 (0%)
Tumor Vascularization		
No vascularization	4 (21,1%)	13 (50%)
At the periphery of the mass	1 (5,3%)	10 (38,5%)
Mass internal vascularization	14 (73,6%)	3 (11,5%)
Ascites		
No ascites	3 (15,8%)	21 (80,8%)
With ascites	16 (84,2%)	5 (19,2%)

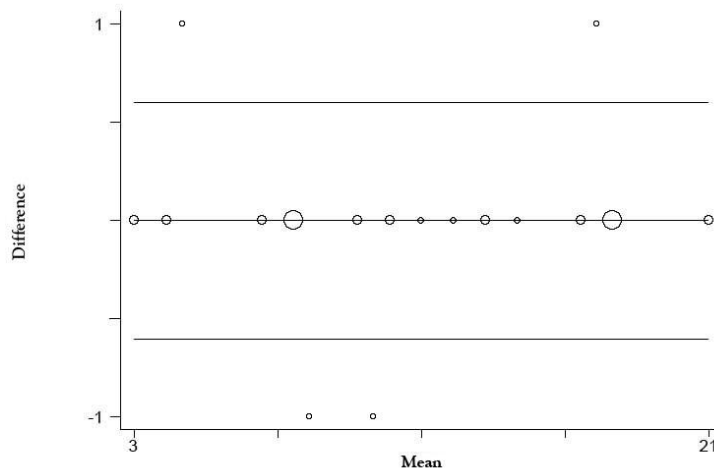


Figure 1. Graph of difference and mean of observations between observers A and B (Interobserver agreement Bland-Altman)

Based on the analysis using the ROC curve, it was found that the area under the curve (AUC) was wide, which was 0.92 (Figure 2). Furthermore, there is a report on each cut-off value's sensitivity and specificity, which can be seen in table 2. The optimal cut-off value is 14.

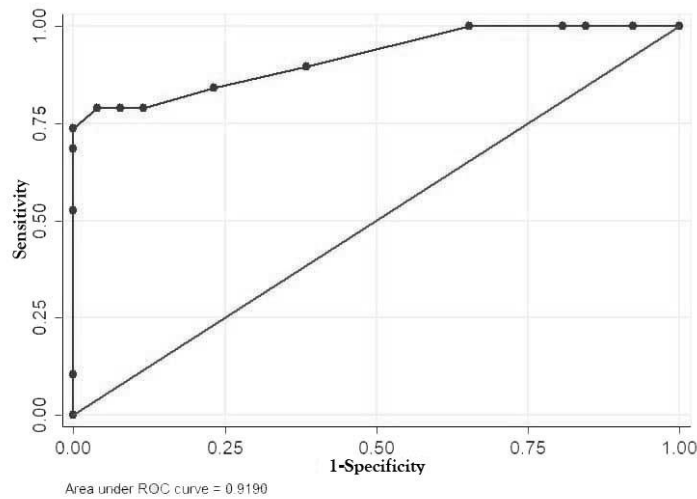


Figure 2. ROC Curve of Gynecologic Ultrasonography Score as a Predictor of Malignant Ovarian Tumor in Children (AUC: 0.92; SE: 0.04; CI 95% AUC: 0.83-1.00).

Table 2. Sensitivity dan Specificity Value, NPP, NPN, LR+, LR- and Accuracy on Each Cut-Off for Gynecologic Ultrasonography Score

Cut Off	Sensitivity	Specificity	NPP	NPN	LR+	LR-	Accuracy
≥ 3	100.00%	0.00%	42.22%	0	1.00		42.22%
≥ 4	100.00%	7.69%	44.19%	100%	1.08	0	46.67%
≥ 5	100.00%	15.38%	46.34%	100%	1.18	0	51.11%
≥ 7	100.00%	19.23%	47.5%	100%	1.23	0	53.33%
≥ 8	100.00%	34.62%	52.78%	100%	1.52	0	62.22%
≥ 10	89.47%	61.54%	60.71%	88.23%	2.32	0.17	73.33%
≥ 11	84.21%	76.92%	66.67%	85.71%	3.64	0.20	80%
≥ 12	78.95%	88.46%	83.33%	85.12%	6.84	0.23	84.44%
≥ 13	78.95%	92.31%	88.23%	85.71%	10.26	0.22	86.67%
≥ 14	78.95%	96.15%	93.8%	86.2%	20,52	0.21	88.89%
≥ 15	73.68%	100.00%	100%	83.87%		0.26	88.89%
≥ 17	68.42%	100.00%	100%	81.25%		0.31	86.67%
≥ 18	52.63%	100.00%	100%	74.29%		0.47	80%
≥ 21	10.53%	100.00%	100%	60%		0.89	62.22%

By using a cut-off ≥ 14 , the number of patients with radiologically malignant ovarian tumors was 16, and 29 patients were benign. The validity test performed on the gynecologic ultrasonography score as a predictor of ovarian tumor malignancy in children showed a sensitivity of 78.9% (95% CI 54.4-93.9%), specificity of 96.2% (95%CI 80.4-99.9%), the positive predictive value of 93.8% (95%CI 69.8-99.8%), the negative predictive value of 86.2% (95%CI 68.3-96.1%), and accuracy of 88.89% (Table 3).

Table 3. Validity Analysis Result of Gynecologic Ultrasonography Score Using Optimal Cut Off as a Predictor of Malignant Ovarian Tumor in Children

Variable	PA Result		Sensitivity (95%CI)	Specificity (95%CI)	NPP (95%CI)	NPN (95%CI)	LR+	LR-	Accuracy
	Malignant	Benign							
Score									
≥ 14	15	1	78.9% (54.4- 93.9%)	96.2% (80.4- 99.9%)	93.8% (69.8- 99.8%)	86.2% (68.3- 96.1%)	20.52	0.21	88.89%
< 14	4	25							

DISCUSSION

Decision-making of the diagnosis of malignancy of ovarian tumors in children is still a challenge. A study stated that there was no difference in age between patients with benign ovarian tumors (16.3 ± 2.1 years) and malignant ovarian tumors (15.7 ± 2.5 years).⁷ In the group with malignant PA results, the majority of the age of menarche was at the age < 12 years old, which is in line with the theory stating that earlier age of menarche can increase the risk of ovarian malignancy associated with the duration of exposure to the estrogen hormone.⁶ Patients with good nutritional status dominated this study. It is supported by the study stating that there was no relationship or negative relationship between obesity and the risk of ovarian malignancy.⁷ In the results of this study, it was found that only 4.4% of subjects had a family history of malignancy. Recent epidemiological studies have shown an interaction between genetic, environmental, and lifestyle factors that might significantly influence the pattern and trend of the incidence and mortality of ovarian tumor malignancies in children.² In this study, the number of malignant histopathological results was less than benign. Malignant ovarian tumors originating from germ cells were rare in children, with the proportion of malignancies only being 3-5%.⁸⁻¹¹

The study findings supported the notion that the subjects with PA results of malignant ovarian tumors, the radiological findings based on gynecologic ultrasonography scores included: papillary inner wall structure with thickness > 3 mm, tumor wall thickness > 3 mm, septa thickness > 3 mm, morphology solid tumor, internal vascular mass and ascites. Ovarian tumors, including malignant lesions, are large lesions with a maximum diameter of 10 cm or larger, with or without solid components; solid lesions with irregular edges; solid components with papillary projections ≥ 3 mm originating from the cyst wall or septation; papillary projections ≥ 4 , septal thickness > 3 mm, color Doppler with the flow in a solid component, presence of ascites, peritoneal mass or enlarged lymph nodes which are high-risk findings of malignancy.¹²⁻¹⁴ In another study, risks were grouped based on high-risk sonographic features, including masses with internal blood flow using the color Doppler (76.5%), thick walls, thick septa, solid components or irregular or nodular areas in it (61.8%).¹⁵⁻¹⁸

Based on the interobserver reliability test results between observers A and B, the mean difference in the results of gynecologic ultrasonography screening was 0.00 (SD \pm 0.3) with 95% CI: -0.59 – 0.59, the r value was 0, 05 and a p-value of 0.77. This analysis found evidence for good conformity and high consistency between observers A and B in interpreting gynecologic ultrasonography images; an account of the interpretation was carried out by two radiology specialists who worked at the same institution, namely at the tertiary level, which was a tertiary hospital where referral of patients with difficult and complex cases.

The ROC curve showed an AUC value of 0.92, classified as very good. It indicated that the accuracy of gynecologic ultrasonography scores as a predictor of malignant ovarian tumor in children was very good. The closer the AUC value to 1 is, the better the performance of the diagnostic test will be.

In this study, the optimal cut-off value of gynecologic ultrasonography scores as a predictor of ovarian tumor malignancy in children was 14 with a sensitivity of 78.9%, specificity of 96.2%, a positive predictive value of 93.8%, a negative predictive value of 86.2%, LR (+) 20.52, LR (-) 0.21 and accuracy of 88.89%. High specificity and good sensitivity resulted in high positive and negative predictive values. In a scoring system using ultrasonography examination in children aged < 19 years old, a DePriest score < 7 (based on the components of lesion volume, cyst wall, and septal structure) had a sensitivity of 88% and a specificity of 95%. while an

Ueland index score <7 (based on the component of lesion volume and tumor morphology) had a sensitivity of 90% and a specificity of 92%, suggesting a benign lesion.¹⁹⁻²¹

The pretest probability in this study found that the prevalence of malignant ovarian tumors in children was 42%. After using the ultrasonography score, the ability to diagnose malignant ovarian tumor (posttest probability) increased to 93.8%. Based on this result, it was found that the diagnosis rate of malignant ovarian tumors in children increased after using an ultrasonography score with a difference of 50%.

This research has several limitations. First, as it is carried out at a tertiary level hospital center which is the highest referral center, it is indicative that this study cannot describe the diagnostic function of ultrasound examinations in other health care units. Second, this research is a retrospective study, indicating that the data and results of gynecological ultrasound examinations taken from existing medical record data may not describe all the predictors needed to evaluate the presence of malignancy in ovarian tumors. Suggestions from this research are as follows; first, this gynecological ultrasound score can be used accurately as a predictor of malignancy of ovarian tumors in children, and second, with a cut-off value of 14, this gynecological ultrasound score can be used to confirm the diagnosis of malignancy of ovarian tumors in children.

CONCLUSION

Gynecologic ultrasonography score included inner wall structure, tumor wall thickness, tumor vascularization and ascites with the best cut-off value at ≥ 14 , which resulted in a very good diagnostic ability as a predictor of malignant ovarian tumor in children.

CONFLICT OF INTEREST

The authors declare that there is no conflict of interest regarding the publication of this paper.

REFERENCES

1. Ferlay J, Soerjomataram I, Ervik M, Dikshit R, Eser S, Mathers C, et al. Cancer Incidence and Mortality Worldwide: IARC Cancer Base [Internet]. 2018. [cited 2020 September 4]. Available from: <http://globocan.iarc.fr>
2. Mahadik K. Childhood Ovarian Malignancy. The Journal of Obstetrics and Gynecology of India. 2014;64(2):91-94. <https://doi.org/0.1007/s13224-014-0533-4>
3. Taskinen S, Fagerholm R, Lohi J, Taskinen M. Pediatric Ovarian Neoplastic Tumors: Incidence, Age at Presentation, Tumor Markers and Outcome. 2015; 94:425-429. <https://doi.org/10.1111/aogs.12598>
4. Rasjidi I, Muljadi R, Cahyono K. Imaging Ginekologi Onkologi. 2012. Jakarta: Sagung Seto.
5. Zhang Z, Zohre M, Azita T, Safoura T, Hamid S. Ovarian Cancer in The World: Epidemiology and Risk Factors. International Journal of Women's Health. 2014; 11:287-299. <http://doi.org/10.2147/IJWH.S197604>
6. Geomini P, Kruitwagen R, Bremer GL, Cnossen J. The Accuracy of Risk Scores in Predicting Ovarian Malignancy: A Systematic Review. Obstet Gynecol. 2015; 113: 384-94. <http://doi.org/10.1097/AOG.0b013e318195ad17>
7. Hatzipantelis ES, Dinas K. Ovarian Tumors in Childhood and Adolescence. European Journal of Gynaecological Oncology. 2017; 31(6):616-620.
8. Ameye L, Valentin L, Testa AC, Van Holsbeke C, Domali E, Van Huffel S, et al. A Scoring System to Differentiate Malignant from Benign Masses in Specific Ultrasonography-Based Subgroups of Adnexal Tumors. Ultrasonography Obstet Gynecol. 2012; 33(1): 92-101. <http://doi.org/10.1002/uog.6273>
9. Daniilidis A, Karagiannis V. Epithelial Ovarian Cancer, Risk factors, Screening and The Role of Prophylactic Oophorectomy. Hippokratia. 2012;11(2):63-66
10. Potdar N, Rekha N, Christina A. Management of Ovarian Cysts in Children and Adolescents. Royal College of Obstetricians and Gynaecologists. 2019; 22: 107-114. <https://doi.org/10.1111/tog.12648>
11. Renaud EJ, Islam S, Danielle, Cameron, Robert LG, Regan FW. Ovarian Masses in The Child and Adolescent: An American Pediatric Surgical Association Outcomes and Evidence-Based Practice Committee Systematic Review. Journal Pediatric Surgery; 2018: 1-9. <http://doi.org/10.1016/j.jpedsurg.2018.08.058>
12. Timmerman D, Testa AC, Bourne T, Ameye L, Jurkovic D, Van Holsbeke C, et al. Simple Ultrasonography based Rules for The Diagnosis of Ovarian Cancer. Ultrasonography Obstet Gynecol. 2008; 31: 681-90. <http://doi.org/10.1002/uog.5365>
13. Twickler DM, Moschos E. Ultrasound and Assessment of Ovarian Cancer Risk. American Roentgen Ray Society. 2012;194:322-329. <http://doi.org/10.2214/AJR.09.356>

14. Depoers C, Martin FA, Timoh KN, Morcet J, Proisy M, Henno S, et al. A Preoperative Scoring System for Adnexal Mass in Children and Adolescents to Preserve Their Future Fertility. *American Society for Pediatric and Adolescent Gynecology*. 2019;32:57-63. <https://doi.org/10.1016/j.jpap.2018.08.009>
15. Stankovic ZB, Bjelica A, Djukic MK, Savic D. Value of Ultrasonographic Detection of Normal Ovarian Tissue in the Differential Diagnosis of Adnexal Masses in Pediatric Patients. *Ultrasound Obstet Gynecol* 2012; 36: 88–92. <https://doi.org/10.1002/uog.7557>
16. Jung SI. Ultrasonography of Ovarian Masses Using A Pattern Recognition Approach. *Korean Society of Ultrasound in Medicine*. 2015;34(3):173-182. <https://doi.org/10.14366/usg.15003>
17. Justyna LJ, Baglaj M. Selecting Treatment Method for Ovarian Masses in Children – 24 Years of Experience. *Journal of Ovarian Research*. 2017,1-9. <https://doi.org/10.1186/s13048-017-0353-0>
18. Heo SH, Kim JW, Shin SS, Jeong SI, Lim HS, Choi YD, et al. Review of Ovarian Tumors in Children and Adolescents: Radiologic- Pathologic Correlation. *RadioGraphics*. 2014; 34:2039–2055. <https://doi.org/10.1148/rg.347130144>
19. Ertas S, Vural F, Tufekci EC, Ertas AC, Kose G, Aka N. Predictive Value of Malignancy Risk Indices for Ovarian Masses in Premenopausal and Postmenopausal Women. *Asian Pacific Journal of Cancer Prevention*. 2016;17(4):2177-2183. <http://doi.org/10.7314/APJCP.2016.17.4.2177>
20. Zhou L, Xuan Z, Wang Y. Diagnostic Value of Ultrasound Score, Color Doppler Ultrasound RI and Spiral CT for Ovarian Tumors. *Oncology Letters*. 2019;17:5499-5504. <http://doi.org/10.3892/ol.2019.10215>
21. Asavoai C, Fufezan O, Cosarca M. Ovarian and uterine ultrasonography in pediatric patients. Pictorial essay. *Med Ultrason*. 2014;16(2):160-167. <http://doi.org/10.11152/mu.2013.2066.162.ca1of2>