

## Case Report

## Integrated orofacial therapy in chronic rhinosinusitis management for children with sleep bruxism

Haryono Utomo

Dental Clinic

Faculty of Dentistry, Airlangga University  
Surabaya – Indonesia

### ABSTRACT

**Background:** The prevalence of rhinosinusitis was 20% in ambulatory patients and was mostly affected by viral infections and allergy. If conservative treatments of rhinosinusitis failed, surgical procedure is an alternative choice. Previous case report revealed that the rhinosinusitis symptoms were successfully relieved by the "assisted drainage" therapy only. Nevertheless, this therapy was less successful in children with sleep bruxism (SB). **Purpose:** To report an integrated orofacial therapy for management of rhinosinusitis children with sleep bruxism (SB) which consisted of the assisted drainage, night-guard and masseter muscle massage therapies. **Case:** Two boys who suffered from rhinosinusitis with bruxism were unsuccessfully treated with conventional treatment. **Case management:** Patients was subjected to the assisted drainage therapy that was scaling and root planning combined with gingival massage, and masseter muscle massage; night guard was worn in night sleep. They successfully relieved the rhinosinusitis symptoms. **Conclusion:** Based on the successful result, this integrated therapy could be suggested as an adjuvant in rhinosinusitis management.

**Key words:** assisted drainage, night guard, rhinosinusitis, children, bruxism

### ABSTRAK

**Latar belakang:** Prevalensi rinosinusitis adalah 20% pasien rawat jalan dan umumnya disebabkan oleh infeksi virus dan alergi. Apabila terapi konservatif rinosinusitis mengalami kegagalan maka pilihan terakhir adalah operasi. Pada laporan kasus yang ada telah terjadi perbaikan gejala rinosinusitis setelah dilakukan terapi "assisted drainage" saja. Akan tetapi, terapi ini kurang berhasil pada anak dengan sleep bruxism (SB). **Tujuan:** Melaporkan suatu terapi orofasial terintegrasi untuk tatalaksana rinosinusitis pada anak dengan sleep bruxism (SB) yang terdiri dari terapi assisted drainage, night guard dan masase otot masseter. **Kasus:** Dua anak laki-laki yang menderita rinosinusitis dengan bruxism telah mengalami kegagalan pada perawatan konvensional. **Tatalaksana kasus:** Pasien dilakukan terapi assisted drainage yang adalah scaling dan root planning yang dikombinasikan dengan masase gingiva dan masase otot masseter; sedangkan nightguard dipakai saat tidur malam. Terapi ini berhasil mengurangi gejala rinosinusitis. **Kesimpulan:** Berdasarkan keberhasilan terapi, terapi terintegrasi ini dapat digunakan sebagai ajuvan dalam tatalaksana sinusitis.

**Kata kunci:** Assisted drainage, night guard, rinosinusitis, anak, bruksism

**Correspondence:** Haryono Utomo, c/o: Rumah Sakit Gigi dan Mulut, Fakultas Kedokteran Gigi Universitas Airlangga. Jl. Mayjend. Prof. Dr. Moestopo No. 47 Surabaya 60132, Indonesia. E-mail: dhoetomo@indo.net.id

### INTRODUCTION

The term of rhinosinusitis was proposed by the American Academy of Otolaryngology–Head and Neck Surgery in 1996, to substitute the term of sinusitis. This term was considered to describe the pathologic process more accurately than sinusitis only. The prevalence of

rhinosinusitis was 20% in ambulatory patients which was mostly affected by viral infections and allergic reactions, and self recovered without the use of antibiotics.<sup>1</sup> However, contradictory, to the USA there were 13 million antibiotics were prescribed for rhinosinusitis.<sup>2</sup>

Conservative treatments of rhinosinusitis are decongestants, corticosteroids, antibiotics and diathermy.

If it failed, surgical procedures such as adenoidectomy had to be done.<sup>3</sup> It was also believed that rhinosinusitis also has relationship to dental infection, mostly dental caries.<sup>4</sup> Moreover, some case reports which related to children revealed the possibility of chronic gingivitis as an etiology of rhinosinusitis symptoms via the "neurogenic switching" mechanism.<sup>5,6</sup>

According to several studies the possible involvement of stressful conditions either to rhinosinusitis and allergic patients<sup>7</sup> or to sleep bruxism (SB)<sup>8,9</sup> had been studied and revealed its positive correlations. However, the mechanism of SB as a trigger of rhinosinusitis symptoms is not clearly understood. Sleep bruxism and clenching are related with parafunctional muscle activities of masticatory muscles during sleeping, particularly the pterygoid muscles (grinding) and temporalis muscles (clenching).<sup>8</sup> The "night guard" or occlusal splint therapy is a treatment of choice for SB, and considered more effective than cognitive-behavioral treatment. Nevertheless, the effectiveness of night-guard therapy in children is still questionable due to the possibility of their poor compliance.<sup>8,9</sup>

The possible correlation of rhinosinusitis with chronic gingivitis had been proven by dental plaque control therapy and the "assisted drainage" therapy (ADT).<sup>5,6</sup> This intra-oral approach had been effectively reduced both rhinosinusitis and chronic gingivitis symptoms. Nevertheless, they had less satisfactory result in children with SB such as in this case report.

The objective of this case report was to reported an integrated therapy for management of rhinosinusitis children with SB which consisted of the assisted drainage, night-guard and masseter muscle massage therapies.

## CASE

Case #1 A nine years old boy, suffering from rhinosinusitis symptoms for years; however, the worst symptoms were started one year before. He was diagnosed to have bilateral maxillary rhinosinusitis by an otolaryngologist confirmed with Water's projection radiograph. He was brought to our private dental clinic because his brother who also suffered from rhinitis and epistaxis had recovered from the similar symptoms after dental plaque control therapy in our clinic.

His main complaints were nasal congestion, hearing impairment, sleep disturbance, fatigue, forgetfulness, difficult to concentrate and headache. Almost every month he was suffered from febris (39-40° C). Treatments which had been done by the otolaryngologist, was mostly antibiotics and nasal decongestants. Sometimes it was also accompanied by diathermy. The result was not satisfactory; he still suffered from rhinosinusitis symptoms almost every month.

Extraorally, the patient appeared fatigue, and there was a small amount of thin nasal discharge in the nostrils. Intra-oral examination showed moderate dental plaque in

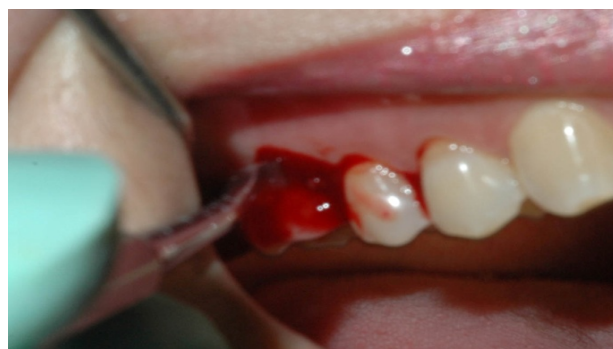every region, and abundant dental plaque was seen in the upper posterior regions. Inflamed gingiva was also seen in several regions, especially the #16 #55 and #65 #26, on which pseudopockets and subgingival pockets were detected. The patient had neither caries nor filling.

## CASE MANAGEMENT

At the first visit, it was noticed that the patient speak loudly and in high pitch voice. Her mother said that other than rhinosinusitis symptoms he had a kind of hearing impairment so everybody had to speak louder to communicate with him. The first thing to be done was explaining the connection between dental plaque and rhinosinusitis to motivate the parents and patient to follow the Dental Health Education (DHE) for home maintenance.

In order to evaluate and convince either the patient or his parent for the effective result of the treatment, before treatment a specific test that was proposed termed as the "paper blowing test" was performed. The test was done by blowing a piece of paper or tissue (approximately 3x7 cm) with one nostril. Other nostril and mouth had to be closed tightly. In a congested nose, patient had to blow with hard effort to move the tissue paper.

Treatment was initiated with prophylactic procedure using rotating brush, pumice and contra-angled-low speed-handpiece. The pseudopockets and interdental spaces were irrigated with hexetidine 0.1%; after one minute the assisted drainage therapy (ADT) was done. The ADT was a procedure developed for removing subgingival plaque within the pseudopockets of the chronic gingivitis area which concomitantly drained the inflammatory mediators using a sickle shaped sealer. The sealer was moved slowly forward and backward with gentle pressure until bleeding comes (Figure 1). The patient was told to raise his left hand if pain felt. Interestingly, the ADT which performed in chronic gingivitis does not elicit pain. In this case, coincident with other chronic gingivitis cases, the dark red blood oozed from the interdental spaces and pseudopockets, especially in the upper left and right posterior teeth.

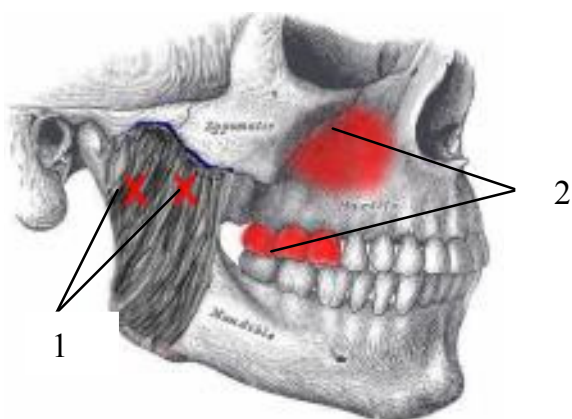


**Figure 1.** The "assisted drainage" therapy.

After the ADT was done bilaterally, approximately three minutes later, the patient was conducting the paper blowing test once more. At that time he could move the paper by blowing with one nostril with almost no effort and also did with his another nostril. The parent said that before the dental procedures, despite many medications and diathermy, the patients could not breathe easily through the nose. Afterwards, the patient and his parent were taught for Dental Health Education and prescribed hexetidine 0.1% mouthwash. He was scheduled for the next visit in a week time.

On the second visit the patient looked more cheerful. The parent said that all the symptoms related to rhinosinusitis (i.e. nasal congestion, headache) had already disappeared. Interestingly, that on the second visit the patient did not speak loudly, he also speak in a considered normal voice pitch. Intra-orally, oral hygiene was good, the chronic gingivitis symptoms also disappeared and so did the pseudopockets. Patient was instructed to maintain oral hygiene and visit the dental practitioner every month for evaluation.

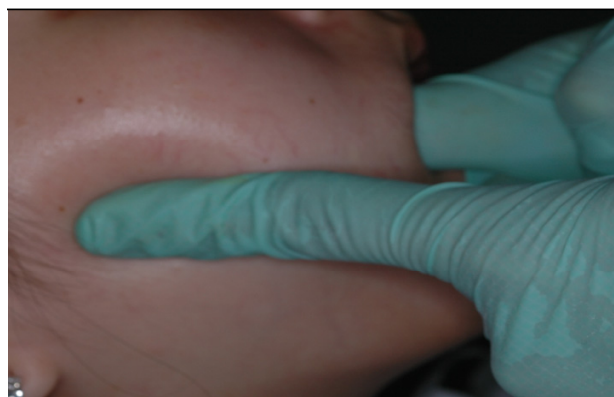A month later it was found that the ADT had poorer result than previous visit because the rhinosinusitis symptoms recurrent, including headache. After taking comprehensive medical and dental history, especially for the persistent headache symptom, it was revealed that according his mother the patient always grinds his teeth every night. This condition was confirmed by palpating the affected masticator muscles (the pterygoid and temporal muscles), which had spasm and also painful by tender pressure (trigger point). Since the pterygoid muscles were difficult to palpate, Okeson<sup>20</sup> suggested palpating its referral pain region (trigger points) in the outer and inner masseter muscles (Figure 2a).



**Figure 2a.** Masseter muscle trigger points (1) and the referred area (2).<sup>17</sup>

In order to reduce muscle spasm caused by sleep bruxism (SB), maxillary impression had been taken for the night-guard fabrication. It was made from silicon sheet and should be worn every night when sleeping, it should be worn for several hours at daytime for adaptation. His parent was also taught to massage the trigger points on

the outer and inner "cheek" masticatory muscle (laymen's term of the masseter muscles) regularly (2–3 times/day) for five minutes for helping reduce the muscle spasm (Figure 2b).



**Figure 2b.** Masseter muscle massage.

The next visit, one week later, the rhinosinusitis symptoms were completely disappeared which was confirmed by the otolaryngologist who treated him earlier. At that time, spasm and trigger points in the masseter muscles were disappeared, so did the SB one month later. Evaluations were done two monthly, the last evaluation was in April 2008, about one year after the first visit. During that time, severe rhinosinusitis symptoms were not recurrent, only mild rhinitis occurred when he was very tired. He also grew as an healthy, active, bright and easy to concentrate children.

**Case #2** An eight years old boy was diagnosed suffered from maxillary rhinosinusitis by an otolaryngologist, and the symptoms had been suffered for more than 3 years. The chief complaints were runny nose, nasal congestion and headache. He was brought by her mother to our private dental clinic after got informed that there was a connection between rhinosinusitis and oral hygiene. He had been treated by several otolaryngologists and pediatricians either in Indonesia or an abroad. The most prescribed medications were mostly antibiotics, antihistamines and nasal decongestants. Sometimes he also sent to have diathermy therapy by a physiotherapist, but severe symptoms still recurrent if the medications were stopped.

Before visiting the dental practitioner, the previous otolaryngologist suggested to do surgery (adenoidectomy) to reduce the rhinosinusitis symptoms. Nevertheless, the parent refused and still look for another opinions. During that time he had to consume antibiotics and other rhinosinusitis medications.

At a glance, the boy looked unhealthy, skinny, irritable, hyperactive and uncooperative. He always scratch his nose and face, it seems that he feel his nose itching all the time (the "allergic salute" symptoms). Extra oral inspection showed that his eyes were watery and also had blackened and swollen lower eyelids, which were common symptoms in rhinosinusitis.

Intraorally, he had a moderate dental plaque accumulation and chronic gingivitis. Inflamed gingiva was also seen in several regions, especially the #16, #55, and #65, #26, on which pseudopockets were detected. The patient had neither caries nor filling. At masticatory muscles palpation, muscle spasm and trigger points were detected.

### CASE MANAGEMENT

At the first visit, after detected the bruxism habit based on the muscle examination, and confirmed by his mother; he received to the regular protocol for the "sleep bruxism-related rhinosinusitis" (a proposed term) management similar to case #1 that was the integrated orofacial therapy. Coincident with case #1, even though the management was more difficult because of his uncooperative behavior, approximately three minutes after ADT, the patients could breathe easily through his nostrils. Night-guard therapy was also recommended for this patient, and his mother also told to massage the masseter muscles everyday. The patient was scheduled for evaluation in one week time.

At second visit, extra oral examination showed that his eyes and lower eyelids became normal. Runny nose and nasal congestion also disappeared, but the headache still persisted a little bit. He also became more cooperative and did not scratch his face and nose. At this occasion, he was instructed to begin wearing the night-guard.

One month later, SB disappeared, so did the headache. Cross-examination of this successful integrated orofacial therapy, for rhinosinusitis management was conducted by an otolaryngologist. Evaluation was done two monthly, the latest evaluation was in May 2008, approximately seven months after the first visit; severe rhinosinusitis symptoms did not reappear, only sneezing in the morning when the weather was cold.

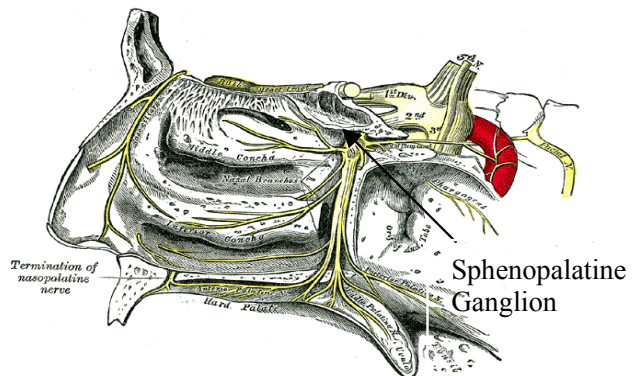
### DISCUSSION

Rhinosinusitis may affect everyone due to infancy, since the maxillary sinuses have already developed in the third month of fetal life, followed by the ethmoid sinuses.<sup>1</sup> As rhinosinusitis mostly accompanied by headache, especially migraine headache, or vice versa, diagnosis of the main etiology could be difficult.<sup>10</sup> Consequently, it will become more difficult if happen to infants or young children.

Several mechanisms were also proposed related to the interrelationship between rhinosinusitis, migraine headache and allergy that are: 1) autonomic symptoms caused by parasympathetic cranial activation, and 2) neurogenic and immunogenic interaction or "neurogenic switching" mechanism which were confirmed by Bellamy *et al.*<sup>11</sup> Nevertheless, recent publications also included stress as a contributing factor in allergic rhinosinusitis due to its ability to stimulate nasal autonomic symptoms.<sup>7,11</sup> Therefore, the interrelationship between stress, allergy, rhinosinusitis and migraine headache is possible.

Nasal congestion is the most common symptom in rhinosinusitis, which related to turbinate dysfunction. The autonomic nervous system provides the general innervation to the nose, with the parasympathetic nerves supplying the resting tone and controlling secretions. The parasympathetic ganglion within the nasal region is the sphenopalatine ganglion (SPG) (Figure 3).<sup>13</sup> According to the neurogenic switching mechanism, the trigger of parasympathetic stimulation could be initiated from chronic gingivitis.<sup>14</sup> This phenomenon was confirmed by a study in allergic Wistar rats which stimulated with intragingival injection of *Porphyromonas gingivalis* lipopolysaccharide.<sup>15</sup>

Instant resolution of rhinosinusitis symptoms after removal of the subgingival plaque and drainage of inflammatory mediators was suspected due to rapid decrease of the neurogenic switching mechanism, which also confirmed by ADT in allergic Wistar rats that was done by Utomo in 2009.<sup>15</sup> However, in this case report, the ADT alone was insufficient for completely eliminate rhinosinusitis symptoms. The idea to find the etiology of the persistent headache was to correlate it with masticatory muscle spasm. It was in accordance with Janal *et al.*<sup>16</sup> that SB caused masticatory muscle spasm which triggers headache. In this case, masseter muscles massage was considered advantageous to reduce muscle spasm.<sup>17</sup>



**Figure 3.** Maxillary nerve-Sphenopalatine ganglion connection.<sup>19</sup>

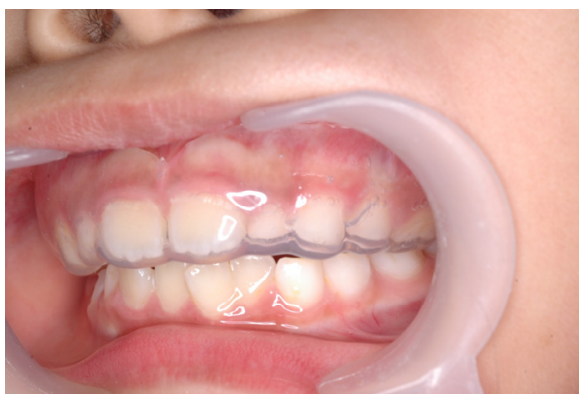It was suggested by Boyd<sup>13</sup> that SB was able to stimulate autonomic symptoms via the otic ganglion, a parasympathetic ganglion that related with mandibular nerve. It was sensitized by the parafunctional activity of the masticatory muscles which were innervated by the mandibular nerve. This suggestion was agreed by Green<sup>18</sup> who also proposed that parasympathetic activation may lead to autonomic symptoms such as rhinosinusitis. Thus, chronic gingivitis and SB are proposed to have the propensity to sensitize the parasympathetic ganglions, either to the SPG or the otic which facilitate the recurrence of the rhinosinusitis symptoms.<sup>19</sup>

Although dental practitioners are considered to be incompetent in diagnosing rhinosinusitis symptoms; however, patient's information about the past medical history which had been done by otolaryngologist was considered



valid. Nevertheless, it is uneasy to improve parents' and children's trust to dental practitioner competency in treating rhinosinusitis. Therefore, a simple but effective treatment evaluation method should be created, such as the "paper blowing test".

Ideally, it was suggested that the treatment of SB using night guard or occlusal splint should follow rules regarding to the type of SB i.e. severe grinder or mild grinder.<sup>13</sup> In addition, according to Okeson<sup>20</sup> the ideal occlusal splint or night guard for SB should be fabricated from hard clear acrylic. However, relevant to Widmalm,<sup>21</sup> soft night guards were preferred by some patients because their cushioning effect. Therefore, considering that children are: a) possibly careless i.e. unintentionally break the hard night guard; b) have poorer motivation and compliance; c) not easily adapted to pressure to the teeth which more pronounced in hard night guard; and d) still have erupting permanent teeth and short primary teeth that which could not easily adapted by hard night guard and lack of retentive area. Thus, soft night guard is preferred to be used by children. Moreover, for increasing retention in short teeth, soft night guard flange could be extended to the vestibule, which mimicking full denture with minimal discomfort (Figure 4).



**Figure 4.** Soft night guard for children with short teeth (extended buccal flange).

Rhinosinusitis in this case report is proposed as "sleep bruxism-related rhinosinusitis" which related to stressful condition. Since recent stressful environment (i.e. intense school assignments, extracurricular activities and lack of leisure time) which may affect children also increasing; thus, it is possible that the prevalence could be increasing. Moreover, because SB is more pronounced in children than decreased relevant with age;<sup>8</sup> hence, health professional who treat children, either medical or dental should be aware of this phenomenon.

It concluded that regarding to the successful treatment procedures in this case report, the integrated orofacial therapy in rhinosinusitis management which consisted of the combination of the ADT, night guard and masseter muscle massage therapies is considered effective. Nevertheless, for further improvement and perfection of this

method, conducting collaborate researches between dental and medical practitioners are mandatory. This teamwork is also beneficial for avoiding unnecessary prolonged medications or therapy, especially surgery which were considered harmful to the patient.

## REFERENCES

1. Kentjono WA. Rhinosinusitis: etiology and pathophysiology. *Ear, Nose and Throat Continuing Education IV*. 2004. p. 1–3.
2. Behrman RE, Kliegman RM, Jenson HB. *Nelson textbook of pediatrics*. 17<sup>th</sup> ed. Philadelphia: Saunders; 2004. p. 760, 1832.
3. Felisati G, Ramadan H. Rhinosinusitis in children: the role of surgery. *Pediatr Allergy Immunol* 2007; 18(Suppl. 18): 68–70
4. Mylonakis E, Bajracharya H. Chronic sinusitis. Available online at URL: <http://www.emedicine.com/med/topic2556.htm>. Accessed May 10, 2008.
5. Utomo H. The sphenopalatine ganglion sensitization by periodontal inflammation: a possible etiology for headache and sinusitis in children. *Majalah Kedokteran Gigi FKG Universitas Airlangga*. 2006; 39(2): 66–71.
6. Utomo H, Pradopo S. Practical dental approach in children's rhinosinusitis management. *J Dentistry* 2006; 13(3): 133–6.
7. Mçşges R, Klimek L. Today\_s allergic rhinitis patients are different: new factors that may play a role. *Allergy* 2007; 62: 969–75.
8. Lavigne GJ, Kato T, Kolta A, Sessle BJ. Neurobiological mechanisms involved in sleep bruxism. *Crit Rev Oral Biol Med* 2003; 14(1): 30–46.
9. Ommerborn MA, Schneider C, Giraki M, Schäfer R, Handschel J, Franz M, Raab WH. Effects of an occlusal splint compared to cognitive-behavioral treatment on sleep bruxism activity. *Eur J Oral Sci* 2007; 115: 7–14.
10. Cady RK, Schreiber CP. Sinus headache or migraine. *Neurology* 2002; 58: S10–4.
11. Bellamy JL, Cady RK, Durham PL. Salivary levels of CGRP and VIP in rhinosinusitis and migraine patients. *Headache* 2006; 46: 24–33.
12. Bousquet J, Khaltaev N, Cruz AA, Denburg J, Fokkens WJ. Allergic rhinitis and its impact on asthma (ARIA) 2008: review article. *Allergy* 63 2008; (Suppl. 86): 8–160.
13. Boyd J. Pathophysiology of migraine and rationale for a targeted approach and prevention. Available online at URL <http://www.migraine-prevention.com/index/html>. Accessed February 15, 2006.
14. Lundy W, Linden R. Neuropeptides and neurogenic mechanism in oral and periodontal inflammation. *Crit Rev Oral Biol*. 2004; 15(2): 82–98.
15. Utomo H. Immunoneuromodulatory mechanism of the assisted drainage therapy in allergic rats induced by *Porphyromonas gingivalis* lipopolysaccharide. Dissertation. Postgraduate Program Airlangga University. 2009. p. 111–5.
16. Janal MN, Raphael KG, Klausner J, Teaford M. The role of tooth-grinding in the maintenance of myofascial face pain: a test of alternate models. *Am Ac Pain Med* 2007; 8(6): 486–96.
17. Alexander D. Masseter muscle, massage therapy, TMJ, tooth pain, sinus pain. Available online at URL <http://www.massagetherapypractice.com/Text/1166848766515-0626/pC/1164930096301-0119/Anatomy-&-Technique.htm>. Accessed May 10, 2008.
18. Green MW. Diagnosing and treating migraine: low tech diagnosis, high tech treatment. Available online at URL <http://www.ama-assn.org/ama1/pub/upload/mm/31/24pres-green.pdf>. Accessed February 20, 2006.
19. Gray's Anatomy of the human body. The trigeminal nerve. Available online at URL: <http://education.yahoo.com/reference/gray>. Accessed February 10, 2006.
20. Okeson JP. *Bell's orofacial pain*. 6<sup>th</sup> ed. Carol Stream: Quintessence Pub. 2005. p. 52–3.
21. Widmalm SE. Bite splints in general dental practice. Available online at URL <http://sitemaker.umich.edu/widmalm/files/bsconstruc.pdf>. Accessed May 5, 2008.