

## Case Report

## Ankylosis of the temporomandibular joint and mandibular growth disturbance caused by neglected condylar fracture in childhood

Endrajana

Department of Oral and Maxillofacial Surgery  
Faculty of Dentistry, Airlangga University  
Surabaya - Indonesia

### ABSTRACT

**Background:** Fractures of the mandibular condyle may lead to complications such as disturbance of occlusal function, internal derangement of the joint, ankylosis and mandibular growth disturbance. When treating young patients with the history of mandible trauma, ankylosis of the temporomandibular joint and mandibular growth disturbance are two most important complications of condyle fracture that should be considered. **Purpose:** This case report attempts to emphasize the long term complication of neglected condylar fracture in children i.e. ankylosis of the temporomandibular joint and subsequently lead to mandibular growth disturbance. **Case:** A case of right temporo-mandibular joint ankylosis and mandibular growth disturbance in a 28 years old male patient is presented. He had a history of trauma to the mandible after a traffic accident when he was 8 years old. Since then, he experienced difficulty in mouth opening which eventually developed into severe trismus. **Case management:** The case was treated surgically with gap and interpositional arthroplasty using Mersilen mesh™. **Conclusion:** Mandibular fractures involving temporomandibular joint in young children should be examined thoroughly and treated adequately in order to prevent ankylosis of the TMJ and the subsequent mandibular growth disturbance.

**Key words:** Condylar fracture, ankylosis, mandibular growth disturbance

### ABSTRAK

**Latar belakang:** Fraktur pada kondilus mandibula dapat menyebabkan beberapa komplikasi berupa: gangguan oklusi, internal derangement sendi, ankilosis serta gangguan pertumbuhan mandibula. Pada perawatan penderita usia muda dengan riwayat trauma pada mandibula, perlu diwaspadai dua macam komplikasi akibat fraktur pada kondilus, yaitu ankilosis sendi temporo mandibula dan adanya gangguan pertumbuhan mandibula. **Tujuan:** Laporan kasus ini bertujuan untuk menekankan bahwa fraktur kondilus pada anak-anak yang tidak mendapatkan perawatan yang semestinya akan mengakibatkan komplikasi jangka panjang berupa ankilosis sendi temporomandibula yang diikuti dengan gangguan pertumbuhan tulang mandibula. **Kasus:** Penderita laki-laki umur 28 tahun dengan keadaan tidak dapat membuka mulut dan adanya gangguan pertumbuhan tulang mandibula. Terdapat riwayat trauma pada mandibula akibat kecelakaan lalu lintas saat penderita berumur 8 tahun. Semenjak kecelakaan tersebut penderita merasakan kesulitan membuka mulut dan akhirnya sama sekali tidak dapat membuka mulut. **Tatalaksana kasus:** Untuk merawat kasus ini dilakukan tindakan pembedahan dengan bius umum yaitu gap arthroplasty dengan memakai Mersilen mesh™ sebagai interposisional graft. **Kesimpulan:** Fraktur kondilus mandibula pada penderita anak-anak memerlukan pemeriksaan dan perawatan yang adekuat untuk menghindari terjadinya ankilosis sendi temporomandibula dan gangguan pertumbuhan tulang mandibula.

**Kata kunci:** Fraktur kondilus, ankilosis sendi temporomandibula, gangguan pertumbuhan tulang mandibula

**Correspondence:** Endrajana, c/o: Departemen Bedah Mulut, Fakultas Kedokteran Gigi Universitas Airlangga. Jl. Mayjend. Prof. Dr. Moestopo No. 47 Surabaya 60132, Indonesia. E-mail: bm\_enjana@yahoo.co.id

## INTRODUCTION

The mandible is different from other facial bones in some important respect. In addition to its contribution to facial dimension and asymmetry, the mandible has unique and important functional features. The mandible is the only bone in the face that moves in relation to the skull. Additionally the mandible bears powerful muscular stresses and injury can make this bone functionally disabled.<sup>1</sup> Condylar neck is the weakest structural part of the mandible in relation to their resistance to mechanical force. The incidence of condylar fracture is the highest (35.6%) among those of other regions in mandible.<sup>2,3</sup> The pattern of the fracture can vary greatly and may occur anywhere down a line from sigmoid notch to the mandibular angle. Condylar neck fractures are clearly different from other mandibular fractures in as much as they are always located behind and above the lingual.

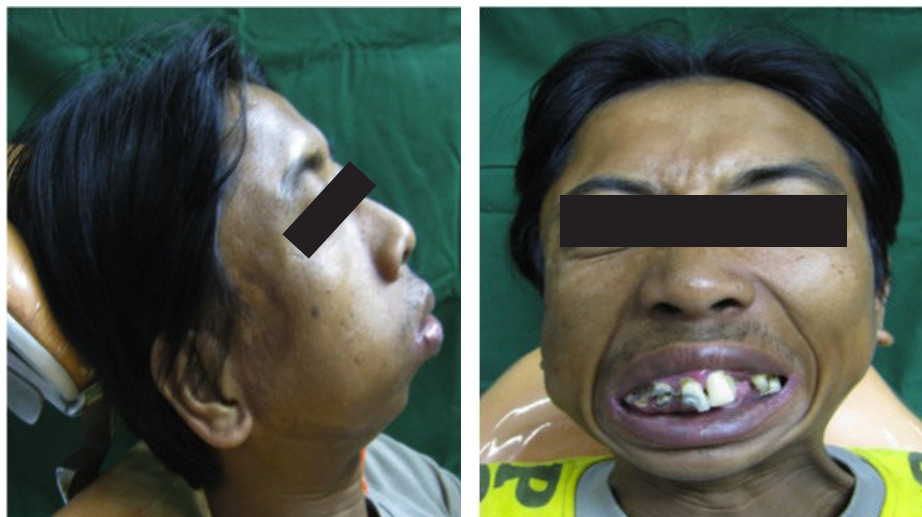They also differ from mandibular body fractures because they are more difficult to diagnose clinically and radiologically.<sup>3</sup> Condylar fracture may occur as a result of either direct trauma in the area of temporomandibular joint or indirect trauma in the chin region, mandibular angle, condyle and the subcondylar region. Complications of condylar fracture may include occlusal disturbances, internal derangement of the articular disc, ankylosis of the joint, and mandibular growth disturbances. If the condylar fractures occur in children at the age of active mandibular growth it should be treated with caution as ankylosis of the temporomandibular joint may take place and lead to the mandibular growth disturbances which may eventually cause facial deformities and functional problem later in

life. In this article a case of condylar fracture because of mechanical trauma during childhood is presented which has caused ankylosis of temporomandibular joint and mandibular growth disturbances.

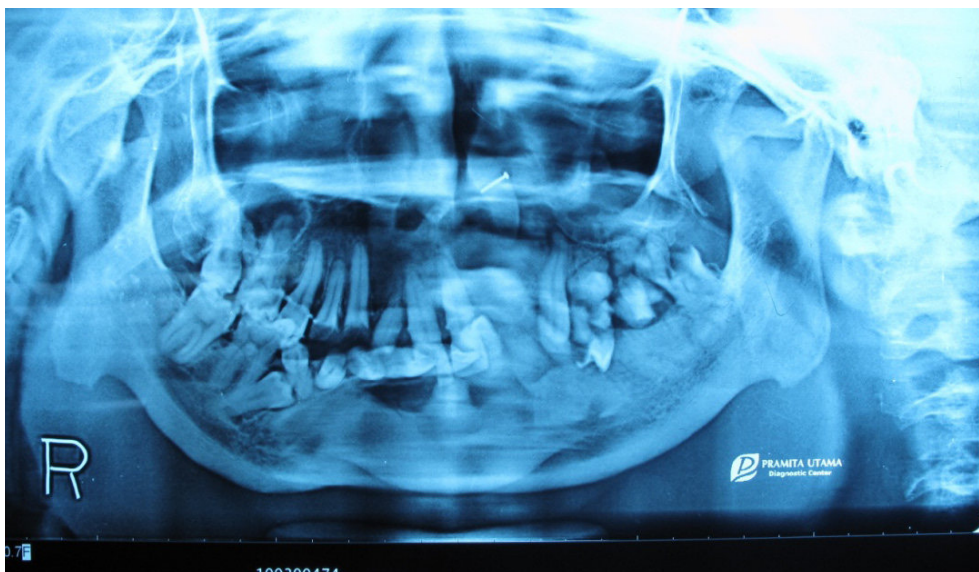## CASE

A 28 years old male patient came to Oral and Maxillofacial Surgery Clinic, Faculty of Dentistry, Airlangga University complaining that he was unable to open his mouth. According to the patient this condition has been lasting for 20 years which started not long after he got a traffic accident at the eight years of age. He was admitted to a hospital during which suturing to the right side of his head and chin were made. Since then his mouth opening was restricted and the condition worsened with time until finally he was completely unable to open his mouth. He has been on liquid diet until today.

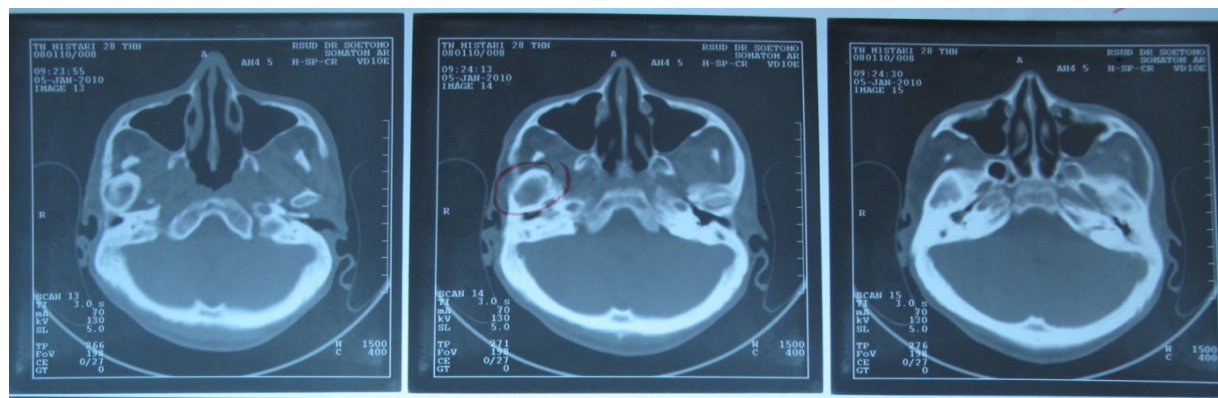
Clinical examination showed facial asymmetry with large area of scar tissue on his right zygomatic and preauricular region, mandibular retrognathism, and severe trismus (Figure 1). Intra oral examination was difficult to perform due to the trismus. Panoramic x-ray showed ankylosis of the right temporomandibular joint whereas the left joint seemed somewhat normal with the presence of joint space (Figure 2). CT scan of the head revealed loss of the normal structure of the right temporomandibular joint showing large ossification area over the region (Figure 3). The diagnosis made was bony ankylosis of the right temporomandibular joint.



**Figure 1.** The profile of the patient showing "bird face" appearance indicating a severe mandibular retrognathism (left) and severe trismus (right).



**Figure 2.** Pre-operative panoramic x-ray showing the absence of normal structure of temporomandibular joint on the right side, anatomical structure of the left joint seems normal.



**Figure 3.** Axial projection of CT scan of the head showing large ossification area replacing the normal anatomical structure of right temporomandibular joint.

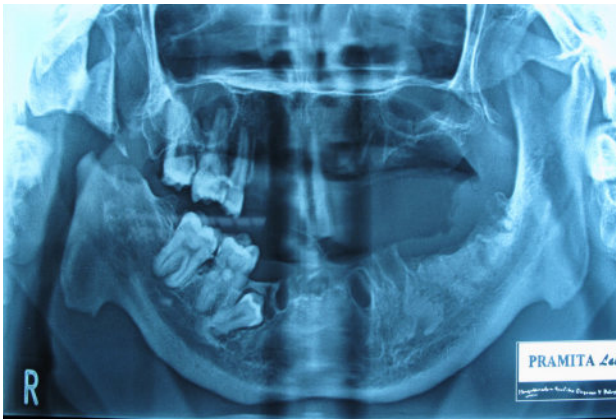## CASE MANAGEMENT

The case was treated surgically with gap arthroplasty of the right temporomandibular joint under general anesthesia. Tracheostomy was performed pre-operatively as blind intubation was difficult to do. Preauricular incision was made and the wound deepened layer by layer until the ankylotic condylar bone was found. A bur was used to create a gap between body of the mandible and the bony ankylosis as wide as 1 cm. The resulting rough edges were smoothed out using Rongeurs forceps and bone file. Using Heister mouth opener the mouth was able to open approximately 3 cm and maintained afterwards. Mersilen mesh™ was packed up in the gap and sutured to the muscles. A Redon drain was placed and Vicryl 4.0 sutures were used to close the wound in layers. A nylon 5.0 suture was used to close the skin.

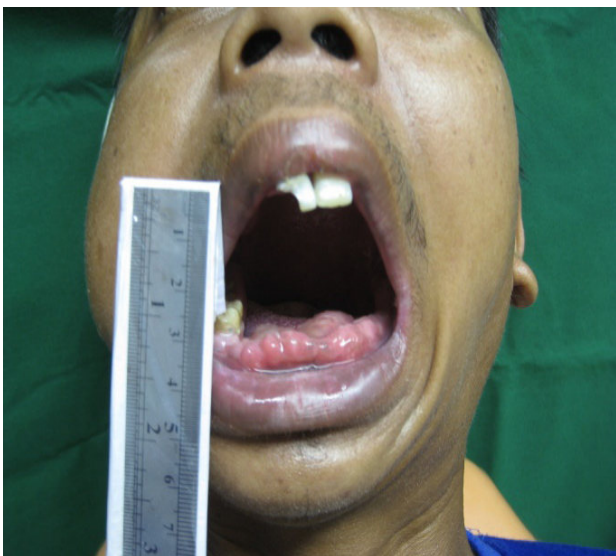The patient had no specific complaints after surgical procedure. The Heister were maintained for two days after the surgery to keep the mouth open for two days to prevent recurrence of the trismus caused by muscles spasm. Three days post operative, the tracheostomy tube was taken out and Redon drain removed at fourth day.

The patient was discharged from the hospital after removal of the drain. Post operative panoramic x-ray was taken on the day he left the hospital, the result of which clearly showing the gap created in the right subcondylar neck region (Figure 4). The patient was instructed to continue mouth opening exercise using Heister for 6 month. The skin sutures were removed at seventh day. Three weeks after the surgery the patient came back in good general health condition and was able to open his mouth normally (Figure 5).





**Figure 4.** One week post-operative panoramic x-ray showing the gap created in the right subcondylar neck.



**Figure 5.** Three weeks post-operative condition showing normal mouth opening.

## DISCUSSION

The causes and treatment of TMJ ankylosis have been well documented, with trauma and infection identified as the two leading causes.<sup>4-6</sup> In children, TMJ ankylosis can result in mandibular retrognathism with attendant esthetic and functional deficits. Classification of ankylosis can be based on the tissues involved and extent of involvement: complete or partial, true or pseudo ankylosis, or bony, fibrous, or fibroosseous.<sup>4</sup> In the case presented above it is most likely that the ankylosis of right temporomandibular joint and the mandibular retrognathism are associated with the history of trauma to the mandible when he was 8 years-old.

Condylar fractures are usually caused by indirect trauma in the chin. There are 3 types of kinetic energy that can cause fracture of the condyle: a) kinetic energy that comes from a moving object hitting a static individual, e.g. a punch, b) kinetic energy coming from a moving individual

towards a static object e.g. fall from height and hitting the floor, c) combination of the two types above.<sup>2</sup> In the above case there was no evidence of chin trauma but a large scar tissue was found over the skin of preauricular region. It is likely that there has been a direct, high energy trauma to the right TMJ region causing condylar fracture, instead of indirect trauma on the chin through one of the three types of kinetic energy mentioned above.

The ankylosis of the temporomandibular joint in this case was possibly caused by intra capsular hemorrhage which led to formation of bony union in the joint space. The predisposition to ankylosis in the joint may also be associated with the occurrence of intracapsular type of fracture which are common in children as their condylar heads are still immature, thinly covered and highly vascularized which tend to burst open and result in hemarthrosis filled with multiple comminuted fragments of bone with high osteogenic potential. It is suggested that direct contact between the articular fossa and the fractured fragments with torn joint meniscus are commonly found in intracapsular fractures of temporomandibular joint.<sup>2</sup>

The patient in this case exhibited severe growth disturbance of the mandible characterized by the obvious facial asymmetry, mandibular retrognathism, and radiographically by the presence of bony prominence at the angle of the mandible. How the ankylosis of the temporomandibular joint can affect mandibular growth can be explained with several theories of mandibular growth.

Brash in 1930 dictated that condylar cartilage was thought to provide the dominant growth impetus to the mandible and the term "condylar growth centre" was much used. The mandible was likened to a long bone, with the cartilage of the condyle acting as an epiphyseal growth-plate cartilage. Additional appositional bone formation was thought to be stimulated at the sites of insertion of the masseter at the angle, the temporalis to the coronoid, and the alveolar margin in response to the stimulus of mastication.<sup>2</sup>

The theory, proposed by Mosh in 1968, also known as "functional matrix theory" stated that the mandible develops in conjunction with the morphogenetic demands of the enveloping soft tissues, particularly muscles and ligaments, acting through their periosteal attachments. The mandibular condyle is not the site of primary growth but has secondary adaptive response which allows the condylar head to stay in the glenoid fossa as the mandible develops downwards and forwards with the demands of the functional matrix.<sup>2</sup>

The condylar growth centers are crucial in mandibular development. Each centre consists of chondrogenic, cartilaginous, and osseous zones. A thin vascular layer covers the chondrogenic zone. Bone is deposited at the posterior borders of the rami and condyles. Trauma to the growth center just beneath the articular disc is important to be concerned. Delayed growth on the affected side can cause facial asymmetry, mandibular deviation, and malocclusion.<sup>1</sup> Mandibular growth is principally attributed to intramembranous osteogenesis, augmented by focal

endochondral ossification at the condylar head, mandibular angle, and coronoid process. The subsequent complex growth patterns including synchronized cortical drifting at the lateral and medial periosteal surfaces leading to forward and downward mandibular rotation and expansion. Mandibular growth also depends on muscles attachment, i.e. temporalis, masseter, and pterygoid muscles, while tooth development and eruption influence alveolar development.<sup>7</sup>

Regardless of which theory is used to explain the mandibular growth, it is clear that since the condylar fracture in the above case took place within the growing period of the mandible, the normal growth on the right side of the mandible has not ensued. The condyle, which plays important role in the elongation of the mandible, was structurally damaged. In addition, as there has been no mastication for a long time the apposition type of growth did not occur in the sites of masseter and temporal muscle insertion. This two masticatory muscles induce the mandibular growth. It is believed that temporomandibular ankylosis in growing child may alter the growth because of destruction of the growth area in the TMJ cartilage as well as function limitation will decrease the influence of soft tissues on developing bone.<sup>8,9</sup>

It is clear that both panoramic and CT scan showed bony union between condyle and the fossa on the right side. These findings are consistent with the criteria for bony ankylosis.<sup>4,10</sup> The left temporomandibular joint, on the other hand, seems to have normal structure with the articular space still being present.

As the diagnosis of the patient was bony ankylosis of the temporomandibular joint the treatment of choice was surgery. The basic objective of TMJ ankylosis surgery should be to restore mouth opening and joint function.<sup>3,11</sup> Regardless of variables, such as age and type of ankylosis, the basic principles of ankylosis release should be followed, these including gap arthroplasty for resection of the ankylosis mass and interpositioning of a material or structure of choice to prevent the recurrence of ankylosis. In this case gap arthroplasty was performed and an interpositional material, Mersilen mesh<sup>TM</sup>, was placed in the gap to prevent the recurrence of ankylosis. The created gap would then act as a new joint, also termed as pseudoarthrosis.<sup>12</sup> This surgical procedure enables the patient to open his mouth normally.

In conclusion, ankylosis of temporomandibular joint and disturbance of mandibular growth may occur as the complication of condylar fracture in children. The first sign of significant problems may be the increasing limitation of jaw opening. Early diagnosis, good treatment and post-operative physiotherapy of the temporomandibular joint should be done to achieve the optimum mouth opening as well as to avoid the recurrence of the trismus.

## REFERENCES

1. Faust RA, Younes AA. Mandible fractures in children. Available at: <http://emidicine.medscape.com/article/872662-overview>. Accessed June 16, 2010.
2. Bradley P. Injuries of the condylar and coronoid process. In: Rowe NL, Williams JLI, editors. Maxillofacial injuries. Volume 1. Edinburg, London, Melbourne, New York: Churchill, Livingstone; 1985. p. 337-61.
3. Gerlach KL, Erle A, Eckelt U, Loukota RA, Luhr HG. Surgical management of mandibular, condylar neck, and atrophic mandible fractures. In: Booth PW, Schendel SA, Hausamen JE, editors. Maxillofacial surgery. Volume 1. Churchill, Livingstone. 2007. p. 80-92.
4. Nayak PK, Nair SC, Krishnan DG, Perciaccante VJ. Ankylosis of the temporo mandibular joint. In: Booth PW, Schendel SA, Hausamen JE, editors. Maxillofacial surgery. Volume 2. Churchill, Livingstone. 2007. p. 1521-37.
5. Rishiray B, Mc. Fadden LR. Treatment of temporomandibular joint ankylosis: A Case Report. J Can Dent Assoc 2001; 67(11): 659-63.
6. Weteid AA, Elkrish E, Mutairi KA, Foghm SA. Temporomandibular joint ankylosis caused by mastoiditis: Presentation of a rare case and literature review. Saudi Dent J 2000; 12(2): 103-5.
7. Lavelle C. Craniofacial development in development and anatomy relevant to the head, neck, and orofacial tissues. Available at: <http://www.abe.pl/html/samples/b/0198510969.pdf>. Accessed June 16, 2010.
8. Tucker MR. Correction of dentofacial deformities. In: Peterson LJ, Ellis E III, Hupp JR, Tucker MR, editors. Contemporary oral and maxillofacial surgery. 2<sup>nd</sup> ed. St. Louis: Mosby; 1993. p. 613-5.
9. Li Z, Zhung W, Li ZB. Induction of traumatic temporomandibular joint ankylosis in growing rats: a preliminary experimental study. Dent Traumatol 2009; 25(1): 136-41.
10. El-Hakim IE, Metwalli SA. Imaging of temporomandibular joint ankylosis: a new radiographic classification. Dentomaxillofac Radiol 2002; 31(1):19-23.
11. Bayat M, Badri A, Moharamnejad N. Treatment of temporomandibular joint ankylosis: gap and interpositional arthroplasty with temporal muscle flap. J Oral Maxillofac Surg 2009; 13(4): 207-232-212.
12. Ortak T, Ulusoy MG, Sungur N. Silicon in temporomandibular joint ankylosis surgery. J Craniofac Surg 2001; 12(3): 232-6.