

Case Report

Acupuncture analgesia: The complementary pain management in dentistry

Abdurachman

Department of Anatomy-Histology
Medical Faculty, Airlangga University
Surabaya-Indonesia

ABSTRACT

Background: Pain is the most common reason for medical consultation in the United States. Pain is a major symptom in many medical conditions, and can significantly interfere with a person's quality of life and general functioning. One of the very unpleasant pain is toothache. Conventional treatments for toothache are improving oral hygiene, prescribing analgesics, anti-inflammatory, and also antibiotics if there are infection even extractions are performed if necessary. Another way to conventional approaches, patients may consider acupuncture method. Acupuncture involves the insertion of needles with the width of a human hair along the precise points throughout the body. This process triggers body's energy normal flow through extra anatomy pathway called meridian. **Purpose:** This case report is aimed to emphasize the existence of teeth-organ relationships through communication channels outside the lines of communication that has been known in anatomy. **Case:** Two patients with toothache complaints in the lower right molars came to an acupuncturist who was a medical practitioner. In these cases pain were relieved by acupuncture analgesia. **Case management:** Two patients were subjected to acupuncture analgesia with different acupuncture points that were customized to the affected tooth, case 1 with the large intestine-4 (Li-4) which located in the hand and case 2 with bladder-25 (Bl-25) which located in the back of the body. Ninety percent of pain was relieved in 40 seconds. **Conclusion:** Pain in toothache can be relieved using acupuncture analgesia technique, using meridian as an extra anatomy pathway. Nevertheless, treating the source of pain by dental practitioner is mandatory.

Key words: Acupuncture analgesia, pain, dental

ABSTRAK

Latar belakang: Nyeri adalah alasan paling umum yang menyebabkan orang datang berkonsultasi kepada profesional medis di Amerika Serikat. Nyeri merupakan gejala utama dalam kasus medis, dan dapat mengganggu kualitas hidup dan kegiatan umum seseorang secara signifikan. Salah satu nyeri yang sangat tidak menyenangkan adalah nyeri gigi. Pengobatan selalu diarahkan kepada menjaga kebersihan mulut, memberikan analgesik, mengurangi inflamasi dan menambahkan antibiotik jika ada infeksi bahkan jika perlu dilakukan ekstraksi gigi. Cara lain dari pendekatan konvensional di atas adalah pasien dapat mempertimbangkan metode akupunktur. Akupunktur dilakukan dengan menusukkan jarum seukuran rambut manusia di sepanjang titik yang tepat di seluruh tubuh. Proses ini memicu aliran normal energi tubuh melalui jalur ekstra anatomi disebut meridian. **Tujuan:** Laporan kasus ini untuk menekankan adanya hubungan gigi-organ melalui jalur komunikasi di luar jalur komunikasi yang telah dikenal dalam anatomi. **Kasus:** Dua penderita dengan keluhan nyeri gigi geraham kanan bawah dilakukan terapi analgesia akupunktur oleh akupunkturis yang adalah dokter umum. Dalam kasus ini ditunjukkan bahwa rasa nyeri pada gigi dapat dihilangkan menggunakan teknik akupunktur. **Tatalaksana kasus:** Pasien dengan keluhan nyeri gigi, kasus #1 pada rahang bawah dilakukan terapi akupunktur pada titik Li-4 pada tangan dan kasus #2 pada titik Bl-25 pada pinggang. Pemilihan titik disesuaikan dengan keluhan pasien, menurut teori meridian dalam akupunktur. Nyeri berkurang sampai 90% dalam 40 detik. **Kesimpulan:** Keluhan nyeri pada gigi dapat dihilangkan menggunakan teknik akupunktur analgesia, menggunakan meridian sebagai jalur komunikasi di luar jalur komunikasi anatomi. Walaupun demikian perawatan kedokteran gigi pada penyebab nyeri yang utama adalah yang paling penting.

Kata kunci: Akupunktur analgesia, nyeri, kedokteran gigi

Correspondence: Abdurachman, c/o: Departemen Anatomi-Histologi, Fakultas Kedokteran Universitas Airlangga. Jl. Mayjend. Prof. Dr. Moestopo No. 47 Surabaya 60131, Indonesia. Email: rachman1166@yahoo.com. Telp: +62 31 5020251 Fax: +62 31 5022472

INTRODUCTION

Pain is the most common reason for medical consultation in the United States.¹ Pain is a major symptom in many medical conditions, and can significantly interfere with a person's quality of life and general functioning.² One of the very unpleasant pains is toothache. Conventional treatment are improving oral hygiene, prescribing analgesics and anti-inflammatory, and add antibiotics if infection involved, or even extractions are performed if necessary.³ Another way from conventional approaches, patients may consider acupuncture method. Acupuncture involves the insertion of needles with the width of a human hair along the precise points throughout the body. This trigger maintains the normal body's energy (chi) flow through extra anatomy pathway called meridian, a communication path that is existed aside from nerve, blood and lymph vessels. In acupuncture theory, it is mentioned that chi flows through the body's meridians. If this chi flows is disrupted, complains (included pain) or symptoms according to the degree of disruption and the affected meridian where disrupted will appear.

then acts as natural pain relief for toothache. The effect of acupuncture as pain reliever is commonly termed as acupuncture analgesia. Acupuncture is able to ease muscle spasm, promote blood circulation and remove blood stasis, diminish inflammation and swelling and promote tissue repair function. In a word, acupuncture is able to cure for pain in toothache by addressing both the symptoms and the primary cause. The map of energy communication path (part of large intestine meridian) in a human body's is shown in the following picture (Figure 1).⁴

According to Gellman,⁵ the body's vital energy flows through specific channels so called meridian and regulates the whole body function of the body's organ. Meridian is channels which connect all the body's components. Aside from connecting all of the body's energy internally, meridian also connects the body's internal energy with external energy (natural energy) through "doors" called acupuncture points.

Stimulation on acupuncture points will be transmitted via meridian communication path. Stimulation will affect circulation of the existing energy system, then creating a healing effect, especially to meridian that is connected directly to the stimulated acupuncture point. Diameters of the acupuncture points are approximately between one to three millimeters.⁵

The depths from the surface of the skin are according to the place and are different individually. It has long been known that acupuncture points have some specific characteristics. Superficial acupuncture points have high electric potential (can reach as high as 300 mV), high electric capacitance (0.1–1 mF), low electric resistance, ability to increase skin respiration, high local temperature, radiating light which spontaneously visible from Jing and Yuan points, and sound signals (frequency 2–15 Hz, amplitude: 0.5–1 mV). Deep acupuncture points have low perception threshold to electric stimulation, high capacity, electric resonance with the other acupuncture points, high conductivity to isotopic tracers.⁶

In the following case report it will be shown that pain in toothache can be relieved using acupuncture technique, another way from conventional treatment in dentistry.

CASE

Case 1: Female 19 years old came with toothache complaint to an acupuncturist who is a medical practitioner. Extraoral examination showed swollen cheek in the lower right cheek area. Intra-oral examination showed periodontal abscess approximately in the location of #47 (Figure 2). The toothache had been felt since ten days before and

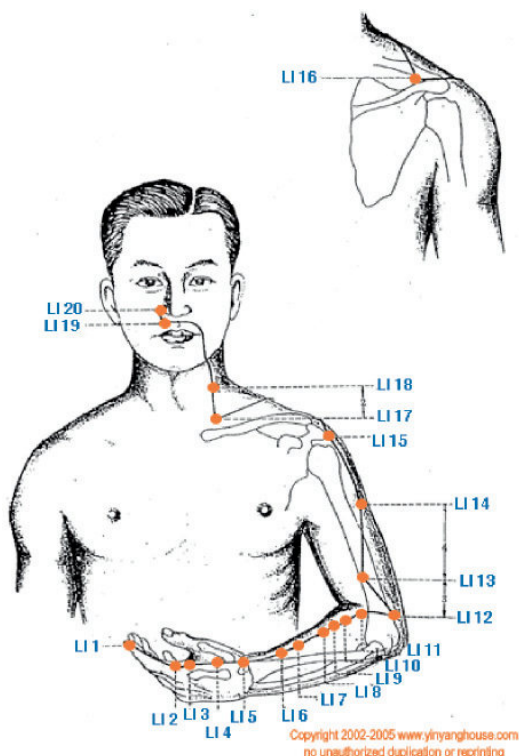


Figure 1. Large intestine meridian.⁴

As for severe pain in toothache, acupuncture can stir up the chi of meridian, regulate chi, clear channels which

resulting in chewing difficulty. The patient suddenly felt pain in that area and continued for about 3 days. Patient treated her pain by consuming antibiotics and analgesics. Nevertheless, the periodontal abscess were still increasing and the pain was not disappear (Figure 3). Body temperature was not elevated.

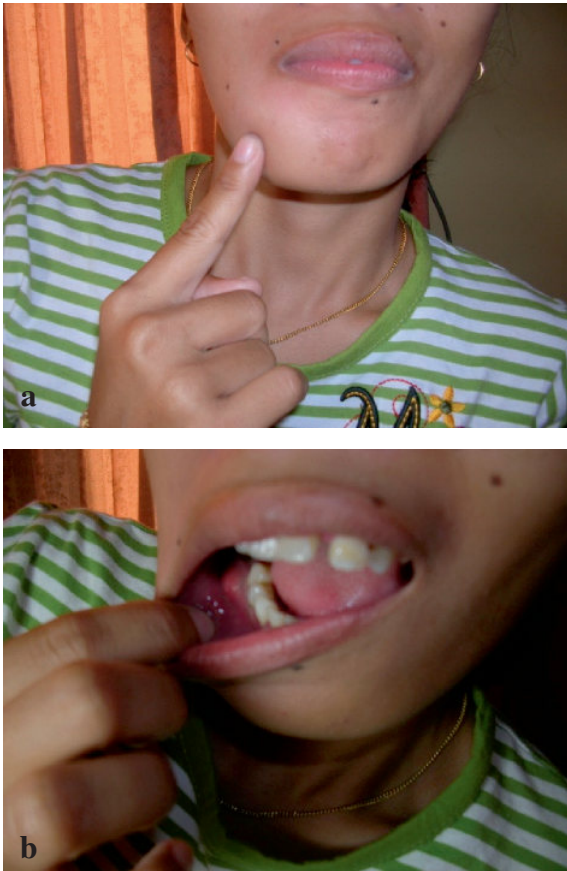

Figure 2. a) The location of complaint, first case; b) Gum swell.



Figure 3. Point punctured at Li-4.

Case 2: Female 36 years old came with toothache complaint. Extra-oral examination showed normal appearance. Intra-oral examination showed redness in

gingival color, and more pronounced in the location of #46 and #47 (Figure 4). The pain was suspected caused by periodontal disease. Toothache had been felt since two days before which caused chewing difficulty. The gingiva was swollen and the pain was mimicking canker sores. Pain was increased suddenly and the teeth were felt like going off. Body temperature was not elevated. (Figure 5).

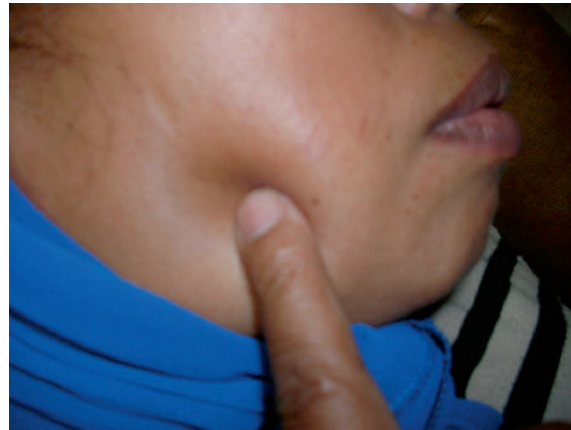

Figure 4. Location of complaint.

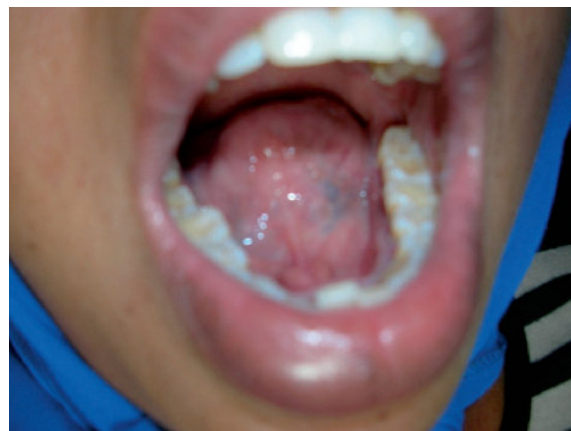

Figure 5. There were no swelling and no difference color between right and left gum.

CASE MANAGEMENT

Case 1: The medical practitioner performed acupuncture therapy using acupuncture needle (stainless steel) sterile size 0.25 × 25 mm. The needle was punctured perpendicularly into the large intestine-4 (Li-4) acupuncture point, in the middle of the 2nd metacarpal bone on the radial side (Figure 4). Point selection was customized to the patient's complaint, according to the theory of meridians in acupuncture.⁷ Acupuncture needle was rotated in clockwise then counter-clockwise direction and vice versa. Alternating rotation was conducted 40 seconds. Once the needle is removed, ninety percent of the pain was disappeared and patient is not complain anymore. Afterwards, patient referred to a dental practitioner for further treatment.

Case 2: In some patients, for reasons of fear of needles, stabbing can be done in other places far from the complaints but still related to the large intestine meridian. Another point that could be used for this purpose is an equal at the low back, below the spinous process of the 4th lumbar vertebra, 1.5 cun lateral to the posterior midline (Figure 6).

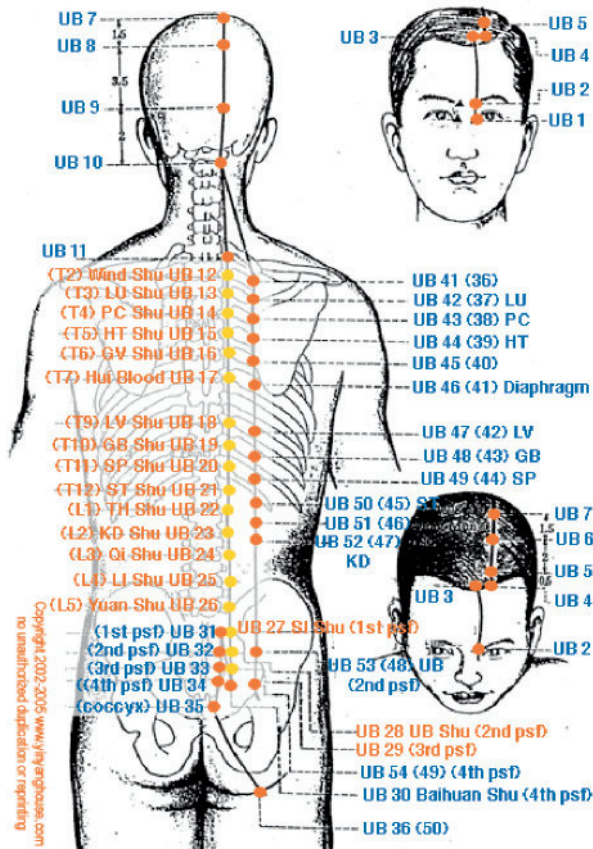


Figure 6. Bladder meridian and back-shu (BI-25) acupuncture point.⁴

The medical practitioner performed acupuncture therapy by acupuncture needle (stainless steel) sterile size 0.25 × 40 mm. Acupuncture needle was punctured perpendicularly at the Bladder-25 (BI-25) (Figure 7). Acupuncture needle was rotated clockwise direction then counter-clockwise direction and vice versa. Alternating rotation was conducted 40 seconds for each point. Once the needle is removed, the pain disappeared. Afterwards, patient referred to a dental practitioner for further treatment.

DISCUSSION

Acupuncture has a different system of communication lines with the lines of communication as it is commonly known in the science of anatomy. These communication channels are called meridians, the extra anatomy pathway. In Western medicine, channels of communication is known through the nerves, lymph vessels and blood vessels. As a communication pathway, meridian is not mentioned above,

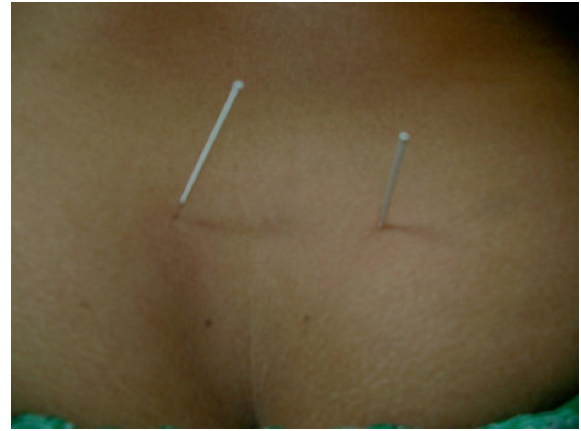


Figure 7. The site location of acupuncture needle (BI-25).

but it is a separate path, a signal transduction pathway. Along the meridians there are acupuncture points.⁸ Each meridian correlated with each organ. Each meridian has its own main indication. Large Intestine meridian for example (Figure 1), the pathway start up at the posterior aspect of the arm, enters the lung in the chest. A branch goes down and connects with the large intestine. Another branch goes up around the mouth to the other side of the body.^{8,9}

Pain is classified into the Bi syndrome in acupuncture. Bi syndrome caused by the blockade of the body's energy flow. Therapy for pain relief which termed as acupuncture analgesia is done by re-launching the body's energy flow.⁵ Point Li-4 was chosen as an effective point for the body's energy flow in Large Intestine energy lines, especially for unblocked of body energy flow in #47 (Figure 9).

BI-25 acupuncture points are the sited of the back-shu points of Large intestine. The back-shu points are the points on the back where chi of the respective solid-hollow organs is infused (solid organ like lung, heart, liver and hollow organ i.e. large intestine, small intestine, gall bladder). They are located on either side of the vertebral column. Each of the solid-hollow organs has a back-shu point, as does the large intestine (BI-25), a total of twelve.⁹

Stimulation at point BI-25 for example, will cause the effect of improvements in organ colon and other organs related. In accordance with Chinese medicine, colon organ associated with the first and second molar (Figure 8, 9). In the first case, Li-4 acupuncture point is used because this point is consistent with the complaint in patient, according to the selection point according to traditional Chinese medicine. In the second case, the point BI-25 was chosen because patient felt fear do to acupuncture therapy in the visible region. Point BI-25 is the back-shu point of the large intestine meridian, which also can be used to perform therapeutic measures in accordance with patient complaints.^{7,9-11}

The relationship between an organ and its acupuncture point had been proven through laboratory experimental research by Sagiran,¹² and Abdurachman¹³ had scientific based that the effect of laser at bladder-20 (BI-20) point, the back-shu point for pancreatic gland, can make β cell increase the number as well as the function.

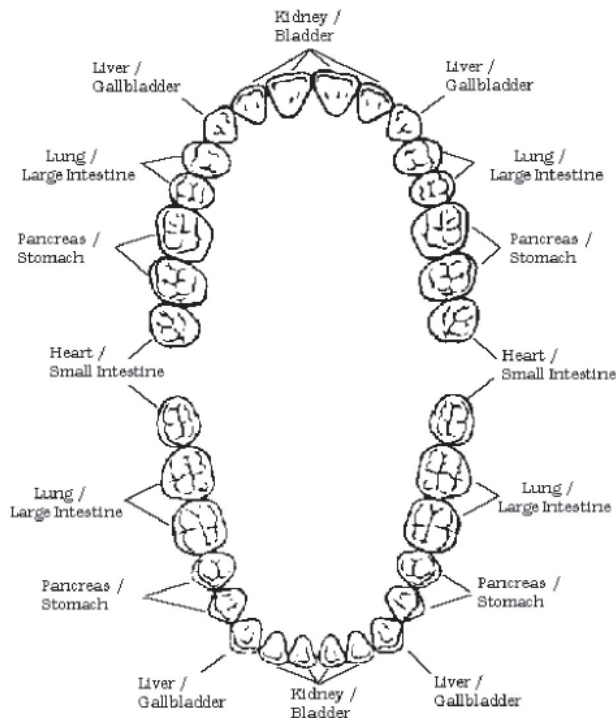


Figure 8. Dental-acupuncture-points.¹⁰

Figure 9. Correlation chart of each tooth with body organs.¹¹

Stimulation in gall bladder-34 (Gb-34) point can relieve pain in dextral hypochondrial area that caused from an old wound in infra malleolus lateralis dextra.¹⁴ The wound is

appropriate with Gb-40 point in acupuncture. This finding impressed the existence of extra anatomy pathway called meridian in acupuncture.

Based on the literatures which support the acupuncture analgesia concept, it can be concluded that: pain in toothache can be relieved using acupuncture technique. This finding impressed the existence of extra anatomy pathway called meridian in acupuncture, furthermore this finding support that acupuncture' technique can relief pain in toothache quickly, the site of acupuncture point due to toothache can be located at a distant site from the main complaint. This finding also impressed the relation between special tooth and special organ in the body. Nevertheless, treating the source of pain by dental practitioner is mandatory.

REFERENCES

1. Turk DC, Dworkin RH. What should be the core outcomes in chronic pain clinical trials?. *Arthritis Res Ther* 2004; 6(4): 151-4.
2. Breivik H, Borchgrevink PC, Allen SM, Rosseland LA, Romundstad L, Hals EK, Kvarstein G, Stubhaug A. Assessment of pain. *Br J Anaesth* 2008; 101(1): 17-24.
3. Bautista D, Shiel Jr. WC. Toothache. Available at: <http://www.medicinenet.com/toothache/article.htm>. Accessed April 2, 2011.
4. Dupuis C. Ying Yang house. Available at: <http://www.yinyanghouse.com/acupuncturepoints/li1>. Accessed April 2, 2011.
5. Gellman H. Acupuncture treatment for musculoskeletal pain. A text book for orthopedics, anesthesia and rehabilitation. New York: Taylor and Francis; 2002. p. 3-7.
6. Starwynn D. Electrophysiology and the acupuncture systems. *Medical Acupuncture* 2001; 13(1): 41-5.
7. Yanfu Z. Chinese acupuncture and moxibution. Shanghai, China: Publishing House of Shanghai University of Traditional Chinese Medicine; 2002. p. 41-143.
8. Shang C. The mechanism of acupuncture - Beyond neurohumoral theory. Available at: <http://acupuncture.com/education/theory/mechanismacu.htm>. Accessed April 2, 2011.
9. Yin G, Liu Z. Advanced modern chinese acupuncture therapy. China: New World Press; 2000. p. 91-115.
10. Lerner DL. The centre for holistic dentistry. 2008. Available at: <http://www.holisticdentist.com/image-pages/dental-acupuncture-points.html>. Accessed April 14, 2011.
11. Revins T, Weisz S. Tooth/ organ relationship. Available at: <http://www.ravecoholistic.com/toothchart.html>. Accessed at April 2, 2011.
12. Sagiran. The effect of pancreatic β cell damage to the electrical voltage profile of difference acupuncture points. Thesis. Yogyakarta: Post Graduate Program University of Gajah Mada; 2001.
13. Abdurachman. Effect of laser at *Pishu* point on amount and function of pancreatic β cell (*Rattus norvegicus*) injected by Streptozotocin. An Experimental Study. *Folia Medica Indonesiana* 2005; 42(1): 8-16.
14. Abdurachman. Acupuncture therapy to relieve pain in dextral hypochondrial area. Case report. *Folia Medica Indonesiana* 2009; 45(3): 232-6.