

## Research Report

## Effect of soybean extract after tooth extraction on osteoblast numbers

Rosa Sharon Suhono<sup>1</sup>, Coen Pramono<sup>2</sup>, and Djodi Asmara<sup>2</sup>

<sup>1</sup> Dental Student

<sup>2</sup> Department of Oral and Maxillofacial Surgery

Faculty of Dentistry, Airlangga University

Surabaya - Indonesia

### ABSTRACT

**Background:** Many researches were done to find natural materials that may increase and promote bone healing processes after trauma and surgery. One of natural material that had been studied was soybean extract which contains phytoestrogen, a non-steroidal compounds found in plants that may binds to estrogen receptors and have estrogen-like activity. **Purpose:** The aim of this study was to investigate the effect of soybean extract feeding on the number of osteoblast cells in alveolar bone socket after mandibular tooth extraction. **Methods:** This study was studied on male *Rattus norvegicus* strain Wistar. Seventeen rats divided into three groups were used in this study. Group 1 fed with carboxy methyl cellulose (CMC) solution 0,2% for seven days, and the left mandibular central incisivus was extracted; group 2 fed with soybean extract for seven days and the left mandibular central incisives was extracted; group 3 received the left mandibular central incisives extraction followed by soybean extract feeding for seven days after the extraction. All groups were sacrificed on the seventh day post-extraction, and the alveolar bone sockets were taken for histopathological observation. The tissues were processed and stained using hematoxylin and eosin to identify the amount of osteoblast cells. The number of osteoblast cells was counted using an Image Tool program. The data was analyzed statistically using the One-Way ANOVA test. **Results:** Significant differences were found on the number of osteoblast cells in alveolar bone after tooth extraction between groups. Group 2 (fed with soybean extract) is higher than group 1 (fed with CMC) and group 3 (fed with soybean extract after extraction). **Conclusion:** Soybean extract feeding that given for seven days pre-tooth extraction can increase the number of osteoblast cells compared with the group that were not given soybean extract feeding and also with the group that were given soybean extract feeding for seven days post-tooth extraction.

**Key words:** Tooth extraction, soybean extract, phytoestrogen, osteoblast

### ABSTRAK

**Latar belakang:** Pada masa sekarang, banyak dilakukan penelitian-penelitian untuk menemukan bahan-bahan alami yang dapat mendukung dan meningkatkan proses remodeling tulang untuk mengembangkan perawatan penyakit osteoporosis dan juga untuk mengembangkan penyembuhan tulang pasca trauma dan pasca pembedahan. Salah satu bahan alami yang banyak diteliti adalah ekstrak kedelai yang mengandung fitoestrogen, suatu senyawa non-steroid yang terdapat dalam tumbuhan, yang dapat berikatan dengan reseptor estrogen dan memiliki bioaktivitas yang sejenis dengan hormon estrogen. **Tujuan:** Tujuan dari penelitian ini adalah untuk meneliti pengaruh ekstrak kedelai yang mengandung fitoestrogen terhadap jumlah sel osteoblas pada tulang alveolar pasca pencabutan gigi. **Metode:** Penelitian ini dilakukan pada tikus wistar jantan. Tujuh belas ekor tikus dibagi menjadi tiga kelompok sampel dalam penelitian ini. Kelompok sampel tersebut mendapatkan perlakuan yang berbeda-beda. Kelompok 1 dilakukan feeding larutan CMC 0,2% selama tujuh hari, kemudian dilakukan pencabutan satu gigi insisivus sentral kiri rahang bawah, kelompok 2 dilakukan feeding ekstrak kedelai selama tujuh hari, kemudian dilakukan pencabutan satu gigi insisivus sentral kiri rahang bawah, kelompok 3 kelompok yang dilakukan pencabutan satu gigi insisivus sentral kiri rahang bawah, kemudian diberikan feeding ekstrak kedelai selama tujuh hari pasca pencabutan gigi. Semua kelompok dikorbankan pada hari ketujuh pasca pencabutan gigi, dan soket bekas pencabutan gigi tersebut diambil untuk dibuat sediaan histopatologis. Jaringan tersebut diproses dan dilakukan pengecatan dengan hematoxylin and eosin untuk melihat sel osteoblas. Setiap preparat diperiksa di bawah mikroskop cahaya dan sel osteoblas dihitung

dengan menggunakan program *Image Tool*. Data hasil penelitian kemudian dianalisa dengan uji statistik *One-Way ANOVA*. **Hasil:** Terdapat perbedaan yang signifikan pada jumlah sel osteoblas pada tulang alveolar pasca pencabutan gigi, antara kelompok sampel yang mendapatkan feeding ekstrak kedelai sebelum pencabutan gigi (Kelompok 2) dibandingkan dengan (Kelompok 1) dan (Kelompok 3). **Kesimpulan:** Pemberian ekstrak kedelai selama tujuh hari sebelum pencabutan gigi dapat meningkatkan jumlah osteoblas.

**Kata kunci:** Pencabutan gigi, ekstrak kedelai, fitoestrogen, osteoblas

*Correspondence:* Rosa Sharon Suhono, c/o: Mahasiswa, Fakultas Kedokteran Gigi Universitas Airlangga. Jl. Mayjend. Prof. Dr. Moestopo no. 47 Surabaya 60132, Indonesia. E-mail: ros.sharon@yahoo.com

## INTRODUCTION

Tooth extraction is a treatment that should be done for severely damaged tooth. The process of wound healing after tooth extraction generally consists of several phases, begins with the formation of blood clots in the socket, continued to inflammation process, infiltration of leukocytes, formation of connective tissue, formation of granulation tissue, epithelialization and regeneration of new bone to close the remaining empty socket. When a tooth is removed, the socket is filled with blood, which coagulates and form blood clot. The inflammatory stage occurs during the first week of post extraction. White blood cells enter the socket to remove contaminating bacteria and any debris from the area, such as bone fragments that are left in the socket. Fibroplasia also begins during the first week, with the growth of fibroblasts and capillaries. Finally, in the end of the first week of healing, osteoclasts accumulate along the crystal bone to start bone resorption, followed by osteoblasts that responsible to the process of bone formation. The cortical bone was resorbed from the socket and new trabecular bone is laid down across the socket. As bones fill the socket, the epithelium moves toward the crest and eventually becomes level with adjacent gingival crest. This processes continue and usually take sometime before a socket heals and becomes the edentulous alveolar ridge.<sup>1,2</sup> Factors that can be related to the healing process is generally divided into common factors and local factors. The common factors includes: age, nutrition, vitamins, hormones, metabolic status, and circulation status. Local factors includes: blood supply, foreign bodies, tissue movement and damage, type of tissue, infections, mechanical factors, size, location, and type of wound. Those factors can also be related to the healing process of tooth extraction.<sup>3</sup>

Nuts and seeds such as soybean, peanut, winged bean seeds, coconut and others are the sources of proteins and fats which are important in human life. Soybean is mostly found in Indonesia and has protein content of 35%. The improved varieties of soybean may even contain protein levels of 40–43%. Compared to rice, maize, cassava flour, green bean, meat, fresh fish, and egg, soybean has higher protein content, nearly as high as the protein content found in dried skim milk. Soybean can be processed into tempeh, tofu, soybean sauce, soybean milk, etc. The processing process of soybean into many kind of food is simple, and the

equipments needed are commonly found in the household, except for the stripper, grinder, and mould.<sup>4</sup>

Soybean contained some chemical substances, one of them is known as phytoestrogen, a non-steroidal compounds found in plants, which have in part some structural similarities to estrogen hormone, that is  $17\beta$ -estradiol.<sup>5</sup> Currently, four different families of phenolic compounds produced by plants are considered as phytoestrogen: the isoflavonoid, stilbenes, lignans and coumestans.<sup>6</sup> Soybean is the main source of phytoestrogen isoflavones group, namely as genistein and daidzein.<sup>7</sup>

Endogenous estrogen levels are associated with human bone homeostasis. Estrogen is known to play an important role in maintaining bone mass. Lack of estrogen levels may causes excessive bone resorption, and the estrogen deficiency results in bone loss.<sup>8</sup> Bone volume is maintained by two phases of bone remodelling: one is bone resorption by osteoclasts, and the other one is bone formation by osteoblasts. It is known that bone remodelling is controlled by various cytokines and hormones, such as interleukin-1 (IL-1), interleukin-6 (IL-6), parathyroid hormone, glucocorticoids, and estrogen hormone.<sup>9</sup>

Many researches were done to find some natural materials that may increase and promote bone remodeling in order to improve treatment in osteoporosis, and bone healing process after trauma and after surgery. Phytoestrogen such as genistein and daidzein found in soybean were investigated and showed its estrogen-like activity because of its structural similarities to  $17\beta$ -estradiol. Natural phytoestrogen found in soybean extract can increase osteoblast cells proliferation in cells MC3T3-E1, the osteoblast-like cell line from rat.<sup>10</sup> Phytoestrogen may as influence in increasing alkaline phosphatase activity in MC3T3-E1 cells in vitro and found that phytoestrogen can also be used as one of the osteogenic local agents in vivo.<sup>5</sup> The aim of this study was to investigate the effect of soybean extract feeding on the number of osteoblast in the alveolar bone socket after mandibular tooth extraction histopathologically.

## MATERIALS AND METHODS

This study was done in healthy male Wistar strain rats, aged 2-3 months and weighed between 150–200

**Table 1.** Number of osteoblast in control group (K)

No.	Slides	Number of osteoblast			Mean of osteoblast cell number each slide
		Bottom region	Middle region	Top region	
1	K.4	40	32	36	36
2	K.5	18	23	22	21
3	K.6	34	78	123	78.33
4	K.7	44	40	48	44
5	K.9	41	27	30	32.67

**Table 2.** Number of osteoblast in treatment group 1 (P1)

No.	Slides	Number of osteoblast			Mean of osteoblast number each slide
		Bottom region	Middle region	Top region	
1	P1.1	91	80	95	88.67
2	P1.2	172	181	134	161.33
3	P1.3	181	232	159	190.67
4	P1.4	172	180	138	163.33
5	P1.5	241	225	76	180.67
6	P1.6	79	93	43	71.67

**Table 3.** Number of osteoblast in treatment group 2 (P2)

No.	Slides	Number of osteoblast			Mean of osteoblast number each slide
		Bottom region	Middle region	Top region	
1	P2.1	133	69	86	96
2	P2.2	159	125	117	133.67
3	P2.3	48	85	66	66.33
4	P2.4	28	97	60	61.67
5	P2.7	77	50	77	68
6	P2.8	80	49	35	54.67

grams. Samples were divided into three groups: control group who received feeding of carboxy methyl cellulose (CMC) solution concentration of 0.2% equivalent to 9 cc/200 gram of rat's body weight per day for seven days before-tooth extraction; the treatment group 1 (P1) which fed with soybean extract feeding using a dose of 9 cc/200 gram of rat's body weight/day for seven days before-tooth extraction; treatment group 2 (P2) which fed with soybean extract feeding 9 cc/200 gram of rat's body weight per day for seven days after-tooth extraction.

"Surya" white Soybean available in local market in Madiun, East Java was used in this study. The soybean extract was made using Akebono brand soybean extractor machine and sixty grams of dried Soybeans was soaked for 12 hours and inserted into the Soybean extractor machine. 1500 cc of warm water was added and 1500 cc of soybean extract liquid obtained.

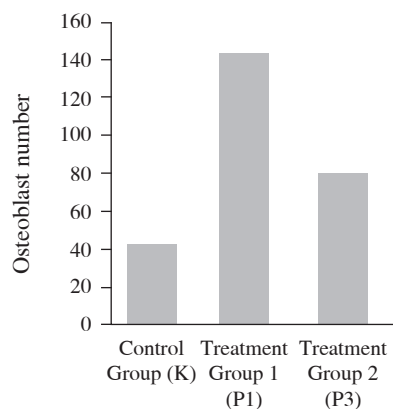
The control group was fed with 0.2% CMC solution in a dose of 9 cc/200 gram of rat's body weight per day for seven days. A feeding tube was connected into a syringe was the feeding instrument used in this purpose. Seven

days after fed with CMC 0.2% solution, the experimental animals in the control group were anesthetized for tooth extraction. General anesthesia with ether solution was used and the process was done by putting the experimental animal into a glass jar contained of cotton wool soaked with ether solution. The experimental animals were inserted and the jar was closed for several minutes until the animal was unconscious. The left mandibular central incisives was removed using a modified forceps which was made for rat's tooth rat extraction. Tooth extraction bleeding was stopped by pressing the socket wound using sterile cotton. Soybean and CMC feeding in the control groups were not given for seven days but only received a drinking water. The same procedure was performed on the P1 group and this group was fed with soybean extract feeding with the dose of 9 cc/200 gram of rat's body weight per day for seven days pre-tooth extraction. Tooth extraction was performed in the experimental animals in P2 group. The same procedure as in the control group and P1 group was used. Soybean extract feeding of 9 cc/200 gram of rat's body weight per day was given for seven days post-tooth extraction in this group.

After all experiment procedures were completed, all animal samples were sacrificed using an overdosed ether solution on the seventh day post-extraction to examine the osteoblast cell that has begun to accumulate along the alveolar bone lining the socket.<sup>1</sup> The mandible bone of the experimental animals were taken from the skull and inserted into the fixative solution of 10% formalin solution. The alveolar bones were taken for further histopathological slide preparation procedure. The tissues were cutting in serial in rotary microtome with 6 $\mu$  of thickness followed by tissue staining using haematoxylin and eosin (HE). All slides fields were observed for the present of osteoblast cells in 400x of magnification. Three different areas were observed as those are the top, bottom and the middle regions of the tooth extracted socket which are adjacent to the post extraction alveolar bone. The number of osteoblast cells were counted using the computer program "Image Tool", a program used to analyze and process free images. Analysis function of images in this program can be done in variety including the dimensional measurement, i.e. measurement of distance, angle, area, and also a certain scale of measurement in the form of points, lines, or areas and it is completed with a counting of its standard deviation.<sup>11</sup> The statistical difference in the number of osteoblast cells during bone remodeling processes after tooth extraction among those three sample groups were statistical analyzed using the One-Way ANOVA test.

## RESULTS

The results on osteoblast cells observation on those three areas of tooth extraction socket on the seventh day after-extraction is shown in table 1, 2, 3. Based on data, it is shown that the difference number of osteoblast cells are found higher in the sample group who received soybean extract feeding (P1, P2 groups), compared to the control group (K) in which soybean extract feeding was not given (Figure 1).



**Figure 1.** Osteoblast cell number in alveolar bone at seventh days post-extraction, in control group, treatment group 1, and treatment group 2.

The data of the number of osteoblast cells in each group were analyzed using Kolmogorov-Smirnov test for normality and homogeneity test results in each group. The result of this test showed that distribution of data in each groups were normal, means that the data in each groups were homogenous. The analysis was done using One-Way ANOVA test ( $p < 0.05$ ,  $\alpha < 0.05$ ), indicating that there are significant difference in osteoblast cell numbers between in the control group (K) and in the treatment group 1 (P1). The same results also showed in treatment group 1 (P1) compared to those in the treatment group 2 (P2). No significant difference was found between the control group (K) and in the treatment group 2 (P2) ( $p > 0.05$ ).

## DISCUSSION

The soybean extracts and its proteins, carbohydrates, fats, calcium, phosphorus, iron, provitamin A, vitamin B complex (except B12) and water contained showed statistically able to enhance the regeneration process of bone healing after tooth extraction.<sup>4</sup> The calcium and phosphorus contain found in soybean extract will increase the intake of calcium and phosphorus, which are needed for the bone regeneration process. Soybeans also have low sulfur amino acid content, which known as acids can inhibit calcium resorption through kidneys, and therefore may cause considerable loss of calcium in the urine.<sup>7</sup> These facts supported the result of this study that overall there are a significant difference in bone regeneration process, marked by the different number of osteoblast cells that found higher in the treatment group who received a soybean extract feeding, compared to the control group who did not fed with the soybean extract. Statistical result of tests using the One-Way ANOVA showed a significant difference in the number of osteoblast cells between the control group and group P1 ( $p < 0.05$ ). These results showed that soybean extract feeding on experimental animals seven days pre-extraction can affect the total amount of alveolar bone osteoblast cells compared to those the control group.

Phytoestrogens has a capability to bind to estrogen receptors in the body competitively with estrogen hormone, so the number of osteoblast cells production can be found higher.<sup>12,13</sup> Thus occurred because the binding process between estrogen receptor and phytoestrogens may influence the osteoblast cells production by improving the process of synthesis, activation, receptor binding, and local growth factor binding protein in osteoblast, either directly or indirectly. Transforming growth factor- $\beta$  (TGF- $\beta$ ) and insulin-like growth factor-1 (IGF-1) which may support the process of cell proliferation from osteoblast precursor cells that is preosteoblas into osteoblasts also activated during the presence of phytoestrogen. The synthesis of bone matrix by osteoblast cells thereby affect in increasing of osteoid deposition during bone regeneration process.

Soybean extracts containing phytoestrogens will increase the anabolic function of osteoblasts cells.<sup>13</sup> The

study on soybean extracts which contain phytoestrogens was reported can stimulate the protein synthesis in osteoblast cells *in vitro*.<sup>13</sup> Synthesis of these proteins will support the process of new osteoblast cell proliferation by accelerating the process of cell differentiation from preosteoblast into osteoblasts.

Binding of phytoestrogens with estrogen receptors on osteoblast cells will improve the synthesis of IGF-1 and TGF- $\beta$ .<sup>13,14</sup> Increase of TGF- $\beta$  as the effect of estrogen receptor binding to the phytoestrogens found in soybean extract on the process of osteogenesis has been demonstrated histochemically, and the results showed that mRNA expression of TGF- $\beta$  in cell culture of human bone marrow containing mesenchymal stem cells that is also called stem cells which can differentiate into osteoblast precursor cells, was observed at day 3 after phytoestrogens treatment *in vitro*, and continued to increase until day 21, then disappeared.<sup>15</sup> Increased growth factors will accelerate the process of differentiation and maturation of preosteoblasts into osteoblasts. TGF- $\beta$  and IGF-1 also supports a mature osteoblast cells in bone matrix synthesis process for forming osteoid deposition of cartilage tissue that has not been calcified.<sup>16</sup>

In addition, it is also reported that soybean extracts containing phytoestrogens can increase the viability of osteoblast cells and increases the activity of alkaline phosphatase and osteocalcin synthesis by osteoblast cells.<sup>13</sup> Osteocalcin is a non-collagen protein bone matrix, which synthesis stimulated by 1.25-dihydroxicolecalciferol.<sup>16</sup> Soybean extracts containing phytoestrogens can increase the synthesis of 1.25-dihydroxicolecalciferol, which receptors are also present in the cell membrane of osteoblast.<sup>13</sup> Soybean extracts containing phytoestrogen will stimulate 1.25-dihydroxicolecalciferol, which will provide a direct influence on the synthesis and stabilization of osteocalcin at the transcriptional and post-transcriptional phase, so that the process of osteocalcin synthesis by osteoblast cells will increase. Osteocalcin is an important component in the process of bone regeneration because osteocalcin is a non-collagen bone protein that functions in the process of calcium ions binding in bone regeneration, assisted by vitamin K1.<sup>16</sup> Those reported facts can be used to explain our study in the present of osteoblast cells that produced in group P1 is found more mature, so that the new bone trabeculae also more in the experiment group of P1 than shown in the control group. In addition, alkaline phosphatase and osteocalcin produced by osteoblast cells indicates that osteoblast cells are already mature and can produce an optimal bone matrix.<sup>16</sup>

The One-Way ANOVA test results also indicates a significant difference in osteoblast cells contained shown in groups P1 and P2 ( $p < 0.05$ ), where the mean of osteoblast cells number in groups P1 is higher than in group P2. This event can be explained that the soybean extract were given

in different sequences in all experiment animals in groups P1 and groups P2.

The removal of tooth initiates some sequences of inflammatory process, fibroplasia, formation of granulation tissue, epithelialization. This pathophysiological sequence can be found during the formation of new bone to close the remaining empty post-extraction socket. The inflammatory stages occurs during the first week of healing process, and feeding with soybean extracts which containing of phytoestrogen during the first week post-extraction to the treatment group 2 (P2) will affect to those inflammatory process.

It was reported that phytoestrogens contained in the soybean has an anti-inflammatory effect by inhibiting proinflammatory cytokine production, that is: IL-6, through inhibition of gene transcription of IL-6 process, which occur because of estrogen receptor binding with phytoestrogen.<sup>13</sup> IL-6 are proinflammatory cytokines that have a significant role in the inflammatory process by improving the accumulation and formation of osteoclast.<sup>16</sup> IL-1 and IL-6 would increase the process of bone resorption, and inhibition of cytokines production will also decrease the number of osteoclasts accumulation, this event would affect in decreasing of bone resorption. Therefore, soybean extracts which contain phytoestrogens given in group P2 might affects not only in the increasing number of osteoblast cells, but also decrease osteoclasts cells accumulation. Although the process of new bone regeneration in tooth extracted socket is present, but the observation showed that the increased number of osteoblast cells in groups P2 is significantly found less as seen in group P1.

The result of this study on the amount of osteoblast cells found in treatment group (P2) and in the control group (K) showed different mean value of osteoblast cells number although this evidence was not statistically significant. It is occurred because soybean extracts feeding which contain phytoestrogens given in group P2 might affects not only in the increasing number of osteoblast cells, but also related to the whole inflammatory process, so the number of osteoblast cells in group P2 was not significantly found higher than in control group which were not given soybean extract. Control group did not receive soybean extract as in group P1 and group P2, so the process of bone regeneration occurred normally with normal amount of osteoblast cells proliferation. The 0.2% CMC solution feeding was given to the control group with purpose to achieve the same physiological conditions in their intestinal tract both the animal control group and treatment group. Although the process of new bone regeneration in tooth extracted socket is present, but the observation showed that the increased number of osteoblast cells in groups P2 was not significantly different than the control group.

It is concluded that soybean extract feeding for seven days before-tooth extraction can increase the number of osteoblast.



## REFERENCES

1. Peterson LJ, Ellis E, Hupp JR, Tucker MR. Contemporary oral and maxillofacial surgery. 4<sup>th</sup> ed. St. Louis: Mosby; 2003. p. 49–74.
2. Sudiono J, Kurniadhi B. Ilmu patologi. Jakarta: EGC; 2003. p. 112–6.
3. Kumar V, Abbas AK, Fausto N. Robbins and cotran pathologic basis of disease. 7<sup>th</sup> ed. Philadelphia: Elsevier Saunders; 2005. p. 107–14.
4. Esti, Sediadi A. Buku panduan teknologi pangan, pusat informasi wanita dalam pembangunan PDI-LIPI bekerjasama dengan Swiss Development Cooperation. Jakarta. 2000. Available at: [http://www.warintek.ristek.go.id/pangan\\_kesehatan/pangan/piwp/susu\\_kedelai.pdf](http://www.warintek.ristek.go.id/pangan_kesehatan/pangan/piwp/susu_kedelai.pdf). Accessed March 30, 2010.
5. Wong RWK, Rabie ABM.. Effect of quercetin on preosteoblast and bone defects. The Open Orthopaedics J 2008(2): 27–32.
6. Cornwell T, Wendie C, Ilya R. Review: Dietary phytoestrogens and health. Phytochemistry. 2004; (65): 995–1016. Available online at: [www.sciencedirect.com](http://www.sciencedirect.com). Accessed March 30, 2010.
7. Koswara, Sutrisno. Isoflavon: Senyawa multi manfaat dalam kedelai. 2006. Available at: <http://www.ebookpangan.com>. Accessed March 30, 2010.
8. Arnita. Fitoestrogen untuk wanita menopause. Majalah Farmacia 2007 Juni; 6(11): 22.
9. Ganong WF, 2001. Buku ajar fisiologi kedokteran. Edisi 20. Widjajakusumah D, editor. Jakarta: EGC; 2003. P. 367–80, 423–6.
10. Kanno S, Hirano S, Kayama F. Effect of phytoestrogen and environmental estrogen on osteoblastic differentiation in MC3T3-E1 cells. Toxicology 2004; 196: 137–45. Available at: [www.sciencedirect.com](http://www.sciencedirect.com). Accessed April 5, 2010.
11. Dove, Brent S. UTHSCSA ImageTool version 3.0 final is here. 2002. Available at: <http://ddsdx.uthscsa.edu/dig/itdesc.html>. Accessed December 13, 2010.
12. George NN, Hopkins NE, Boue S, Alworth WL. Interactions of dietary estrogen with human estrogen receptors and the effect of estrogen receptor-estrogen response element complex formation. Environmental Health Prespective. 2000; 108(9): 867–72.
13. Hassan, Nahed M, Hassan RA, Setta LMA, El-moinem MMA, Ahmed HH, Hammouda FM. Potent role of dietary phytoestrogen plants cultivated in egypt against osteoporosis in ovariectomized rats. Australian J Basic and Applied Sciences 2010; 4(2): 359–69.
14. Kim H, Xu J, Su Y, Xia H, Li L, Peterson G, Murphy-Ullrich J, Barnes S. Actions of the soybean phytoestrogen genistein in models of human chronic disease: potential involvement of transforming growth factor  $\beta$ . Biochemical Society Transactions 2001; 29(2): 216–21.
15. Heim M, Frank O, Kampmann G, Sochocky N, Pennimpede T, Fuchs P, Huznicker W, Weber P, Martin I, Bendik I. The phytoestrogen genistein enhanced osteogenesis and represses adipogenic differentiation of human primary bone marrow stromal cells. Endocrinology 2004; 145(2): 848–59.
16. Favus MJ. Primer on the metabolic bone diseases and disorders of mineral metabolism. 2<sup>nd</sup> ed. New York: Raven Press; 1993. p. 3–9, 15–37.