

The application of lesion sterilization and tissue repair 3Mix-MP for treating rat's dental pulp tissue

Raditya Nugroho,¹ Ananta Tantri Budi,² and Sri Kunarti²

¹ Department of Conservative Dentistry, Faculty of Dentistry, Universitas Jember, Jember-Indonesia

² Department of Conservative Dentistry, Faculty of Dental Medicine, Universitas Airlangga, Surabaya-Indonesia

ABSTRACT

Background: Lesion sterilization and tissue repair (LSTR) 3Mix-MP are three broad-spectrum antibiotics, including metronidazole, ciprofloxacin and minocycline are mixed with propylene glycol or macrogol. There is the possibility of the healing process that marked proliferation of new blood vessels and proliferation of fibroblasts in the treatment of irreversible pulpitis by pulp capping LSTR 3Mix-MP because of the principle of the method LSTR 3Mix-MP is to kill bacteria. **Purpose:** The purpose of this study to prove the effect of LSTR 3Mix-MP on chronic inflammation and the healing process in rat dental pulp tissue in vivo. **Methods:** *Rattus norvegicus* anaesthetized by using ketamine and xylazine dissolved in sterile isotonic saline solution (0.2 ml/50gr mm) on the upper right thigh. Cavity preparation class I to perforation by using a low speed tapered diamond round bur. In the treatment group, rats were treated 3Mix-MP at a dose of 10 mg and then covered with glass ionomer cement for 7 days on the pulp that has been opened for 3 days. The control group treated with saline irrigation on the pulp that has been opened for 3 days. Rats were killed after seven days, and then made preparations pulp tissue to count the number of lymphocytes, macrophages, plasma cells, blood vessels, and fibroblasts **Results:** There is an increase in the average number of macrophage cells, plasma, and fibroblasts; and decreased lymphocytes and blood vessels in the treated group exposure LSTR 3Mix-MP. **Conclusion:** LSTR 3Mix-MP can reduce chronic inflammation process and enhance the healing process in rat dental pulp tissue.

Keywords: LSTR 3Mix-MP; chronic inflammation; healing

Correspondence: Raditya Nugroho, c/o: Departemen Konservasi Gigi, Fakultas Kedokteran Gigi Universitas Jember. Jl. Kalimantan I No. 37 Jember 68121. E-mail: ranugtab@gmail.com

INTRODUCTION

Lesion sterilization and tissue repair (LSTR), also called non instrument endodontic treatment (NIET), is a new treatment with or without pulp and periapical infections by using a mixture of three antibiotics as disinfection.¹ The mixture of those three antibiotics is considered as quite powerful antibiotics in eradicating bacteria compared to a single antibiotic.^{2,3} Thus, this disinfection treatment is expected to heal the lesion fast.

This treatment actually was developed by Cariology Research Unity of the Niigata University School of Dentistry in 1988. There was disagreement about LSTR in the earlier studies showing that LSTR therapy, using a

mixture of metronidazole, ciprofloxacin, and minocycline (three materials) and a mixture of carrier materials, such as *macrogol and propylene glycol* (MP), has toxic effect on the cell culture of fibroblast.^{1,4} In addition, the use of antibiotic pasta may cause bacterial resistance.² Thus, the use of LSTR is still questionable and requires further research.

Moreover, there are different opinions on the mixture ratio and the proportion of antibiotics used in LSTR, namely metronidazole, ciprofloxacin and minocycline (3Mix). Some researchers use a mixture of 3: 1: 1, while others use 3: 1: 3 like what Hoshino did. Three antibiotics (3Mix) were mixed with propylene glycol or macrogol as the carrier (MP) of 3Mix into the dentinal tubules killing all the bacteria in lesion. 3Mix is incorporated into MP using the following 1:5 (MP:3Mix) or 1:7 (standard mix).^{5,6}

Inflammation, furthermore, is a protective mechanism that is limited to trauma or microbial invasion by destroying, diluting, or restricting hazardous materials causing tissue damage. Acute inflammation even can cause the elimination of harmful agents followed by decreasing the reaction and repairing damaged tissue. If the cause of the inflammation cannot be removed, there will be a chronic inflammation. Chronic inflammation is characterized by mononuclear infiltration (lymphocytes, macrophages, and plasma cells), tissue destruction and repair marked with the proliferation of new blood vessels and fibroblasts. Inflammatory healing reaction then will arise immediately after the injury while acute inflammatory reaction will be running. Nevertheless, the healing process still can occur if the cause of the injury can be destroyed or neutralized. This process consists of the replacement of dead cells by live cell.⁷⁻⁹

Direct pulp capping treatment have used pulp perforation technique due to mechanical bur trauma or deep caries cleaning with reversible pulpitis diagnosis. In the clinics of Faculty of Dental Medicine, Universitas Airlangga, however, reversible pulpitis with pulp perforation treatment is rare. In general, people come up with superficial dental caries, or teeth that were perforated before with irreversible pulpitis diagnosis.

Irreversible pulpitis is an inflammation of the pulp that cannot recover normally even if the cause of inflammation is removed. Damage that occurs in irreversible pulpitis can be caused by surgical procedures or blood flow interruption in the pulp due to trauma. In irreversible pulpitis, there is also a bacterial infection occurred in pulp.¹⁰ A treatment using LSTR 3Mix-MP is expected to heal irreversible pulpitis since a previous research conducted by Takushige *et al.* shows that the perforation of pulp and pulpitis with spontaneous pain can cause positive clinical results.¹¹

Nevertheless, the mechanism of pulp therapy using LSTR 3 Mix-MP is still unclear. There is still a possibility of irreversible pulpitis healing process in pulp capping treatment using LSTR 3Mix-MP since its principle is to kill bacteria. It means that if bacteria can be removed, then inflammation can subside, thereby allowing dental pulp tissue repair.¹¹ Therefore, a further research is needed to know the effectiveness of the provision of LSTR 3Mix-MP on the healing process by calculating a chronic inflammatory cells (lymphocytes, macrophages, and plasma cells), fibroblasts, and blood capillaries.

MATERIALS AND METHODS

In this research, experimental animals used were male Wistar strain *Rattus norvegicus* aged 8-16 weeks and weighed 200-250 grams. Moreover, samples used for control group were treated with saline irrigation in their pulp that has been opened for 3 days. Meanwhile, samples used for treatment group were similarly treated to a previous research conducted by Sabir¹² in which those animals were anaesthetized by using ketamine and xylazine dissolved in

sterile isotonic saline solution (0.2 ml/ 50gr mm) on their upper right thigh. Thus, the similar working principle of asepsis was conducted. All the tools were sterilized by dry heat of 160° C for 1 hour. The disinfection was conducted on the upper right thigh of those animals with betadine before intramuscular anesthesia was conducted. The first right molars of the lower jaw were disinfected with 70% alcohol. Class I cavity with perforation was prepared by using low speed tapered round diamond bur no. 200s (Intensive, Switzerland) with a bur's diameter of 0.84 mm closer to the pulp, and then the thin layer of dentin was penetrated to the perforation in the pulp chamber area. Those animals were given 3Mix-MP at a dose of 10 mg, and then the pulp that had been opened for 3 days filled with glass ionomer cement for 7 days. 3Mix-MP used was a pasta combination of LSTR, a mixture of ciprofloxacin, metronidazole, and minocycline, with a ratio of 1: 3: 3 (3Mix) mixed with macrogol and propylene glycol to be formed.

All samples in the control group and in the treatment group were sacrificed after seven days of the treatment. Their jawbone in the interdental areas of mandibular molars then was cut and put into the fixation solution. This research using independent t-test with significance level of 95%($p < 0.05$) to see the difference in the number of lymphocytes, macrophages, plasma cells, blood vessels, and fibroblasts between control and treatment groups. The normality of the data was tested first by using Kolmogorov-Smirnov test, while the homogeneity of the data was tested by using Levene Test.

RESULTS

It can be seen that the average numbers of macrophages, plasma cells, and fibroblasts in the treatment group exposed with LSTR 3 Mix-MP on their dental pulp tissue had larger perforations than those in the control group without LSTR 3 Mix-MP exposure (Figure 1). The average numbers of lymphocytes and blood vessels in the treatment group were lower than those in the control group. In short, it can be said that the numbers of lymphocytes, macrophages, blood vessels and fibroblasts in the treatment group were significantly different from those in the control group with the significance value less than 0.05 ($p < 0.05$). Meanwhile, the number of plasma cells in the treatment group was not significantly different from that in the control group with the significance value greater than 0.05 ($p > 0.05$).

DISCUSSION

This research used Wistar strain *Rattus norvegicus* as experimental animals because those animals are easy to care, and also have a similar healing reaction to humans. In other words, their dental pulp has a similar reaction to humans dental pulp. Thus, the lower right first molar tooth

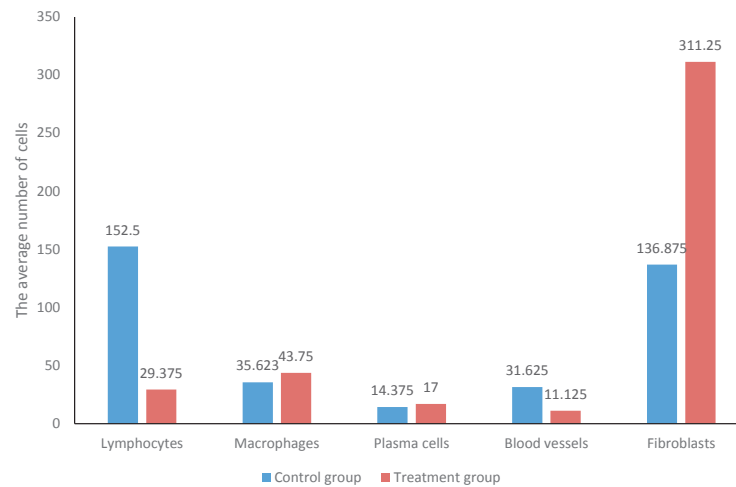


Figure 1. The average number of lymphocytes, macrophages, plasma cells, blood vessels, and fibroblasts.

was selected not only because the structure and anatomy of their tooth are similar to human's tooth, which can access to the pulp tissue, but also because the speed of attrition due to mastication on the occlusal surface of their molars is slower than their incisive.¹²

Based on the result of histopathological examination on the pulp tissues in the treatment group, then it is known the average numbers of macrophages, plasma cells, and fibroblasts in the treatment group were increased. Meanwhile, the average number of blood vessels in the treatment group was decreased compared to in the control group. The increasing average number of lymphocytes, macrophages, plasma cells, and fibroblasts and the decreasing average number of lymphocytes and blood vessels were associated with the healing process. In the healing process, there are actually several phases, namely inflammation, proliferation, and maturation.

In inflammation phase, vascular and cellular responses respond to injury. Both injury and thermal and mechanical exposure can usually cause interference with microvasculature, and subsequently can lead to bleeding. During this inflammation process, the vasoconstriction of blood vessels occurs with mediators, such as epinephrine, norepinephrine, prostaglandins, serotonin, and thromboxane. Vasoconstriction actually plays a role in reducing the occurrence of bleeding at the wound with the addition of platelet aggregation factors-other healing factors. Vasoconstriction is then followed by longer vasodilation period mediated by histamine, prostaglandins, kinins, and leukotrienes. Vasodilation is characterized by erythema, edema, and heat that occurs after an injury. Vasodilation is an important phase in which blood flow to the injured area is increased, followed by inflammatory cells and important factors in fighting infections and cleaning tissue damaged by the injury.¹²

In proliferation phase, the formation of granulation tissue occurs. The formed granulation tissue consists of inflammatory cells, fibroblasts, new blood vessels

in fibronectin matrix, collagen, glycosaminoglycans, and proteoglycans. This formation of granulation tissue occurs 3 to 5 days after the injury, and overlaps with the inflammation phase. In the proliferation phase, moreover, there are fibroplasia and angiogenesis processes. In the fibroplasia process, fibroblasts are the most important component. Fibroblasts are responsible for the formation of collagen, elastin, fibronectin, and glycosaminoglycans. The growth of fibroblast proteases in the wound can be considered as a form of the reduction of inflammatory cells. The existence of demand for the inflammation process will make the production of chemotactic factors, called inflammatory cells decreased and disappeared. Fibroplasia begins 3-5 days after the injury and can last for 14 days. Fibroblasts migrate and proliferate in response to the presence of fibronectin, platelet-derived factor (PDGF), fibroblast growth factor (FGF), transforming growth factor (TGF), and C5a.

In the angiogenesis process, the amount of blood supply is vital to maintain the shape of the newly formed tissue characterized by the presence of erythema at the newly formed scar. In the next process, the blood vessels will be lost because it is not needed anymore, so is in the formed scar. Macrophages are something essential in stimulating angiogenesis and in producing macrophage-derived angiogenesis factor in response to the deeper tissue oxygenation. The function of these factors are as chemoattractant in endothelial cells. Basic fibroblast growth factors are actually secreted by macrophages. Meanwhile, vascular growth factors are secreted by epidermal cells, considered as important factors in the occurrence of angiogenesis. Angiogenesis produce large blood flow in the injured area, and consequently will increase the perfusion factors-healing factors. In the next process, the cessation of angiogenesis will occur as a termination request from new blood vessels. The new blood vessels become too important to be lost by the presence of apoptosis.

In the maturation phase, moreover, collagen and cytokines play a role. Collagens are an important component in all phases of wound healing. Synthesized by fibroblasts, they impart integrity and strength to all tissues and play a key role, especially in the proliferative and remodelling phases of repair. Collagens act as a foundation for the intracellular matrix formation within the wound. Collagen remodeling during the maturation phase relies on the synthesis of collagen. Collagenase and matrix metalloproteinase in the wound actually helps to eliminate excess collagen during the synthesis of new collagen. Tissue inhibitor of metalloproteinase will inhibit collagenolytic enzyme, so there is a balance between the formation of new collagen and the disposal of old collagen. In addition to collagen, cytokines also play a role as an important mediator in the wound healing process.^{9,13}

Based on the results in this research, it is known that the numbers of macrophages, plasma cells, and fibroblasts in the treatment group were bigger than those in the control group associated with the provision of LSTR 3Mix-MP. It is because in the control group, inflammation process was still on progress to become chronic inflammation although the process could also improve to healing process. The healing process that occurred in the control group, however, was slower than in the treatment group. It is because in the control group, substance or agent that can help the healing process go faster was not given.

In addition, it is also known that the average number of blood vessels in the treatment group was about 11.125 smaller than in the control group, about 31.625. The low average number of blood vessels in the treatment group could be due to the faster healing process. It is because in the angiogenesis phase, as described earlier, there was a reduction or even elimination of the blood vessels that were not important. The loss of blood vessels actually has been programmed by the process of apoptosis.

It can be seen that the average number of fibroblasts in the treatment group was significantly increased compared to those in the control group. This condition is because of fibroplasia process in the proliferative phase. Fibroblasts play an important role in the healing process because fibroblasts are responsible for the formation of new tissue and the process of maturation in the next process. In the perforation area, the presence of fibroblasts is very important since they together with odontoblastoid synthesize collagen type I, which is instrumental in the formation of reparative dentin.¹⁴

In the treatment group, the healing process can be due to the provision of LSTR 3Mix-MP, which acts as an antibiotic. Antibiotics in LSTR 3Mix-MP consist of metronidazole, ciprofloxacin, and minocycline. The use of metronidazole alone has a role in inhibiting amoeba, trichomonas, and anaerobic bacterial infections. Metronidazole has a broad

bactericidal spectrum. Meanwhile, ciprofloxacin used in mixing antibiotics has a broad- antibiotic spectrum that can fight gram-positive and gram-negative bacteria. Minocycline, a group of tetracycline, has a broad antibacterial activity which includes gram-positive-negative, aerobic, and anaerobic bacteria.

In short, it can be said that after the dental pulp of those rats was drilled, the dental pulp was left open to let bacterial colonization, including good bacteria from dental bacteria, bacteria in saliva, and bacteria found in periodontal tissues. Inflammation process then occurred. But, inflammation process occurred in the control group lasted longer and became chronic inflammation process, while the inflammation process in the treatment group did not last long and got faster healing process. The existence of the healing process that occurs in the treatment group can be associated with a mixture of antibiotics, namely metronidazole, ciprofloxacin, and minocycline which has anti-bacterial power.¹¹

In conclusion, LSTR 3Mix-MP can reduce chronic inflammation process and enhance the healing process in rat dental pulp tissue.

REFERENCES

- Hendrawan C. Uji toksisitas lesion sterilization and tissue repair (3mix-MP) terhadap kultur sel fibroblas. Undergraduate Theses Airlangga University Library; 2007.
- Huang GJ. A paradigm shift in endodontic management of immature teeth: conservation of stem cells for regeneration. *J Dent* 2008; 36(6): 379-86.
- Mohammadi Z. Antibiotics as intracanal medicaments: a review. *CDAJ* 2009; 137: 99.
- Prabhakar AR, Sridevi E, Raju OS, Satish V. Endodontic treatment of primary teeth using combination of antibacterial drugs: an in vivo study. *J Indian Soc Pedod Prev Dent* 2008; 26 (Suppl 1): S5-10.
- Parasurama V, Muljibhai BS. 3Mix - MP in Endodontics: an overview. *JDMS* 2012; 3: 36-45.
- Handajani J, Haniastuti T, Ohshima H, Hoshino E. Survival of root canal pulp tissue after pulpitis. *J LSTR Ther* 2010; 9: 1-6.
- Kumar V, Cotran RS, Robbins SL. Robbins basic pathology. Michigan: Saunders; 2003. p. 31-5.
- Baratawidjaja K. *Imunologi dasar*. Edisi-4. Jakarta: Balai Penerbit FK UI; 2004. p. 153-70.
- Kumar V, Cotran RS, Robbins SL. *Buku ajar patologi*. Jakarta: EGC; 2007. p. 35-65.
- Ingle JI, Bakland LK. *Endodontics*. Fifth edition. London: BC Decker Inc; 2002. p. 31-40.
- Takushige T, Cruz EV, Moral AA, Hoshino E. Non surgical treatment of pulpitis, including those with history of spontaneous pain, using a combination of antibacterial drugs. *J LSTR Ther* 2008; 7: 1-5.
- Sabir A. Respon inflamasi pada pulpa gigi tikus setelah aplikasi ekstrak etanol propolis (EEP). *Oral Sci J* 2005; 47: 77-83.
- Velnar T, Hainar T, Smrkolj. The Wound Healing Process: an Overview of the Cellular and Molecular Mechanism. *J InMedRes* 2009; 37: 1528-42.
- Goldberg M, Smith AJ. Cell and extracellular matrices of dentin and pulp: a biological basis for repair and tissue engineering. *Crit Rev Oral Biol Med* 2004; 15(1): 13-27.