

Correlation between p53 expressions and histopathological grading in oral cavity squamous cell carcinoma

Silvi Kintawati

Department of Oral Biology
Faculty of Dentistry, University of Padjadjaran
Bandung – Indonesia

ABSTRACT

Background: Squamous cell carcinoma is a malignancy of oral cavity mostly occurred and can also metastasize. p53 gene is a tumor suppressor gene that plays an important role in carcinogenesis. The role of wild-type p53 is very important in suppressing the formation of a malignancy. p53 also has many other important functions. p53 is a suppressor of tumor/ cancer progression through the response of cell cycle to DNA damage and by giving time to repair DNA prior to replication of genes. p53 mutation, mostly occurs in a malignancy, so earlier histopathological transformation can be detected by observing p53 mutation. The prognosis of squamous cell carcinoma in oral cavity, therefore, depends on histopathological grading and clinical staging of the tumor. To enforce the histopathological grading, in addition based on histopathology differentiation, the earlier histopathological transformation can also be assessed. **Purpose:** This study aimed to determine the correlation of p53 expressions and histopathological grading in oral cavity squamous cell carcinoma. **Method:** This study was a retrospective study on 20 cases of oral cavity squamous cell carcinoma examined at Department of Pathology Anatomy in Hasan Sadikin Hospital in Bandung. Immunohistochemical examination was then performed using p53 antibodies to determine the correlation of p53 expression and histopathological grading in oral cavity squamous cell carcinoma to predict prognosis. **Result:** The overall results showed that there was no correlation between p53 expression and histopathological grading in oral cavity squamous cell carcinoma of the oral cavity although there was a very strong correlation between p53 expression and histopathological grading I ($p < 0.01$). **Conclusion:** It can be concluded that there was no correlation between p53 expression and histopathological grading in oral cavity squamous cell carcinoma. Thus, p53 expression cannot be used to predict a prognosis.

Keywords: p-53; squamous cell carcinoma; immunohistochemical

Correspondence: Silvi Kintawati, Department of Oral Biology, Faculty of Dentistry, University of Padjadjaran. Jl. Raya Jatinangor, Cibeusi, Jatinangor, Kabupaten Sumedang, Jawa Barat 45363, Indonesia E-mail: silvikintawati@yahoo.com

INTRODUCTION

Squamous cell carcinoma is a tumor often found in head and neck, 90% of which is oral cavity malignancy. Squamous cell carcinoma can also be considered as an aggressive disorder that can undergo metastasis and treatment failure, which can result in recurrence of the tumor.¹

Squamous cell carcinoma is a malignancy of the stratified squamous epithelium which can lead to local destruction and metastasis.² Unfortunately, etiology of squamous cell carcinoma in oral cavity as well as in other

forms of carcinoma is still not known certainly. There are actually several stimulus factors playing a role in the incidence of oral cavity carcinoma, namely extrinsic and intrinsic factors. There is no specific factor that can be determined as a single carcinogen. Extrinsic factors are composed of external resources, such as exposure to cigarette, tobacco, alcohol, bacteria, viruses, chemicals and ultra violet.^{2,3}

Clinically, squamous cell carcinoma has several variations, such as exophytic and endophytic. Exophytic lesions typically have an irregular surface and papilla, as well as various color from normal to red with white

patches depended on the amount of keratin produced. The surface sometimes is ulcerated, and on palpation the tumor mass is hard. Endophytic lesions, on the other hand, are characterized by their curvature, irregular edges, ulceration, and elevated border (induration) with red mucosa and white patches. Destruction of the underlying bone can occur with a radiology overview in the form of mouth-eaten radiolucent with unsmooth edges.¹

Histopathologically, Broders (1920) classifies levels of carcinoma grading in the oral cavity into four levels, namely level I (well differentiated), level II (moderately differentiated), level III (poorly differentiated), and level IV (anaplastic). The most common incidences of squamous cell carcinoma in oral cavity are in lip inferior, lateral and ventral part of the tongue, and floor of the mouth, followed by the posterior part of the soft palate as well as tonsil area.

To confirm the diagnosis of squamous cell carcinoma, histopathological examination is required. Dysplasia rate will show the extent of cellular abnormalities, including increased mitotic figures, hyper-chromatics, and changes in normal cells as well as their maturation. Mild, moderate, and severe dysplasia will show epithelial abnormalities with many different levels. If an abnormality has involved the entire thickness of the epithelium, it can be diagnosed as an *in situ*-carcinoma. If the basement membrane is damaged and the invasion into the underlying connective tissue occur, it can be diagnosed as a carcinoma.

Prognosis in oral cavity squamous cell carcinoma, further depends on histopathological grading and clinical staging of the tumor. To enforce the histopathological grading, in addition based on histopathology differentiation, the earlier histopathological transformation can also be assessed.

p53 gene is a tumor suppressor gene that plays an important role in carcinogenesis. The role of wild-type p53 is very important in suppressing the formation of a malignancy. p53 also has many other important functions. p53 is a suppressor of tumor/ cancer progression through the response of cell cycle to DNA damage and by giving time to repair DNA prior to replication of genes, as well as the initiation of apoptosis in DNA damage that cannot be repaired anymore. It basically can be considered as a central monitor directing cells to provide a response in the form of termination of the cell cycle and apoptosis.^{4,5} p53 mutation mostly occurs in a malignancy, so earlier histopathological transformation can be seen by observing p53 mutation. This study aimed to determine correlation of p53 expressions and histopathological grading in oral cavity squamous cell carcinoma that can be an indicator of the prognosis.

MATERIALS AND METHOD

This study was a retrospective study. Samples used in this study were derived from paraffin blocks of oral squamous cell carcinoma examined at Department of

Pathology in Dr. Hasan Sadikin Hospital. In total, there were 20 cases of oral cavity squamous cell carcinomas selected and were stained with hematoxylin eosin for enforcing diagnosis and histopathological grading according to Broder's modification (grading I, II and III).

An immunohistochemical examination was performed using p53 monoclonal antibodies. Immunohistochemical examination on p53 can indicate mutant p53/ p53 mutation that leads to transformation of malignancy.^{4,5} p53 mutation then will extend its half-life by increasing the stability of the protein, so the tumor cells with p53 mutation will show positive immunoreactive p53 in the nucleus/ cytoplasm of the tumor cells. Immunohistochemical examination of the p53 protein in the tumor cells can also serve as an additional method to determine a correlation between the p53 genes and other tumor genes.⁶ p53 primary antibody DO-7 clone, M7001 (DAKO, Carpinteria, CA 93013, USA) can be used in immunohistochemical examination with streptavidin biotin peroxidase method. The results of the immunohistochemical staining can be indicated as positive ones if there is a brownish color expression in the nucleus and cytoplasm. The results of the staining then are compared to both of the positive control using a colon carcinoma that is known to be positive with p53 antibody and also the negative control.

p53 expressions were rated quantitatively and intensively. p53 expressions were quantitatively calculated at 1000 tumor cells in 10 representative visual fields by using a light microscope CX-21 (Olympus America Inc. Melville, NY 11747) with a magnification of 400x. In other words, p53 expressions were quantitatively categorized based on the percentage of positive tumor cells into score 1 if positive cells less than 25%, score 2 if positive cells between 25-50%, score 3 if positive cells between 51-75%, and score 4 if positive cells more than 75% with cut-off levels of <25% to >75%.^{3,7}

On the other hand, the intensity of p53 expressions are categorized based on color into score 1 for weak intensity (light brown), score 2 for moderate intensity (chocolate between score 1 and score 3), and score 3 for stronger intensity (dark brown).⁸ Based on the percentage and intensity of the p53 expressions, the values of p53 expressions were calculated by multiplying the percentage value of p53 expressions (score 1, 2, 3 or 4) with the intensity of the p53 expressions (score 1, 2 or 3). As a result, the values of p53 expressions obtained were in a range of 1-12, correlated later with histopathological grading for squamous cell carcinoma. Data obtained then were statistically tested using correlation-regression test.

RESULTS

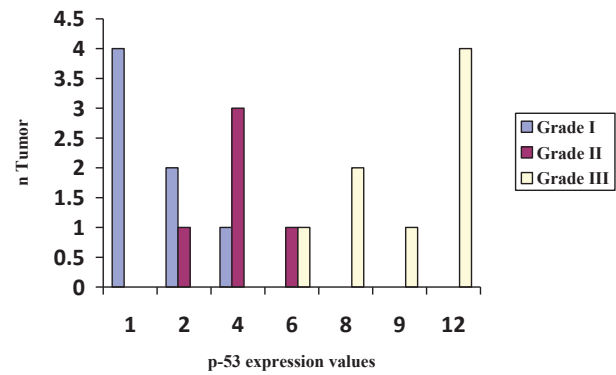
Of the 20 sample cases of squamous cell carcinomas, there were eight (8) males and twelve (12) females with a mean age of 49 years old. The location of tumors was various, namely, 8 cases in tongue, 5 cases in gingival area,

Table 1. Characteristics of patients with oral squamous cell carcinoma

Variables	n (%)
Median of age (years)	
<49	4 (20%)
>49	16 (80%)
Sex	
Males	8 (40%)
Females	12 (60%)
Location	
Tongue	8 (40%)
Gingival area	5 (25%)
Buccal area	2 (10%)
Base of tongue	4 (20%)
Palate	1 (5%)

2 cases in buccal area, 4 cases in the base of tongue, and 1 case in palate (Table 1). Grade I squamous cell carcinoma was found in 7 cases, grade II in 5 cases, and grade III in 8 cases. The number of tumor cells with immunoreactive p53 was also various from <25% to >75%, namely, <25% in 5 cases, 25-50% in 5 cases, 51-75% in 4 cases, and >75% in 6 cases. Similarly, the color intensity of the p53 expressions was various, weak intensity in 4 cases, moderate intensity in 11 cases, and stronger intensity in 5 cases (Table 2).

Based on the quantity and intensity of p53, the values of p53 expressions then were calculated by multiplying the quantity of p53 expressions with the intensity of p53 expressions. The values of p53 expressions obtained were between 1-12, consisted of score 1 in 4 cases, score 2 in 3 cases, score 4 in 4 cases, score 6 in 2 cases, score 8 in 2 cases, score 9 in 1 case, and score 12 in 4 cases. Next, those scores were correlated with histopathological grading of oral squamous cell carcinoma (Table 3) and (Figure 1).

**Figure 1.** Graph of p53 expression values.

Based on the results of the statistical analysis using a correlation-regression test, there was no correlation between p53 expressions and histopathological grading I, II, and III as a whole. Nevertheless, there was a very significant correlation between p53 expressions and histopathological grading I ($p < 0.01$).

DISCUSSION

Squamous cell carcinoma is a malignancy in oral cavity found mainly at the age of 45 years often associated with various risk factors, such as smoking and drinking alcohol in addition to other extrinsic factors. However, many cases of squamous cell carcinoma lately are also found in young adults associated with those risk factors.³ Squamous cell carcinoma in oral cavity will have a poor prognosis when found in an advanced stage, in which most patients die within 5 years after the enforcement of diagnosis.³ Prognosis of oral cavity squamous cell carcinoma actually depends on histopathological grading and clinical staging of

Table 2. Expression and intensity of p53 in histopathological grading of squamous cell carcinoma

Histopathological grading	Expression		Intensity							p
	n	<25%	26-50%	51-75%	>75%	Weak	Medium	Strong		
Grade I	7	4	2	1	-	4	3	-	<0.01	
Grade II	5	1	3	1	-	-	5	-		
Grade III	8	-	-	2	6	-	3	5		

Table 3. The correlation between the scores of p- 53 expressions and histopathological grading of oral squamous cell carcinoma

Histopathological grading	Scores of p53 expressions								Total	p
	1	2	3	4	6	8	9	12		
Grade I	4	2	-	1	-	-	-	-	7	<0.01
Grade II	-	1	-	3	1	-	-	-	5	
Grade III	-	-	-	-	1	2	1	4	8	

the tumor.^{1,2} To enforce the histopathological grading, in addition based on histopathological differentiation, histopathological transformation found early can be observed by using immunohistochemical examination. Immunohistochemical examination has been widely used to evaluate and analyze the role of various markers in predicting prognosis of squamous cell carcinoma.^{9,10}

p53 gene is a tumor suppressor gene that plays an important role in carcinogenesis. Normally, p53 genes regulate cell cycle from G1 phase to S phase. Increasing concentrations of wild-type p-53, consequently, will inhibit the cells in the G1 phase into the S phase during cell cycle by activating protein p-21 which will inhibit the function of cycling -dependent kinase enzyme, resulting in terminating the cell cycle, inhibiting cell growth, preventing duplication and replication of damaged DNA, and allowing for DNA repair. In other words, the roles of wild-type p53 are very important in suppressing the formation of a malignancy. Wild-type p53 also has many other important functions, namely as a suppressor of tumor/ cancer progression through the response of cell cycle to DNA damage and by giving time to repair DNA prior to replication of genes, as well as the initiation of apoptosis in DNA damage that cannot be repaired anymore, as a result, it basically can be considered as a central monitor that directs cells to provide a response in the form of termination of the cell cycle and apoptosis.^{4,5} If p53 mutation occurs, p53 will lose its function in regulating the cell cycle and apoptosis resulting in transformation and progression of malignancy. p53 mutation is one thing that most often occurs in a malignancy, so earlier histopathological transformation can be observed by looking at the p53 mutation.

p53 mutation has been widely used as markers in a variety of malignancies, including in oral cavity squamous cell carcinoma.¹¹ Based on various researches that have been conducted, there were different correlation found between p53 expressions and histopathological grading in predicting prognosis.^{12,13} For instance, a research on 76 cases of squamous cell carcinoma in larynx conducted by Luo *et al.* shows a significant correlation between p53 expressions and histopathological grading I, II and III. Similarly, Ashraf *et al.* also shows that p53 expressions can predict prognostic in squamous cell carcinoma in larynx.² Unlike the previous researches, the researches show that there is no significant correlation between p53 expressions and histopathological grading I, II and III.^{10,13-15}

For those reasons, this study aimed to determine the role of p53 in immunohistochemistry as well as the correlation between p53 expressions and histopathological grading in oral cavity squamous cell carcinoma. In all 20 cases of squamous cell carcinoma classified by grading I, II and III, there was no correlation between p53 expressions and histopathological grading in those three groups as a whole. Nevertheless, there was a highly significant correlation between p53 expressions and histopathological grading I ($p < 0.01$). This finding is consistent with a research conducted

by Rodrigues *et al.* showing that there is no correlation between immunohistochemical p53 and histopathological grading in predicting prognosis for 30 cases of squamous cell carcinoma of larynx.¹³ Similarly, another research conducted by Motta *et al.*¹⁰ also shows that there is no significant correlation between p53 and histopathological grading in predicting prognosis for 28 cases of squamous cell carcinoma of oral cavity.

Therefore, it can be argued that p53 expressions possibly play a role at the beginning of the occurrence of malignant transformation. p53 mutation occurs as an initial change of a mutation to malignancy of oral cavity, such as dysplasia and leukoplakia.^{16,17} Although the overall p53 expressions in this research were not statistically correlated with histopathological grading, there were greater distribution of high expression (6 cases) and strong intensity (5 cases) in histopathological grading III. It means that p53 expressions in those squamous cell carcinoma cases of oral cavity were correlated with a poor prognosis (grade III). This finding is in accordance with an opinion of Motta *et al.*¹⁰ stating that there is a correlation between p53 and a poor prognosis in oral cavity squamous cell carcinoma. p53 expressions in grading I indicates a highly significant correlation ($p < 0.01$) due to the low expression distribution (4 cases) and the weak intensity (4 cases) on histopathological grading I. This is possibly because of p53 mutation has a longer half-life, mostly found in a change/ occurrence of a malignancy. However, p53 mutation is not correlated with increased histopathological grading since p53 mutation emerges in the early stage of change into malignancy. This is in accordance with an opinion of Khanna *et al.* stating that p53 mutation is considered as an initial change of a mutation to malignancy of oral cavity, such as dysplasia and leukoplakia.^{11,13,16,17}

It can be concluded that there was no correlation between p53 expressions and histopathological grading in oral cavity squamous cell carcinoma. p53 cannot be used to predict prognosis, but p53 expressions in this research still can be considered as a part of the pathogenesis and development of a malignancy.

REFERENCES

1. Ghali GE, Larsen PE, Waite PD. Peterson's principles of oral and maxillofacial surgery. 2nd ed. Hamilton, London: BC Decker Inc; 2004. p. 617-71.
2. Regezi JA, Sciubba JJ, Jordan RCK. Oral pathology: clinical pathologic correlations. 5th ed. St Louis, Missouri: Elsevier; 2008. p. 48-71.
3. Chandra A, Singh A, Sebastian BT, Agnihotri A, Bali R, Verma PK. Oral squamous cell carcinomas in age distinct population: A comparison of p53 immunoexpression. J Can Res Ther 2013; 9: 587-91.
4. Maiuri MC, Galluzzi L, Morselli E, Kepp O, Malik SA, Kroemer G. Autophagy regulation by p53. J Curr Opin Cell Biol 2010; 22: 181-5.
5. Levine B, Abrams J. p53: The Janus of autophagy? J Nat Cell Biol 2008; 10: 637-9.

6. Kasakov DV, Grossmann P, Supagnolo DV, Vanecek T, Vazmitel M, Kacerovska D. Expression of p53 and TP53 mutational analysis in malignant neoplasms arising in preexisting spiradenoma, cylindroma, and spiradenocylindroma, sporadic or associated with Brooke-Spiegler syndrome. *Am J Dermatopathol* 2010; 32: 215-21.
7. Barcones-Martinez A, Rodriguez-Gutierrez C, Rodriguez-Gomez E, Gilmontoya J.A., Gomez-Font R, Gonzalez-Moles MA. Evaluation of p53, Caspase-3, Bcl-2, and Ki-67 markers in oral squamous cell carcinoma and premalignant epithelium in a sample from Alava Province (Spain). *J Med Oral Patol Oral Cir Bucal* 2013; 18(6): ne846-e850.
8. Humayun S, Ram Prasad V. Expression of p53 protein and ki-67 antigen in oral premalignant lesions and oral squamous cell carcinoma: An Immunohistochemical study. *Natl. J Maxillofac Surg* 2011; 2(1): 38-46.
9. Li L, Fukumoto M, Liu D. Prognostic significance of p53 immunorexpression in the survival of oral squamous cell carcinoma patients treated with surgery and neoadjuvant chemotherapy. *Oncology Letters* 2013; 6(6): 1611-5.
10. Motta RDR, Zettler CG, Cambruzzi E, Jotz GP, Berni RB. Ki-67 and p53 correlation prognostic value in squamous cell carcinomas of the oral cavity and tongue. *Braz J Otorhinolaryngol* 2009; 75(4): 1-11.
11. Sassi LM, Loshii SO, Oliveira BV, Pedruzzi PA, Guerbur M, Schussel JL, Stramandinoli RT, Ramos GH, Orlandi D, Fukuda E, Cervantes O. Second primary tumor: P53 and Ki-67 expression in patients with oral squamous cell carcinoma. *webmedCentral CANCER* 2011; 2(3): 2-8.
12. de Oliveira LR, Ribeiro-Silva A, Zucoloto S. Prognostic impact of p53 and p63 immunorexpression in oral squamous cell carcinoma. *J Oral Pathol Med* 2007; 36(4): 191-7.
13. Rodrigues RB, Da Ros Motta R, Dos Santos Macbado SM. Prognostic value of the immunohistochemistry correlation of Ki-67 and p53 in squamous cell carcinomas of the larynx. *Bras Otorrinolaringol* 2008; 74(6): 855-9.
14. Luo K, wang Z, wang N, Zhang X, Yang J. Effect of expression of p53 in squamous cell carcinoma of larynx and mucosa adjacent in tumor on the biological behavior. *Lin Chuang Er Bi yan hou ke za Zhi* 2005; 19(9): 405-8.
15. Micozkadioglu D, Unal M, Pata YS, Basturk M, Cinel L. Prognostic value of expression of p53, proliferating cell nuclear antigen, and c-erbB-2 in laryngeal carcinoma. *Met Sci Monit* 2008; 14(6): 299-304.
16. Khanna R, Vidhyarthi AK, Khanna S, Singh U, Singh UC. Expression of p53 protein in leukoplakia and oral squamous cell carcinoma. *World Journal of Surgical Medical and Radiation Oncology* 2012; 1: 16.
17. Ashraf MJ, Maghbul M, Azarpira N, Khademi B. Expression of Ki67 and P53 in primary squamous cell carcinoma of the larynx. *Indian Journal of Pathology & Microbiology* 2010; 53(4): 661-5.