

The possibility of polymorphonuclear leukocyte activation in dental socket healing by freeze-dried Aloe vera induction

Pratiwi Soesilawati, Ester Arijani Rachmat, Ira Arundina and Nita Naomi
Department of Oral Biology,
Faculty of Dental Medicine, Universitas Airlangga,
Surabaya – Indonesia

ABSTRACT

Background: Research has proved that Aloe vera has anti-inflammatory, anti-bacterial, and immunomodulator properties that can accelerate the healing process. These properties could be beneficial in the tooth extraction wound-healing process. Neutrophils are the first inflammatory cells to invade and are the predominant cell markers in the wound for 24 hours after injury. Polymorphonuclear leukocytes (PMN) provide initial protection against micro-organisms, as they engulf and digest foreign bodies. **Purpose:** The aim of this study was to prove the effect of Aloe vera 90% gel application on the PMN count in the healing process of *Cavia cobaya* following tooth extraction. **Methods:** This laboratory experimental research was done using Post-Test Only Control Group Design. The lower incisive of twelve male *Cavia cobayas* were extracted then divided into four groups. Group P1 and P3 had 90% Aloe vera gel applied into the socket and sutured; group K1 and K3, received no 90% Aloe vera gel application and acted as controls. Samples from group P1 and K1 were terminated and had their mandibula taken one day after tooth extraction, and those from group P3 and K3 were terminated after three days. Tissues were then processed into histology slides, and PMN cells were counted. **Results:** There were significant differences in the PMN count between groups K1, P1, and K3 compared with P3 ($p < 0.05$). Higher PMN count was shown on the group containing Aloe vera 90% gel compared with control group, both on day one and three after tooth extraction. **Conclusion:** Aloe vera 90% gel can increase the PMN count in the inflammation phase of the tooth extraction wound-healing process.

Keywords: Aloe vera 90% gel; PMN count; tooth extraction; wound healing

Correspondence: Pratiwi Soesilawati, Department of Oral Biology, Faculty of Dental Medicine, Universitas Airlangga, Jl. Mayjen Prof. Dr Moestopo 47 Surabaya, 60132 Indonesia. Email: pratiwi-s@fkg.unair.ac.id

INTRODUCTION

Tooth extraction is the removal of a tooth, which creates a wound in its socket. Post-extraction wounds normally go through a healing process, but sometimes complications can slow down this process. Some research stated that post-extraction wounds treated by the use of various natural products, such as Aloe vera, can minimise the risk of complications and promote wound healing because of their therapeutic properties.¹

Wound healing is a complex phenomenon. Immediately after injury, extravasated blood constituents form a hemostatic plug. The inflammatory stage is the first attempt of the repair process, and corresponds to the proliferation and remodelling stage that constitutes wound healing.

The process begins with the infiltration of leukocyte, as a primary cellular component of inflammation response in the wound area.²

Neutrophils are the first type of white blood cell to be attracted into the wound within a few hours and are the predominant cell marker in the injury site for 24 hours after injury. Polymorphonuclear leukocyte (PMN) provides initial protection against micro-organisms, as they engulf and digest foreign bodies. After two to three days, mature and senescent PMNs undergo apoptosis and phagocytosis, which is then cleared locally by tissue phagocytes, such as macrophage.^{3–5}

Additional PMN cell functions that contribute to tissue restoration by promoting angiogenesis and cell proliferation are important in the wound-healing process. These functions

have also been uncovered in tumours, sterile inflammation and ischemic injury. PMN cell functions are impaired in patients with chronic diseases associated with compromised healing, such as diabetes. The use of a substance that can improve PMN cells will significantly help the wound-healing process for people with this condition.⁶

The Aloe plant consists of more than 360 species, with the most commonly used being the Aloe vera species (*Aloe barbadensis* Miller). Research involving cytotoxic tests of variable concentrations of Aloe vera against fibroblast cell culture shows that a concentration of Aloe vera 90% is nontoxic against fibroblast cell culture.⁷ The research result states that Aloe vera promotes wound healing by improving cell regeneration and increasing the number of phagocytic cells, that it has a hypoglycemic effect, is anti-inflammatory, anti-bacterial, anti-viral, anti-fungal, and is an immunomodulator.^{8,9}

Aloe vera contains mannose-6-phosphates, chromones, β -sitosterol, and bradykinase as an anti-inflammation agent. Acemannan, which is derived from Aloe vera, is an immunomodulator that stimulates various cytokines and growth factors in the wound-healing process. This property of Aloe vera might impact on the PMN count through a vascular (vasodilatation/vasoconstriction), immunomodulator, and anti-inflammation effect during the inflammation phase in the wound-healing process following tooth extraction.^{9,10} The purpose of this research is to prove the effect of Aloe vera 90% gel application on the PMN count in the wound-healing process following tooth extraction of *Cavia cobaya*.

MATERIALS AND METHODS

This was a laboratory experimental research with posttest only control group design. Twelve healthy male samples of *Cavia cobaya*, weight 300–500-gram, age 2–3 months old, were used for right mandibular incisive extraction. Samples were divided into four groups (P1, P3, K1, K3). Groups P1 and P3 were the experimental groups, in which Aloe vera 90% gel was applied and sutured in the post-extraction socket. Groups K1 and K3 were the control groups in which Aloe vera 90% gel was not applied in the post-extraction socket. Samples from groups P1 and K1 were terminated one day after tooth extraction; those in groups P3 and K3 were terminated three days after the extraction.

Aloe vera (*L.*) Webb species were used in this research. They underwent freeze drying and were dissolved with sodium carboxymethyl cellulose (CMC-Na) to form a gel with 90% concentration. The right mandibular incisive was carefully extracted using a needle holder and elevator, and the socket was irrigated with sterile aquadest. *Cavia cobaya* was then euthanised with a lethal dose of 10% ether. The mandibula was separated from its joint and, for the fixation process, was first put into formalin buffer 10% solution for 24 hours at -80°C , then underwent decalcification using a nitric acid solution for 48 hours. After the mandibular

bone had softened, the lower right incisor region was cut into rectangular pieces and put into formalin buffer 10% solution for 24 hours at -80°C . The remaining tissue was thinly sliced into $1 \times 1 \times 1/2$ cm, then was dehydrated, cleared, embedded, blocked, sectioned into 5–7 micron width, and stained with Haematoxylin and Eosin solution so the specimen could be analysed histopathologically.¹¹

The histology slide was then put under an Olympus Microscope BX53 and Olympus Camera DP73, which had a sensor that was connected to the computer with Cell Sens imaging system software. The magnification was set to 40x, and the resulting image were shown on a computer screen with live mode action, operating the microscope to get a clear field of PMN and its features. The snapshot feature was then used to get an exact photo of recognised PMN, then the Cell D imaging system by Olympus was used to count the PMN automatically, and the results were ready to be analysed.¹² The data was statistically processed using the Kruskal-Wallis and post hoc (Tukey HSD) test ($p < 0.05$).

RESULTS

There is a PMN count difference between the experimental and control group, with a higher PMN count in the experimental group on day one (P1) and day three (P3), as shown in Figure 1. Table 1 shows the PMN count of the control group on day one (K1), the experimental group on day one (P1), the control group on day three (K3), and the experimental group on day three (P3). *Aloe vera's* ability to inhibit PMN infiltration on day three is discovered by counting the PMN mean percentage between groups shown by the following equation:

$$\frac{(\text{mean differential between day one and three})}{\text{mean day one}} \times 100\%$$

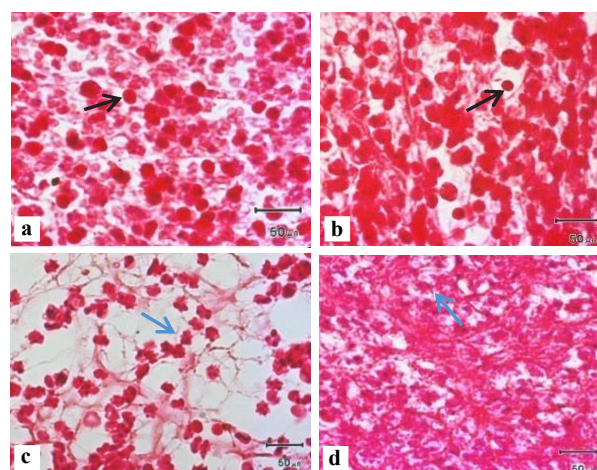


Figure 1. Histopathology specimen a) Control group day one (K1), b) Experimental group day one (P1), c) Control group day three (K3), and d) Experimental group day three (P3). Black arrows show whole and rounded PMN cells, while blue arrows show PMN shrinkage with cytoplasmic projections.

Table 1. PMN count by histopathological examination

Group	Cell count	Mean	Standard deviation
K1	6	4	2 ± 0.175
	4		
	2		
P1	17	17	1 ± 0.175
	18		
	16		
K3	15	18.33	3.05 ± 0.253
	19		
	21		
P3	40	66.33	22.85 ± 0.362
	78		
	81		

Table 2 shows that the increase in percentage of mean PMN count in the experimental group is less than in the control group, so the experimental group has a stronger ability to inhibit PMN infiltration compared with control group. The post hoc (Tukey HSD) test was then used to compare the 4 groups of variables, and the results can be seen in Table 3. Group K1 and P3 ($p = 0.001$), P1 and P3 ($p = 0.004$), K3 and P3 ($p = 0.004$) have a p score < 0.05 , showing there is a significant difference in the PMN count. Group K1 and P1 ($p = 0.547$), K1 and K3 ($p = 0.472$), P1 and K3 ($p = 0.999$) show no significance of PMN count difference.

DISCUSSION

Post extraction-socket wound healing starts with thrombus formation that stimulates PMN infiltration to the wound site.¹³ PMN then undergo apoptosis and phagocytic clearance by macrophage, and are replaced with macrophage and other mononuclear leukocytes on day two or day three.^{2,5}

The PMN count of the control (K1) and experimental group (P1) on day one was less than on day three (Table 1), while the theory stated that extravasated neutrophils influx after wounding increased most rapidly over the initial 12 hours and reached a maximum value between day one and two, with the level plateauing up to day three, and decreasing precipitously on day five.¹⁴ This might be caused by the PMN count on day three having included apoptotic PMN, which had not undergone phagocytic clearance by macrophages. In Figure 1, on day three, both group K3 and P3 showed some PMN cells still in an apoptotic state (blue arrows show PMN with cytoplasmic projections). Another cause for the higher PMN count on day three is the up-regulated anti-apoptotic genes, immediate early response gene X-1 (IEX1) also known as immediate early response 3 (IER3) and BCL2 related protein A1 (BCL2A1) defined as target genes of nuclear factor κ B (NF- κ B), a transcription factor that is activated through interleukin 1 beta (IL-1 β)

Table 2. Increased percentage of mean PMN cell number between control and experimental group

Control group	$\frac{(18.33 - 4)}{4} \times 100\%$	= 358.25%
Experimental group	$\frac{(66.33 - 17)}{17} \times 100\%$	= 290.18%

Table 3. Tukey HSD test result between control group and experimental group

Sig.	K1	P1	K3	P3
K1		0.547	0.472	0.001*
P1			0.999	0.004*
K3				0.004*
P3				

and tumour necrosis factor alpha (TNF- α) signalling. Because macrophages and PMNs both produce IL-1 β and TNF- α at sites of infection, it might be responsible for the inhibition of normal cell apoptosis.¹⁵

The normal process of engulfment of apoptotic neutrophils by tissue phagocytes triggers anti-inflammatory signals, which decrease their production of interleukin 23 (IL-23), a key cytokine for the induction of interleukin 17 (IL-17) by both innate and adaptive immune cells. The resulting inhibition of IL-17 production, in turn, leads to decreased production of granulocyte-colony stimulating factor (G-CSF) by cells such as fibroblasts, thereby limiting stimulus for neutrophils production to maintain steady-state neutrophil counts.⁵ Another possibility is described by a research of full thickness skin burn on rats treated by Aloe vera 95% gel, which shows there was a significant decrease of PMN infiltration in the granulation tissue that appeared at the base of the burnt area detected on day four.¹⁶

The PMN count on day one of the experimental group (P1) is higher than the control group (K1) (Figure 1). Pure Acemannan isolated from Aloe vera leaves have hematopoietic activity by stimulating macrophages to release GM-CSF, thus increasing cell numbers and improving PMN function.⁹ GM-CSF is a monomeric glycoprotein secreted by macrophage and other cells, which functions as a growth factor of white blood cells, and stimulates stem cells to produce granulocytes that include neutrophils.¹⁷

Some research stated that polysaccharides (mannan, mannose, galactose, β -glucans) have hematopoietic activity linked with specific carbohydrate receptors that mediate the binding between hematopoietic progenitor stem cells and the stroma. Study has shown that PPG-Glucan improves hematopoietic cells' mobilisation towards the peripheral area to release progenitor cells, which increase the amount of spleen GM-CSF. Another study, that uses pure polymannan (>99%) shows a significant expansion of progenitor cells in the spleen.¹⁰

Other content of Aloe vera is glycoprotein fraction (14kDa) which synthesises less Thromboxane A2

(TxA2) in *in vitro* analysis.¹⁶ TxA2 produced by active platelets has a vasoconstrictor effect and plays an important role in wound healing and the inflammation process. Decreased TxA2 synthesis causes vasodilatation and thus accelerates PMN extravasated to the wound site.¹⁸

The PMN count on day three of experimental group (P3) was higher than the control group (K3) (Figure 1), but the percentage of increasing cells number was lower than the control group (Table 2). On day three, PMN cells became apoptotic and were cleared by macrophages. This downward pattern of PMN cells confirmed that there was no prolonged inflammatory response.¹⁹ This clearance process was also marked by the release of the tissue-repairing cytokines, transforming growth factor- β (TGF β) and interleukin-10 (IL-10), which initiates tissue repair. Thus, substances that promote PMN cells' apoptosis have a therapeutic potential to accelerate wound healing and tissue repair.²⁰

Aloe vera contains amino acid (phenylalanine, tryptophane) and salicylic acid, which inhibit PGE2 synthesis from arachidonic acid, which inhibits vasodilatation and inflammatory mediator effect (histamine, serotonin), and thus has the ability to inhibit PMN infiltration to the wound site.¹⁸ Another research stated that chromones component (C-glucosyl chromone) isolated from Aloe vera can inhibit the cyclooxygenase (COX) cycle and lower PGE2 production.¹⁶

Aloe vera contains bradykinase, which can break down the bradykinin compound. Bradykinin is an inflammation mediator that causes vasodilatation. Hydrolysis of bradykinin can reduce the vasodilatation effect, which causes an inhibition of leukocyte infiltration.²¹

Gibberellins from Aloe vera have an anti-inflammatory effect by inhibiting the COX cycle during the inflammation phase, which inhibits PMN infiltration. *In vivo* analysis of diabetes-induced rats show that Aloe vera has an active component similar to gibberellin, which can lower the amount of PMN infiltration up to 60.1%.²²

This research has proved a differential count of PMN in the inflammation phase. The experimental groups treated by Aloe vera 90% gel show a significant increase in PMN count compared with control group in the tooth extraction wound-healing process.

ACKNOWLEDGEMENTS

We thank Lita Rakhma Yustinasari, drh and Suryo Kuncorojakti, drh for the preparation and processing supported by Faculty of Veterinary Medicine, Airlangga University. This study was also supported by Dana Riset Kolaborasi Dosen Mahasiswa, Faculty of Dental Medicine, Airlangga University. The authors declare no potential conflicts of interest with respect to the authorship and/or publication of this article.

REFERENCES

- Nimma VL, Talla HV, Bairy JK, Gopaldas M, Bathula H, Vangdoth S. Holistic healing through herbs: effectiveness of Aloe vera on post extraction socket healing. *J Clin Diagnostic Res.* 2017; 11(3): ZC83–6.
- Gonzalez AC de O, Costa TF, Andrade Z de A, Medrado ARAP. Wound healing - A literature review. *An Bras Dermatol.* 2016; 91(5): 614–20.
- Wang J. Neutrophils in tissue injury and repair. *Cell Tissue Res.* 2018; 371(3): 531–9.
- Nanci A. Ten Cate's oral histology: development, structure, and function. 8th ed. St Louis: Mosby Elsevier; 2012. p. 379–83, 388–9.
- Hajishengallis E, Hajishengallis G. Neutrophil homeostasis and periodontal health in children and adults. *J Dent Res.* 2014; 93(3): 231–7.
- Phillipson M, Kubes P. The healing power of neutrophils. *Trends Immunol.* 2019; 40(7): 635–47.
- Sumarta NPM, Danudiningrat CP, Rachmat EA, Soesilawati P. Cytotoxicity difference of 316L stainless steel and titanium reconstruction plate. *Dent J (Majalah Kedokt Gigi).* 2011; 44(1): 7–11.
- Hashemi SA, Madani SA, Abediankenari S. The review on properties of Aloe vera in healing of cutaneous wounds. *Biomed Res Int.* 2015; 2015: 714216.
- Cock IE. Problems of reproducibility and efficacy of bioassays using crude extracts, with reference to Aloe vera. *Pharmacogn Commun.* 2011; 1(1): 52–62.
- Sierra-García GD, Castro-Ríos R, González-Horta A, Lara-Arias J, Chávez-Montes A. Acemannan, an extracted polysaccharide from Aloe vera: A literature review. *Nat Prod Commun.* 2014; 9(8): 1217–21.
- Yuliati, Kusumaningsih T, Rananda I, Soesilawati P. Increasing macrophages in tooth extraction wound healing after induction of freeze-drying gel Aloe vera 90% on *Cavia cobaya*. *Malaysian J Med Heal Sci.* 2020; 16(4): 87–91.
- Olympus Corporation. User manual cellSens 1.18 life science imaging software. Tokyo: OLYMPUS; 2017. p. 7–39, 139–75.
- Cross SS. Underwood's pathology: a clinical approach. 6th ed. China: Churchill Livingstone Elsevier; 2013. p. 179–80.
- Reinke JM, Sorg H. Wound repair and regeneration. *Eur Surg Res.* 2012; 49(1): 35–43.
- Wilkinson HN, Hardman MJ. Wound healing: cellular mechanisms and pathological outcomes. *Open Biol.* 2020; 10(9): 200223.
- Abdel Hamid AA, Soliman MF. Effect of topical aloe vera on the process of healing of full-thickness skin burn: a histological and immunohistochemical study. *J Histol Histopathol.* 2015; 2: 3.
- Francisco-Cruz A, Aguilar-Santelises M, Ramos-Espinosa O, Mata-Espinosa D, Marquina-Castillo B, Barrios-Payan J, Hernandez-Pando R. Granulocyte-macrophage colony-stimulating factor: not just another haematopoietic growth factor. *Med Oncol.* 2014; 31(1): 774.
- Jamil M, Mansoor M, Latif N, Naz R, Anwar F, Arshad M, Gul J, Ullah S, Saddam M. Review: Effect of Aloe vera on wound healing. *Pakistan J Sci Ind Res.* 2020; 63(1): 48–61.
- Kamadajaja DB, Harijadi A, Soesilawati P, Wahyuni E, Maulidah N, Fauzi A, Rah Ayu F, Simanjuntak R, Soesanto R, Asmara D, Rizqiawan A, Agus P, Pramono C. Demineralized freeze-dried bovine cortical bone: Its potential for guided bone regeneration membrane. *Int J Dent.* 2017; 2017: 5149675.
- Haque N, Widera D, Govindasamy V, Soesilawati P, Abu Kasim NH. Extracellular vesicles from stem and progenitor cells for cell-free regenerative therapy. *Curr Mol Med.* 2021; 21.
- Gupta VK, Malhotra S. Pharmacological attribute of Aloe vera: Revalidation through experimental and clinical studies. *Ayu.* 2012; 33(2): 193–6.
- Choche T, Shende S, Kadu P. Extraction and identification of bioactive components from Aloe barbadensis. *J Pharmacogn Phytochem.* 2014; 2(1): 14–23.