

# Effect of mangosteen peel extract combined with demineralized freeze-dried bovine bone xenograft on osteoblast and osteoclast formation in post tooth extraction socket

Utari Kresnadi, Yurike Hadisoianto, and Harly Prabowo

Department of Prosthodontics  
Faculty of Dental Medicine, Universitas Airlangga  
Surabaya - Indonesia

## ABSTRACT

**Background:** Tooth extraction, a common procedure in dentistry, can cause bone resorption during socket healing. Therefore, it is important to perform socket preservation procedure to maintain alveolar bone. Providing a combination of mangosteen peel extract with demineralized freeze-dried bovine bone xenograft (DFDBBX) in tooth extraction socket was expected to accelerate alveolar bone formation. **Purpose:** This study aims to determine the effect of mangosteen peel extract combined with DFDBBX introduced into the socket of post tooth extraction on the formation of osteoblasts and osteoclasts. **Method:** Twenty-eight (28) *Cavia cobaya* were divided into four groups. Extraction to the lower left incisor of *Cavia cobaya* was performed. The extraction socket was filled with 25 gram of PEG (group I) as a control, active materials consisted of mangosteen peel extract and DFDBBX 0.5% (group II), active materials consisted of mangosteen peel extract and DFDBBX 1% (group III), and active materials consisted of mangosteen peel extract and DFDBBX 2% (group IV). After thirty days, those *Cavia cobaya* were sacrificed. By using HE on histopathological examination, the number of osteoblasts and osteoclasts were measured by light microscope with 400 times of magnification. The statistical analysis was then performed using one-way Anova & Tukey HSD test. **Result:** The component active materials consisted of mangosteen peel extract and DFDBBX 2% had the most significant results related to the formation of osteoblasts and osteoclasts. **Conclusion:** Mangosteen peel extract combined with DFDBBX can increase osteoblasts and decrease osteoclasts in the socket of tooth extraction in *Cavia cobaya*. The combination of mangosteen peel extract and DFDBBX 2% is the most effective material in increasing osteoblast and decreasing osteoclast.

**Keywords:** DFDBBX; mangosteen peel extract; osteoblast; osteoclast

**Correspondence:** Utari Kresnadi, Department of Prosthodontics, Faculty of Dental Medicine, Universitas Airlangga. Jl. Mayjend. Prof. Dr. Moestopo no. 47 Surabaya 60132, Indonesia. E-mail: ut.kres@yahoo.com

## INTRODUCTION

Tooth extraction is a common procedure performed in the field of dentistry. Tooth extraction followed socket healing process usually leads to alveolar bone deformities, including the reduction of residual ridge height and width. Poor bone healing pattern will then cause problems for dentists, especially related to aesthetic problems in the manufacture of dental implants or conventional prostheses as well as in the placement of dental implants.<sup>1</sup> Therefore,

it is important to perform socket preservation procedures to maintain alveolar bone.

One of socket preservation procedures is to put a bone graft in the socket immediately after tooth extraction.<sup>2</sup> One of bone graft materials used is demineralized freeze-dried bovine bone xenograft (DFDBBX). DFDBBX are often used due to their osteoconductive inorganic matrix components, which serve to provide scaffold for bone regeneration without getting involved in bone formation

itself. However, the bone graft healing process is a complex process involving many factors, such as bone metabolism, hormonal balance changes, and external factors for a long time.<sup>3</sup> Thus, an innovative material is needed to induce osteogenesis activity in order to accelerate bone formation.

In the current technological development, a lot of various natural materials has been used to assist or accelerate the wound healing process. One of them is mangosteen (*Garcinia mangostana L.*). The results of previous researches showed that mangosteen is rich of nutrients, namely xanton that are abundant in the peel. The functions of xanton in human body are as anti-oxidant, anti-proliferation/anti-cancer, anti-inflammatory, anti-microbe, anti-histamine, anti-fungus, heart disease treatment, HIV treatment, and sugar blood-lowering.<sup>4</sup> In the previous research on toxicity test of mangosteen peel extract, mangosteen extract at certain concentration, from 200 µg/ml to 800 µg/ml, is not toxic to gingival cell cultures of human fibroblasts.<sup>5</sup>

During tooth extraction, trauma may occur which will lead to inflammation. Inflammation will cause the infiltration of inflammatory cells, including macrophages, to the traumatized area. As a result, it will activate pro-inflammatory cytokines, such as IL-1, TNF- $\alpha$ , and PGE. IL-1 and TNF- $\alpha$  in this case can trigger production of RANKL and binding of RANKL in RANK receptor on the surface of the pre-osteoblasts that can lead to activation of NF- $\kappa$ B triggering the formation of osteoclasts, while PGE plays a role in vascular changes, and when injected into bone surfaces, it can cause bone resorption.<sup>6,7</sup> Therefore, this research aims to determine the effect of the combination of mangosteen peel extract and DFDBBX on the number of osteoblasts and osteoclasts in tooth extraction sockets.

## MATERIALS AND METHODS

This research is an experimental research with randomized factorial design (true eksperimental design). This research also has already passed Eligible Ethics from the Ethics Committee of Faculty of Dental Medicine, Universitas Airlangga with number 44/KKEPK.FKG/IV/2015. Subjects in this research were male cavia cobayas weighed 300-350 g and aged 3-3.5 months. Those animals were healthy and active, had normal appetite, body temperature and five senses, and suffered no injuries in the limbs and skin as well as no deformed limbs or limp, as well as normal body temperature. Those animals were obtained from the test animal unit of Biochemistry laboratory, Faculty of Medicine, Universitas Airlangga.

Materials used were mangosteen peel extract, distilled sterile, DFDBBX produced by Batan with a size of 10 mesh/2000 microns, polyethilen glycol suspension (PEG) 400 and 4000, 100 mg of ketamine, Blue Nylon 5-0 non cutting sewing thread, sterile cotton, alcohol absolute 99%, 95%, 90%, 80%, and 70%, reagent for haemotoxilin eosin

(HE) staining, formalin buffer 10%, paraffin solution, ethanol 96%, xylol, ethilen diamine tetra acetate (EDTA), and HE dye. The research was conducted in several places, namely Biology Laboratory in Faculty of Science and Technology for identifying mangosteen peel; laboratory of Research and Industry Consultation in Research & Industry Consultation Unit, Surabaya for manufacturing mangosteen peel extract; Chemical Analysis Laboratory of Pharmacy Faculty, Universitas Airlangga for mixing mangosteen peel extract, DFDBBX, and PEG; Biochemistry Laboratory of Faculty of Medicine, Universitas Airlangga for preparing and treating *Cavia cobaya*; Anatomical Pathology Laboratory of Hospital Dr. Soetomo for preparing preparations; and Biochemistry and Biomolecular Engineering Laboratory of Faculty of Medicine, Universitas Brawijaya for observing and measuring the number of osteoblasts and osteoclasts.

Twenty-eight (28) *Cavia cobaya* were divided into four groups, each of which consisted of seven animals. In group I, the lower left incisors of those *Cavia cobaya* were extracted and then given with 25 grams of PEG into the socket (control). In group II, the lower left incisors of those *Cavia cobaya* were extracted and then given with mangosteen peel extract and DFDBBX + 99 grams of PEG (at the active substance concentration of 0.5%). In group III, the lower left incisors of those *Cavia cobaya* were extracted and then given with mangosteen peel extract and DFDBBX + 49 grams of PEG (at the active substance concentration of 1%). In group IV, the lower left incisors of those *Cavia cobaya* were extracted and then given with mangosteen peel extract and DFDBBX + 24 grams of PEG (at the active substance concentration of 2%).<sup>8</sup> After 30 days of treatment, those *Cavia cobayas* were sacrificed, and then their mandible was cut to be decalcified with EDTA for 30 days.

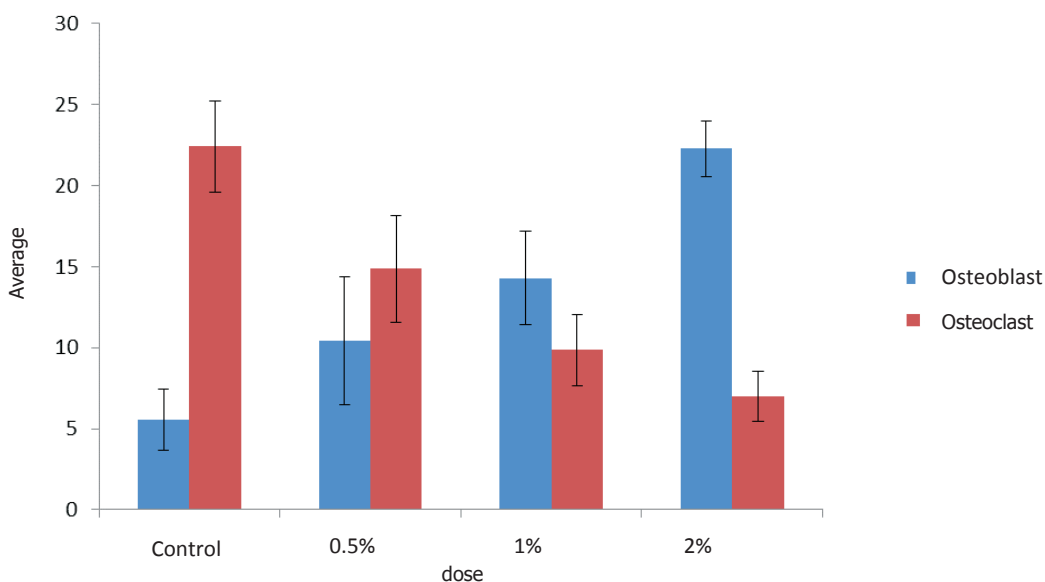
Manufacture of paraffin blocks was performed and cut with a rotary microtome with a thickness of 4 microns, and then deparaffinized by dissolving into xylol for 2 x 3 minutes. Residual xylol was washed with absolute alcohol, 99%, 95%, 90%, 80%, and 70% respectively for 2 x 1 minutes. Residual alcohol was washed with running water. Afterward, HE staining was performed for 30 seconds, and then rinsed with water. Staining with eosin was then conducted for 1-2 minutes, and washed with alcohol 70%, 80%, 90%, 95%, 99%, and absolute for 2 x 1 minutes. Meanwhile, xylol was washed for 2 x 2 minutes, and then glass cover previously dripped with Canada balsam covered them. Osteoblast cells, round cells located on the edge of trabecular bone, and osteoclasts, large cells with multiple nuclei, were observed. The number of osteoblasts and osteoclasts was measured using a light microscope with 400 times of magnification.<sup>9</sup> Statistical test was performed on the data obtained using Kolmogorov-Smirnov test. To know the difference between the groups, oneway Anova test was conducted, followed with multifactorial comparison test using Tukey HSD test after Levene homogeneity statistic test was previously performed.

**RESULTS**

The calculation results of averages and standard deviations of the number of osteoblasts and osteoclasts in each treatment group and the control group can be seen in Figure 1. The figure shows that there were differences in the averages of the number of osteoblasts in the extraction sockets after the treatments with the extract of mangosteen peel and DFDBBX with various concentrations of active ingredient (0.5%/1%/2%). The highest average of the number of osteoblasts was found in the fourth group at the concentration of 2%, while the lowest average of the number of osteoblasts was found in the control group. On the other hand, there were differences in the averages of the number of osteoclasts in the extraction sockets after the treatments with the extract of mangosteen peel and

DFDBBX with various concentrations of active ingredient (0.5%/1%/2%). The highest average of the number of osteoclasts was found in the control group, while the lowest average of the number of osteoclasts was found in the fourth group at the concentration of 2%.

Before the analysis of the test results conducted on the groups, normality test was conducted on each group using Kolmogorov-Smirnov test. In this research, all the research groups had p value greater than 0.05, which means that data from all the research groups had normal distribution. Based on the results of homogeneity test, all the research groups had significance value greater than 0.05. It indicates that all the groups had the same variance (homogeneous). With the prerequisite of normal and homogeneous distribution, one-way Anova test was then conducted to see the significance among the groups. Based on the results of the one way



**Figure 1.** The graphs display the averages and standard deviations of the number of osteoblasts and osteoclasts after 30 days of the treatment. Y-axis shows the averages of the number of osteoblasts and osteoclasts. X-axis shows the sockets filled with PEG (the control group), the sockets filled with a dose of 0.5%, the sockets filled with a dose of 1% dose, and the sockets filled with a dose of 2%.

**Table 2.** The results of Tukey HSD test on the number of osteoblasts and osteoclasts in each treatment group

		Group 2	Group 3	Group 4
Osteoblasts	Group 1	0.022*	0.000*	0.000*
	Group 2	-	0.078	0.000*
	Group 3			0.000*
Osteoclasts	Group 1	0.000*	0.000*	0.000*
	Group 2		0.002*	0.000*
	Group 3			0.000*

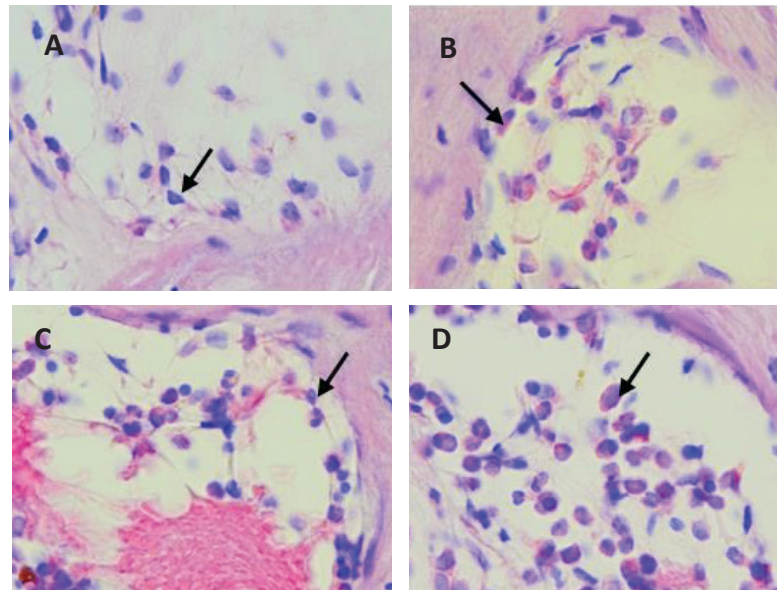
\* = There is a significant difference (p<0.05)

Note: group I: The lower left incisors of those *Cavia cobaya* were extracted and then given with 25 grams of PEG into the socket; group II: The lower left incisors of those *Cavia cobaya* were extracted and then given with Mangosteen peel extract and DFDBBX +99 g PEG (at the active substance concentration of 0.5%); group III: The lower left incisors of those *Cavia cobaya* were extracted and then given with Mangosteen peel extract and DFDBBX +49g PEG (at the active substance concentration of 1%); group IV: The lower left incisors of those *Cavia cobaya* were extracted and then given with Mangosteen peel extract and DFDBBX + 24 gPEG (at the active substance concentration of 2%).

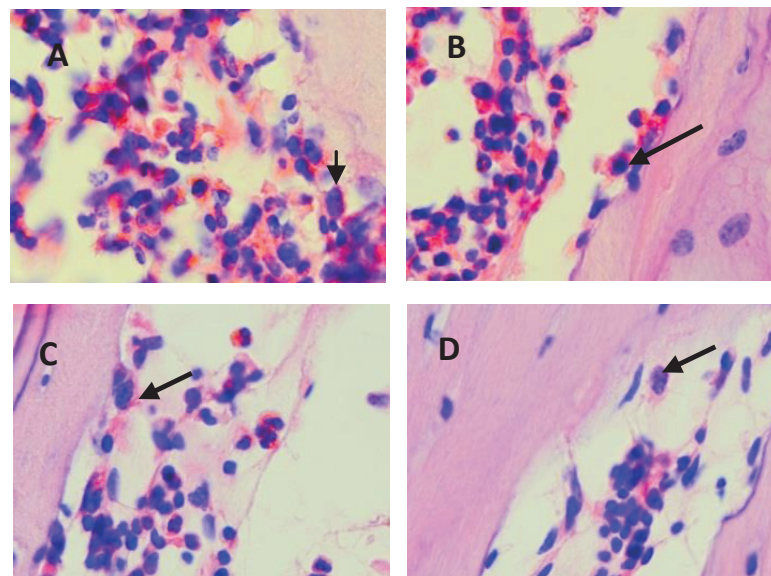
Anova test, the significance value obtained was 0.000, smaller than  $\alpha = 0.05$ . It means that there was a significant difference in the number of osteoblasts and osteoclasts between the control group and the treatment groups.

The results of Tuckey HSD test showed that there was a significant difference in the number of osteoblasts and

osteoclasts between the control group and the treatment groups I, II, III and IV with significance  $p = <0.05$ . But, there was no significant difference between Group II and Group III with  $p = 0.78$ . The microscopic description of osteoblast cells can be seen in Figure 2. The microscopic description of osteoclast cells can be seen in Figure 3.



**Figure 2.** The histological examination in identifying osteoblast cells (HE staining using light microscope with a magnification of 400X). Control and treatment groups. (A) control group; (B) active substance group with a concentration of 0.5%; (C) active substance group with a concentration of 1%; (D) active substance group with a concentration of active substance group with a concentration of 2%.



**Figure 3.** The histological examination in identifying osteoclast cells (HE staining using light microscope with a magnification of 400x). Control and treatment groups. (A) control group; (B) active substance group with a concentration of 0.5%; (C) active substance group with a concentration of 1%; (D) active substance group with a concentration of active substance group with a concentration of 2%.

## DISCUSSION

Based on the results of the data analysis, it is known that the number of osteoblasts increased, while the number of osteoclasts declined significantly between the control group and the treatment groups at the concentrations of 0.5%, 1%, and 2%. It indicates that the combination of mangosteen peel extract, DFDBBX, and PEG has significant effect on the formation of osteoblasts and osteoclasts in the extraction socket since the content of mangosteen peel extract plays a role as graft material.

Mangosteen peel contains at least about 40 kinds of xanton, such as mangostin, mangostenol, mangostinon A, mangostenon B, trapezifolixanthone, tovophyllin B,  $\alpha$ -mangostin,  $\beta$ -mangostin, garcinon B, mangostanol, flavonoid epicatechin, epicatechin, garciniafuran, mangoxanthone, and gartanin. Among those kinds of xanton,  $\alpha$ -mangostin and  $\gamma$ -mangostin are the most useful substance.<sup>10</sup> Xanton in the human body plays a role as anti-oxidant, anti-proliferation, anti-inflammatory, and anti-microbe. Xanton is a powerful antioxidant, which is necessary for balancing the pro-oxidants in the body and the environment, known as free radical.<sup>4</sup>  $\gamma$ -mangostin is able to stop inflammation by inhibiting production of cyclooxygenase-2 enzyme (COX-2) causing inflammation, inhibiting activities of Ikappa B kinase enzyme directly, preventing the process of gene transcription of COX-2 (the target gene of NF kappaB), and then lowering the production of PGE-2 during inflammation process.<sup>11,12</sup>

The administration of mangosteen peel ethanolic extract can reduce infiltration of inflammatory cells and expression of COX-2 in mice induced with periodontitis.<sup>13</sup>  $\alpha$  and  $\gamma$ -mangostin are bioactive substances that have anti-inflammatory effects by inhibiting the production of NO and PGE-2.<sup>14</sup>  $\alpha$  and  $\gamma$ -mangostin have anti-inflammatory properties based on the previous research on mice.  $\alpha$  and  $\gamma$ -mangostin are also able to decrease LPS-induced inflammatory gene, including TNF- $\alpha$ , IL-1, IL-6, IL-8, monocyte chemoattractant protein-1, and Toll-like receptor-2.<sup>15</sup> The use of *Garcinia mangostana* as a medicine for inflammatory diseases is associated with its ability to inhibit the release of NO and PGE-2, even control TNF- $\alpha$  and IL-4 moderately.<sup>15</sup>

In this research, mangosteen peel extract was used to lower inflammation caused by tooth extraction trauma by lowering the growth of osteoclasts and increasing the growth of osteoblasts. This is in line with a research conducted by Port and Martin in 2009 explaining that inflammation will trigger macrophages to induce the synthesis of pro-inflammatory cytokines, IL-1 and TNF- $\alpha$  leading to the release of phospholipids of fibroblast cell membranes, mast cells, neutrophils, macrophages, and lymphocytes; as a result, the metabolism of arachidonic acid will be triggered by phospholipase A2 enzyme, and cyclooxygenase (COX-2) enzyme will be produced.<sup>6</sup> The increasing of COX-2 can stimulate the synthesis of prostaglandins, especially PGE-2, which can lead to the

increasing of vasodilation and endothelial permeability, thereby, increasing the infiltration of inflammatory cells.<sup>16</sup> In addition, proinflammatory cytokines (IL-1, TNF- $\alpha$ ) and PGE-2 (prostaglandin E2) also stimulates osteoclast formation, either directly or via the RANKL (receptor activator of nuclear factor  $\kappa$ B ligand), resulting in differentiation and fusion of osteoclast precursors into osteoclasts. PGE-2 induces the occurrence of bone resorption intensively.<sup>7</sup>

A research conducted by Hakozaki *et al.*<sup>18</sup> shows that RANKL is a key mediator in the formation of osteoclasts. Protein bound on this membrane is part of tumor necrosis factor, expressed in a variety of cell types including osteoblasts, fibroblasts, and T cells during normal bone metabolism, RANKL are expressed by osteoblasts. However, the inflammatory part of RANKL is also expressed by immune cells, such as T lymphocytes. Expression of RANKL is also controlled by other modulators in the bone metabolism, such as parathyroid hormone, vitamin D3, and interleukin-11. Binding of RANKL on RANK receptor on the surface of pre-osteoblast can cause activation of jun terminal kinase and nuclear factor-kappaB, which leads to the formation osteoclasts.<sup>18</sup> Similarly, a research conducted by Chang *et al.*<sup>19</sup> also explains that the activation of NF- $\kappa$ B can increase osteoclast activity and bone resorption, and will simultaneously inhibit the function of osteoblasts.<sup>18</sup> RANKL also plays an important role in osteoimmunology. RANKL production is set in conjunction with the presence of inflammatory cytokines, such as TNF- $\alpha$  and IL-119.

Consequently, since mangosteen peel extract inhibited COX-2 and decreased proinflammatory cytokines (IL-1, TNF- $\alpha$ ) and PGE-2, the formation of osteoclasts, either directly or indirectly by RANKL (receptor activator of nuclear factor  $\kappa$ B ligand) was inhibited. As a result, the differentiation and fusion of osteoclast precursors into osteoclasts did not occur. In addition, the binding of the RANKL on RANK receptor on the surface of pre-osteoblasts was also inhibited. Thus, the activation of nuclear factor-kappaB (NF- $\kappa$ B) was inhibited. Therefore, the number of osteoclasts decreased.

For those reasons, it can be said that there is an inverse relation between osteoblasts and osteoclasts. The decreasing of osteoclast cells will occurs when the growth of osteoblast cells increases according to homeostasis in bone cells. Some researchers even state that osteoclasts are responsible for bone resorption, while osteoblasts are responsible for new bone formation.<sup>20</sup> Similarly, the results of this research also shows that the administration of the combination of mangosteen peel extract and DFDBBX increased the number of osteoblasts, but decreased the number of osteoclasts. Another cause that also affected the increasing of osteoblast cells in this research was the participation of a graft material combined with mangosteen peel extract. Graft material used in this study was DFDBBX, a type of xenograft production of Batan. Xenografts are useful for stimulating proliferation of osteoblasts, fibroblasts and endothelial cells.<sup>21</sup> DFDBBX

contain osteoconductive inorganic matrix component, serving to provide scaffold for bone regeneration without getting involved in bone formation itself.<sup>22</sup> The combination of mangosteen peel extract and DFDBBX, consequently, could reduce inflammation, decrease osteoclasts resulting in decreasing bone resorption, as well as stimulate and induce osteoblasts needed in alveolar bone formation. Finally, it can be concluded that the combination of mangosteen peel extract and DFDBBX can reduce osteoclasts and increase osteoblasts. The most effective dose of the active substance was 2%.

## REFERENCES

- Irinakis T. Rationale for socket preservation after extraction of a single-rooted tooth when planning for future implant placement. *J Can Dent Assoc* 2007; 72(10): 917-22.
- Kotsakis G, Markou N, Chrepa V, Krompa V, Kotsakis A. Alveolar ridge preservation utilizing the 'socket plug' technique. *Int J Oral Implantol Clin Res* 2012; 3(1): 24-30.
- Habal MB, Reddi AH. An update on bone grafting and bone substituting. *Advast Reconstr Surg* 1987; 3: 147-210.
- Yatman E. Kulit buah manggis mengandung Xanton yang berkhasiat tinggi. *Wawasan* 2012; 29(324).
- Hayyu NS. Sitotoksitas ekstrak kulit *Garcinia Mangostana* Linn terhadap sel fibroblas gingiva manusia. Skripsi. Fakultas Kedokteran Gigi, Universitas Airlangga 2013:24.
- Porth MC, Matfin G. Pathophysiology concepts of altered health science. 8<sup>th</sup> ed. New York: Mosby; 2009. p. 320.
- Wei S, Kitaura H, Zhou P, Ross FP, Teitelbaum SL. IL1 mediates TNF induced osteoclastogenesis. *J Clin Invest* 2005; 115(2): 282-90.
- Kresnoadi U. Toll-like receptor 2 sebagai signaling pathway Osteogenesis tulang alveol yang diinduksi kombinasi Aloe vera dan Graft. Disertasi. Surabaya: Fakultas Kedokteran, Universitas Airlangga; 2012. p. 42-4.
- Vindani D. Efektivitas kombinasi ekstrak jinten hitam (*Nigella Sativa*) dan graft terhadap peningkatan osteoblas tulang alveol pada *Cavia Cobaya*. Tesis. Surabaya: PPDGS FKG Unair; 2013. p. 24-35.
- Mardiana L. Ramuan dan khasiat kulit manggis. Cetakan V. Jakarta: Penebar Swadaya; 2013. p. 38.
- Nakatani K, Nakahata N, Arawaka T, Yasuda H, Ohizumi Y. Inhibition of and prostaglandin E2 synthesis by gamma-mangostin, a xanthone derivative cyclooxygenase in Mangosteen, in C6 rat glioma cell. *Biochem Pharmacol* 2002; 63(1):73-9.
- Nakatani K, Yamakuni T, Kondo N, Arakawa T, Oosawa K, Shimura S, Inoue H, Ohizumi Y. Gammamangostin inhibits inhibitor-kappaB kinase activity and decreases lipopolysaccharide-induced cyclooxygenase-2 gene expression in C6 rat glioma cells. *Mol Pharmacol* 2004; 66(3): 667-74.
- Prasetya RC. Ekspresi siklooksigenase-2 dan infiltrasi sel inflamasi gingiva pada tikus yang diinduksi periodontitis setelah pemberian ekstrak etanolik kulit manggis. Tesis. Yogyakarta: Universitas Gajah Mada; 201. p. 34.
- Chen LG, Yang LL, Wang CC. Anti-inflammatory activity of mangostins from *Garcinia mangostana*. *Food Chem Toxicol* 2008; 46(2): 688-93.
- Bumrungpert A, Kalpravidh RW, Chitchumroonchokchai C, Chuang CC, West T, Kennedy A, McIntosh M, Xanthoness from Mangosteen prevent lipopolysaccharide-mediated inflammation and insulin resistance in primary cultures of human adipocytes. *J Nutr* 2009; 139(6): 1185-91.
- Tewtrakul S, Wattanapiromsakul C, Mahabusarakam W. Effects of compounds from *Garcinia mangostana* on inflammatory mediators in RAW264.7 macrophage cells. *J Ethnopharmacol* 2009; 121(3): 379-82.
- Carranza F, Henry H, Newman, Michael G. Clinical periodontology. 10<sup>th</sup> ed. New York: WB Saunders; 2006. p. 5-7.
- Hakozaki A, Yoda M, Tohmonda T, Furukawa M, Hikata T, Uchikawa S, Takaishi H, Matsumoto M, Chiba K, Horiuchi K, Toyama Y. Receptor activator of NF-kB (RANK) ligand induces ectodomain shedding of RANK in murine RAW264.7 macrophages. *J Immunol* 2010; 184(5): 2442-8.
- Chang J, Wang Z, Tang E, Fan Z, McCauley L, Franceschi R, Guan K, Krebsbach PH, Wang CY. Inhibition of osteoblast function by IKK/NF-kB in osteoporosis. *Nat Med* 2009; 15(6): 682-9.
- Lorenzo J, Horowitz M, Choi Y. Osteoimmunology: interaction of the bone and immune system. *Endocr Rev* 2008; 29(4): 403-40.
- Gupta R, Pandit N, Malik R, Sood S. Clinical and radiological evaluation of an osseous xenograft for the treatment of infrabony defects. *J Can Dent Assoc* 2007; 73(6): 513.
- Ghamdi SH, Mokeem AS, Anil S. Current concepts in alveolar bone augmentation: a critical appraisal. *The Saudi Dentistry Journal* 2007; 19(2): 74-85.