

The enhancement of type 1 collagen expression after 10% propolis-carbonated hydroxyapatite application in periodontitis-induced rabbits

Indi Kusumawati¹, Suryono² and Ahmad Syaify²

¹Clinical Dentistry Program,

²Department of Periodontology,

Faculty of Dentistry, Universitas Gadjah Mada,

Yogyakarta – Indonesia

ABSTRACT

Background: Alveolar bone defects caused by periodontitis may require regenerative therapy to restore bone structure. Propolis possesses antibacterial, anti-inflammatory and antioxidant properties, which can stimulate bone regeneration. Propolis-carbonated hydroxyapatite (CHA) material was applied during open flap debridement (OFD) in periodontitis therapy. **Purpose:** To analyse the effect of the application of 10% propolis-CHA after OFD on type 1 collagen expression on periodontitis-induced rabbits. **Methods:** Six male rabbits, aged 5–8 months, weight 1500–2000 grams, were ligated with wire and injected with *Porphyromonas gingivalis* lipopolysaccharide (LPS) for six weeks to induce periodontitis. The samples were divided into three groups: group A (OFD only), group B (OFD+CHA) and group C (OFD+10% propolis-CHA). To acquire 10% propolis-CHA, the CHA block was cut into 10mg and then immersed in 1ml of 10% propolis solution for 24 hours at room temperature. Decapitation was performed on the seventh and 14th day after OFD was performed on each group and microscopic slides were prepared for type 1 collagen examination. The data was analysed using a two-way ANOVA with a 95% confidence interval followed by a post hoc LSD test. **Results:** The type 1 collagen expression in group C (61.36 ± 1.88 on day seven and 70.25 ± 3.89 on day 14) was significantly different from group A (42.91 ± 1.78 on day seven and 45.18 ± 2.48 on day 14) and group B (43.91 ± 5.31 on day seven and 59.63 ± 3.27 on day 14) on both the seventh day and the 14th day ($p=0.000$). **Conclusion:** The administration of 10% propolis-CHA during OFD can increase the type 1 collagen expression in the alveolar bone of rabbits on the seventh and 14th day.

Keywords: carbonated hydroxyapatite; periodontitis; propolis; type 1 collagen

Correspondence: Suryono, Department of Periodontology, Faculty of Dentistry, Universitas Gadjah Mada, Jl. Denta 1, Sekip Utara, Yogyakarta 55281, Indonesia. Email: suryonodent@mail.ugm.ac.id

INTRODUCTION

Periodontitis is a chronic inflammatory disease in periodontal tissues which is caused by particular microorganisms and characterized by the formation of pockets, recessions, or both.¹ The main cause of periodontitis is polymicrobial periodontal pathogens, most of which are gram-negative anaerobic bacteria.² Periodontitis can result in damage to the periodontal ligament, cementum and alveolar bone, which then leads to the formation of defects in the alveolar bone.³

Alveolar bone defects due to periodontitis require adequate treatment. A treatment used to obtain the biological conditions needed for the regeneration of periodontal tissues is open flap debridement (OFD), which has been proven to be successful in treating infrabony defect.⁴ OFD is a surgical procedure that aims to get direct access to the involved periodontal tissues and to remove necrotic tissues, yet it results in minimal periodontal tissue regeneration.⁵ The addition of bone graft material in the OFD treatment has been proven to increase the filling of bone defects.⁶ Carbonated hydroxyapatite (CHA) is one

example of alloplastic bone graft materials of which the composition is similar to that of human bone. Besides, it is biocompatible, has excellent osteoconductivity and can be resorbed by osteoclasts.⁷

Propolis is a natural resin substance produced by bees that possesses antibacterial, anti-inflammatory, antioxidant, anticancer, antiviral, antifungal and immunostimulant properties.⁸ In addition, propolis also has the ability to regenerate bone tissue by increasing osteoblast activity and decreasing osteoclast activity.⁹ An *in vivo* study showed that 10% propolis gel could stimulate the healing process of gingivitis in experimental animals by reducing the number of polymorphonuclear (PMN) cells, increasing the number of fibroblasts, and stimulating the formation of angiogenesis.¹⁰ A previous study showed that CHA immersed in 10% propolis solution had an excellent mechanical and chemical bond between the two materials,¹¹ and this new material showed excellent capability in stimulating fibroblast cell lines.¹² Devitaningtyas et al.¹³ proved the inhibition properties of CHA-10% propolis against *Porphyromonas gingivalis*. Another study of propolis-coated allograft bone graft material showed that propolis also has osteoinductive properties by stimulating the proliferation and differentiation of bone cells – thus accelerating the bone regeneration processes in experimental animals.¹⁴

Bone regeneration processes can be measured by the production of bone formation biomarkers: one of which is type 1 collagen. Type 1 collagen is produced by osteoblasts during the reparative phase in the bone healing process.¹⁵ Osteoblasts are mononucleated cells derived from mesenchymal stem cells (MSCs) which are responsible for bone synthesis and mineralization in the early stage of bone formation and final stage of bone remodeling.¹⁶ Expression of type 1 collagen can be observed on day seven, which increases on day 14.¹⁷ Another study showed that the expression of type 1 collagen reached its peak on day 14 after treatment in experimental animals.¹⁸ The objective of this study was to analyse the effect of the application of 10% propolis-CHA in OFD on the expression of type 1 collagen on periodontitis-induced rabbits.

MATERIALS AND METHODS

All the procedures for this research were approved by the Ethical Committee of the Faculty of Dentistry, Universitas Gadjah Mada, No. 00208/KKEP/FGK-UGM/EC/2019. This was an experimental study with a randomised post-test only control group design. The CHA (Gama-CHA[®], PT. Swayasa Prakarsa, Yogyakarta) was cut into pieces, each of which weighed 10mg. Pure propolis solution (Propolis Brazilian[®], Minas Gerais, Brazil) was diluted using sterile water with a dilution ratio of 1:9, thus resulting in a 10% concentration propolis solution. To acquire 10% propolis-CHA, the 10mg CHA was then immersed in 1ml of 10% propolis solution for 24 hours at room temperature.¹¹

The experimental animals that were used were six male rabbits (*Oryctolagus cuniculus*) aged 5–8 months, weight 1500–2000g and induced with periodontitis. Periodontitis induction on the rabbits was performed by the ligation technique and injection of lipopolysaccharide (LPS) from *Porphyromonas gingivalis* ATCC 33277 from Thermo Scientific, USA. The rabbits were first allowed to acclimatization for one week. Periodontitis induction was then started by anesthetizing the rabbits using ketamine HCL 40mg/kg of body weight (BW) and xylazine 3mg/kg BW by intramuscular injection, and then the cervical region in the mandibular anterior teeth was ligated using silk 3.0 for six weeks. Injection of 0.05ml LPS from *Porphyromonas gingivalis* was also performed three times a week by injecting the ligated mandibular anterior teeth.¹⁹

The rabbits as periodontitis animal models were randomly divided into three groups. Clinical signs of the induced periodontitis that were observed in the rabbits were tooth mobility, gingival recession and redness of the gingiva. The rabbits in group A were treated with OFD; those in group B were treated with OFD and application of CHA; and those in group C were treated with OFD and application of 10% propolis-CHA. Prior to the surgery, the rabbits were anesthetized by injecting ketamine 40mg/kg BW and xylazine 3mg/kg BW intramuscularly. A full thickness envelope flap was performed in the buccal side of the anterior mandible and then the inflamed tissue was debrided using a universal scaler. The predetermined material was applied to each group using dental tweezers while pressed gently onto the bone. The flap repositioning was done using 4.0 nylon thread. All the rabbits were then returned to their cages at room temperature and administered a soft diet for the first 24 hours, followed by feeding *ad libitum* during the research.

Rabbits from each group were randomly assigned to be decapitated on the seventh day and the 14th day after the OFD. Four microscopic slides were made from each rabbit. The decapitation procedure was carried out using a sodium pentobarbital overdose (i.e. 120mg/kg BW) injected intramuscularly. The defect area in the alveolar bone of the rabbits was fixed in 10% buffered formalin for 24 hours and then decalcified. Samples were embedded in paraffin wax and then sliced into 5µm thick sections using a microtome for the immunohistochemistry (IHC) staining. This study used polyclonal antibody type 1 collagen (1:100, bs10423R, Bioss, Beijing, China).

The observation of type 1 collagen expression was carried out using a light microscope in 400x magnification looking at three visual fields for each slide (reviewed by two independent observers). The observed osteoblasts were cuboidal in shape and were located on the peripheral side of the alveolar bone trabeculae. Osteoblasts that positively expressed type 1 collagen were dark brown in colour, while those which negatively expressed collagen were a purplish-blue colour. The data was presented in the form of a percentage of osteoblasts which were positive to type 1 collagen IHC staining. The formula was as follows:²⁰

$$\text{Type 1 collagen expression} = \frac{\text{number of positive cells}}{\text{total cells}} \times 100\%$$

The Shapiro-Wilk test was used as the data normality test and Levene's test of homogeneity of variance was also used. The data was then analysed using the two-way ANOVA test, with a confidence interval of 95%, and followed by the post hoc LSD test.

RESULTS

Figure 1 shows the histological view of the alveolar bone of *Oryctolagus cuniculus* on the seventh and 14th days for each group. The type 1 collagen, which was expressed by osteoblasts in the peripheral of the bone trabecula, is shown in dark brown.

The percentages of type 1 collagen expression found in all groups is presented in Table 1. The highest number of osteoblasts was observed in group C on day 14 (70.25%), whilst the lowest number was observed in group A on day seven (42.91%). The Shapiro-Wilk normality test showed that the type 1 collagen expression in each treatment group on each decapitation day were normally distributed with $p > 0.05$. Levene's homogeneity test showed that all data were homogeneous with $p > 0.05$. Based on the normality and homogeneity test results, a parametric statistical test two-way ANOVA was performed. The two-way ANOVA test showed significant differences in the type 1 collagen expression on days seven and 14 between the treatment groups with $p = 0.000$ ($p < 0.05$).

The post hoc LSD test presented in Table 2 shows that the type 1 collagen expression on day seven in group A was

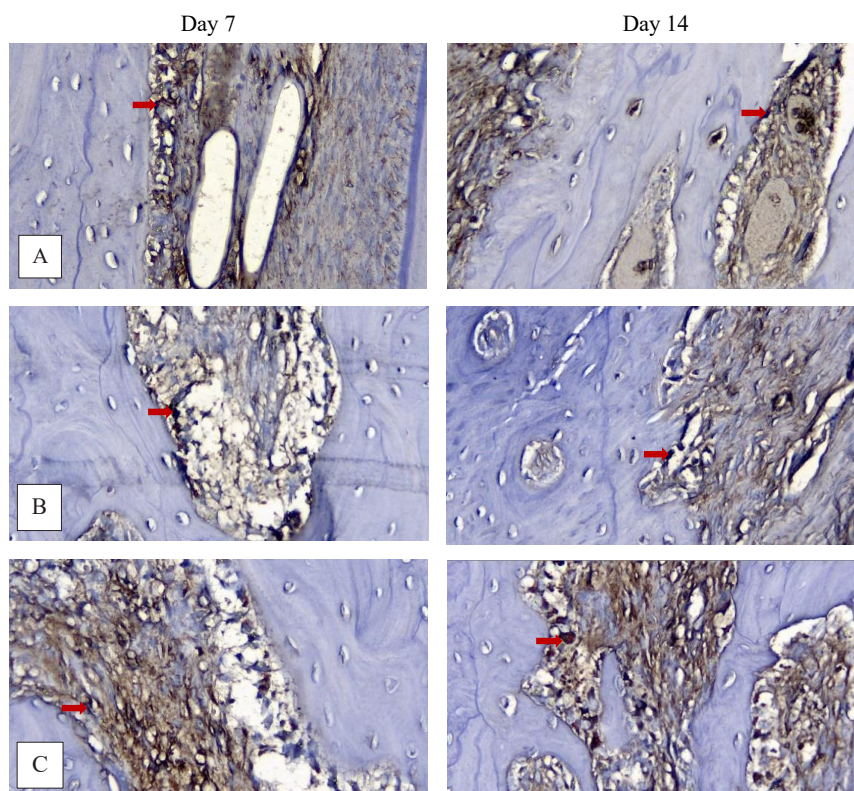


Figure 1. Type 1 collagen expression in (A) OFD group, (B) OFD+CHA group, (C) OFD+CHA+10% propolis group on days 7 and 14 at 400x magnification. The red arrows show a positive expression of type 1 collagen.

Table 1. Mean and standard deviation of type 1 collagen expression on days 7 and 14

Groups	n	Mean ± SD		p
		Day 7	Day 14	
A	4	42.91±1.78	45.18±2.48	0.000*
B	4	43.91±5.31	59.63±3.27	
C	4	61.36±1.88	70.25±3.89	

* significant differences between groups ($p < 0.05$)

Table 2. LSD test results of type 1 collagen expression on days 7 and 14

Days	Groups	A	B	C
7	A		0.687	0.000*
	B			0.000*
	C			
14	A		0.000*	0.000*
	B			0.001*
	C			

* significant differences between groups ($p < 0.05$)

not significantly different from that in group B ($p > 0.05$), while that of group A was significantly different from group C and the group B expression was significantly different from group C also ($p < 0.05$). On day 14, group A was significantly different from group B and group C. In addition, group B was significantly different from group C ($p < 0.05$). Thus, it can be concluded that the expression of type 1 collagen in the group treated with 10% propolis-CHA was higher than the other groups: both on day seven and day 14.

DISCUSSION

Type 1 collagen is the most abundant collagen found in bones, making up more than 90% of the organic bone mass.²¹ Type 1 collagen is produced by osteoblasts during the reparative phase of bone healing processes.¹⁶ Osteoblasts are mononucleated bone cells derived from MSCs.²²

The results of this study showed that the highest expression of type 1 collagen could be observed in the group given OFD+10% propolis-CHA: both on day seven and day 14. An increase in the expression of type 1 collagen is affected by the addition of propolis into CHA. These results prove that propolis has the ability to stimulate bone regeneration. This is in line with the findings of a previous study, showing that propolis has the ability to stimulate bone regeneration by stimulating the osteoblast differentiation process.⁹ According to Srivastava et al.²³ the ability of propolis to stimulate osteoblast differentiation can be attributed to flavonoids that increase the expression of runt-related transcription factor 2 (Runx2). Runx2 is a transcription factor needed by MSCs to differentiate into preosteoblasts, which express type 1 collagen at a low level. The preosteoblasts then require Runx2 transcription factors to differentiate into osteoblasts, which express type 1 collagen at a high level.²⁴

The expression of type 1 collagen on day seven in the OFD group was not significantly different from that of the group given OFD+CHA. This is probably because CHA has lower osteoinductivity, thus resulting in insignificant new bone formation. This concurs with the results of a previous study showing that it is necessary to add growth factors into CHA to increase the osteoinductivity of the material.²⁵

The results of this study have proved that the addition of propolis into CHA can increase the osteoinductivity of bone graft materials, which is evident from the increase in the expression of type 1 collagen in the group treated with OFD+10% propolis-CHA. This is in agreement with the results from a previous study, showing that propolis-coated allograft bone graft material has osteoinductivity by stimulating the proliferation and differentiation of bone cells, thus accelerating bone regeneration processes in experimental animals.¹⁴ This study was limited by the number of subjects and the observation time. From the data,

it can be concluded that the application of 10% propolis-CHA in the OFD procedure could increase the expression of type 1 collagen in the alveolar bone of *Oryctolagus cuniculus* on both the seventh and 14th days. A suggestion for future research is to investigate the variables over a longer time period with a larger sample size.

ACKNOWLEDGEMENT

This study was supported by the grant Penelitian Tesis Magister SIMLITABMAS in the fiscal year 2020 under contract No. 2024/UN1/DITLIT/DIT-LIT/PT/2020.

REFERENCES

- Carranza, F.A., Newman, M.G., Takei, H.H. dan KPR. Carranza's clinical periodontology. 11th ed. St Louis Missouri: Saunders Elsevier; 2012. p. 62–3.
- Nishihara T, Koseki T. Microbial etiology of periodontitis. *Periodontol* 2000. 2004; 36: 14–26.
- Graves DT, Kang J, Andriankaja O, Wada K, Rossa C. Animal models to study host-bacteria interactions involved in periodontitis. *Front Oral Biol*. 2012; 15: 117–32.
- Crea A, Deli G, Littarru C, Lajolo C, Orgeas GV, Tatakis DN. Intrabony defects, open-flap debridement, and decortication: a randomized clinical trial. *J Periodontol*. 2014; 85: 34–42.
- Muthu J, Namasivayam A, Perumalsamy R, Pushparajan S, Bose B, Kannan A. Efficacy of combination therapy using anorganic bovine bone graft with resorbable GTR membrane vs. open flap debridement alone in the management of grade II furcation defects in mandibular molars - A comparative study. *J Int Soc Prev Community Dent*. 2014; 4(4): 38.
- Kaushal S. Evaluation of OSSIFI® as alloplastic bone graft material in treatment of periodontal infrabony defects. *J Clin Diagnostic Res*. 2014; 8(10): 61–5.
- Landi E, Celotti G, Logroscino G, Tampieri A. Carbonated hydroxyapatite as bone substitute. *J Eur Ceram Soc*. 2003; 23(15): 2931–7.
- Lara Pereira YC, Mardegan Issa JP, Watanabe E, Nascimento GC, Iyomasa MM, Del Ciampo JO, Ervolino E. The therapeutic use of propolis extract in alveolar bone contaminated with bacterial endotoxin. *Dentistry*. 2018; 8(3): 1–9.
- Zohery AA, Meshri SM, Madi MI, Abd El Rehim SS, Nour ZM. Egyptian propolis compared to nanohydroxyapatite graft in the treatment of Class II furcation defects in dogs. *J Periodontol*. 2018; 89(11): 1340–50.
- Suryono S, Hasmy NS, Pertiwi TL, Benyamin B. Propolis 10%-gel as a topical drug candidate on gingivitis. *Int J Med Pharm*. 2017; 5: 12–7.
- Kusumawati I, Suryono, Syaify A. Loading and release profile assay of carbonated hydroxyapatite incorporated with propolis as bone graft material. *Maj Obat Tradis*. 2020; 25(2): 121–5.
- Wijayanti P, Lastianny SP, Suryono S. Growth of NIH 3T3 fibroblast cells exposed to carbonated hydroxyapatite with incorporated propolis. *Indones J Cancer Chemoprevention*. 2020; 11(2): 54–9.
- Devitaningtyas N, Syaify A, Herawati D, Suryono S. Evaluation of antibacterial potential of carbonated hydroxyapatite combined with propolis on *porphyromonas gingivalis*. *Maj Obat Tradis*. 2020; 25(1): 55–8.
- Abdellatif B, Mohamed H, Karim A, Asma B. Radiography monitoring of osteoconduction and osteoinduction of orthotopic allograft autoclaved covered with propolis. *Int J Adv Life Sci Technol*. 2014; 1(1): 25–31.
- Burr DB, Allen MR. *Basic and Applied Bone Biology*. Oxford: Elsevier Inc.; 2014. p. 55–6.

16. Neve A, Corrado A, Cantatore FP. Osteoblast physiology in normal and pathological conditions. *Cell Tissue Res.* 2011; 343(2): 289–302.
17. Vieira AE, Repeke CE, De Barros Ferreira S, Colavite PM, Biguetti CC, Oliveira RC, Assis GF, Taga R, Trombone APF, Garlet GP. Intramembranous bone healing process subsequent to tooth extraction in mice: micro-computed tomography, histomorphometric and molecular characterization. *PLoS One.* 2015; 10(5): 1–22.
18. Itagaki T, Honma T, Takahashi I, Echigo S, Sasano Y. Quantitative analysis and localization of mRNA transcripts of type I collagen, osteocalcin, MMP 2, MMP 8, and MMP 13 during bone healing in a rat calvarial experimental defect model. *Anat Rec Adv Integr Anat Evol Biol.* 2008; 291(8): 1038–46.
19. Zenobia C, Hasturk H, Nguyen D, Van Dyke TE, Kantarci A, Darveau RP. *Porphyromonas gingivalis* lipid A phosphatase activity is critical for colonization and increasing the commensal load in the rabbit ligature model. Bäumlér AJ, editor. *Infect Immun.* 2014; 82(2): 650–9.
20. Zhang W, Ju J, Rigney T, Tribble G. *Porphyromonas gingivalis* infection increases osteoclastic bone resorption and osteoblastic bone formation in a periodontitis mouse model. *BMC Oral Health.* 2014; 14: 1–9.
21. Kruger TE, Miller AH, Wang J. Collagen scaffolds in bone sialoprotein-mediated bone regeneration. *Sci World J.* 2013; 2013: 1–6.
22. Fawcett DW. *Buku ajar histologi (terj).* 12th ed. Jakarta: EGC; 2002. p. 174–195.
23. Srivastava S, Bankar R, Roy P. Assessment of the role of flavonoids for inducing osteoblast differentiation in isolated mouse bone marrow derived mesenchymal stem cells. *Phytomedicine.* 2013; 20(8–9): 683–90.
24. Nakashima K, de Crombrughe B. Transcriptional mechanisms in osteoblast differentiation and bone formation. *Trends Genet.* 2003; 19(8): 458–66.
25. Torre E. Molecular signaling mechanisms behind polyphenol-induced bone anabolism. *Phytochem Rev.* 2017; 16(6): 1183–226.