

# The correlation between Rood and Shehab's radiographic features and the incidence of inferior alveolar nerve paraesthesia following odontectomy of lower third molars

David B. Kamadjaja, Djodi Asmara, and Gita Khairana

Departement of Oral and Maxillofacial Surgery  
Faculty of Dental Medicine, Universitas Airlangga  
Surabaya-Indonesia

### ABSTRACT

**Background:** Odontectomy of lower third molar has a potential risk for inferior alveolar nerve impairment. Paraesthesia of inferior alveolar nerve has often been associated with close relationship between the apex of lower third molar and mandibular canal. Rood and Shehab's category has been commonly used for radiological prediction of inferior alveolar nerve injury following third molar surgery. **Purpose:** This study aimed to determine whether there was correlation between Rood and Shehab's radiographic features and the incidence of inferior alveolar nerve paraesthesia following odontectomy of lower third molar. **Method:** This was a retrospective cross-sectional study, using data obtained from the dental record of patients who had undergone odontectomy of lower third molars in Dental hospital of Universitas Airlangga during 2 years period. Samples were cases that, from presurgical radiograph, showed close relationship between lower third molar roots and mandibular canal. The case and non-case groups were assigned based on the presence of paraesthesia and non-paraesthesia of inferior alveolar nerves, respectively. Based on Rood and Shehab's category, the samples collected were then classified into two groups which were those whose relationship matched and did not match with the category, respectively. Data were analyzed using Chi-square correlation test. **Result:** Of 975 odontectomy cases included in this study, 80 cases were taken as study samples consisting of 15 and 65 cases assigned, respectively, as case and non-case. The 32 cases matched with the criteria of Rood and Shehab's category while the remainder of 48 cases did not. Of 32 cases which met the criteria of Rood and Shehab's relationship, only 5 cases showed paraesthesia, whereas out of 48 cases which did not met the criteria 10 cases showed paraesthesia. Statistical analysis showed significance value of 0.770 ( $p > 0.05$ ) indicating that there was no significant correlation between relations of third molar root and mandibular canal, based on Rood and Shehab's category, and the incidence of inferior alveolar nerve paraesthesia. **Conclusion:** There was no correlation between Rood and Shehab's radiographic features and the incidence of paraesthesia of inferior alveolar nerve following odontectomy of lower third molars.

**Keywords:** odontectomy; lower third molar; paraesthesia; inferior alveolar nerve; Rood and Shehab's (1990)

**Correspondence:** David B. Kamadjaja, Department of Oral and Maxillofacial Surgery, Faculty of Dental Medicine Universitas Airlangga. Jl. Mayjen Prof. Dr. Moestopo 47 Surabaya 60132, Indonesia. E-mail: davidbk65@gmail.com

### INTRODUCTION

Odontectomy is surgical removal of unerupted or impacted tooth which requires mucoperiosteal flap followed with removal of bone overlying the buried tooth.<sup>1</sup> Due to the close anatomic relation between lower third molars and mandibular canal, odontectomy of impacted lower third

molars carry potential risk for injury of inferior alveolar nerve.<sup>2</sup>

Injury of inferior alveolar nerve may be due to trauma, inflammation or infection in the periphery of the nerve manifesting clinically as reduced sensation, or paraesthesia, of lower lip and chin of the affected sides.<sup>3</sup> Various factors have been associated with the incidence which

include variation of the lower third molar roots shapes and locations, less cautious procedures leading to unnecessary large trauma to the bone, the technique used by the operator, excessive pressure on the sutured tissue, and post-operative infection.<sup>4,5</sup>

Study showed that inferior alveolar nerve may be afflicted in the removal of impacted lower third molar at a rate of 0.5 to 5%. In many cases the incidence of inferior alveolar nerve injury can be predicted radiographically prior to the surgery, based on the existence of close relationship between the nerve and the root.<sup>6</sup> Studies revealed that seven radiological signs could be suggested as indication for a close relationship between mandibular third molar root and mandibular canal. These signs have been used as radiological prediction of inferior alveolar nerve injury during third molar surgery.<sup>7</sup>

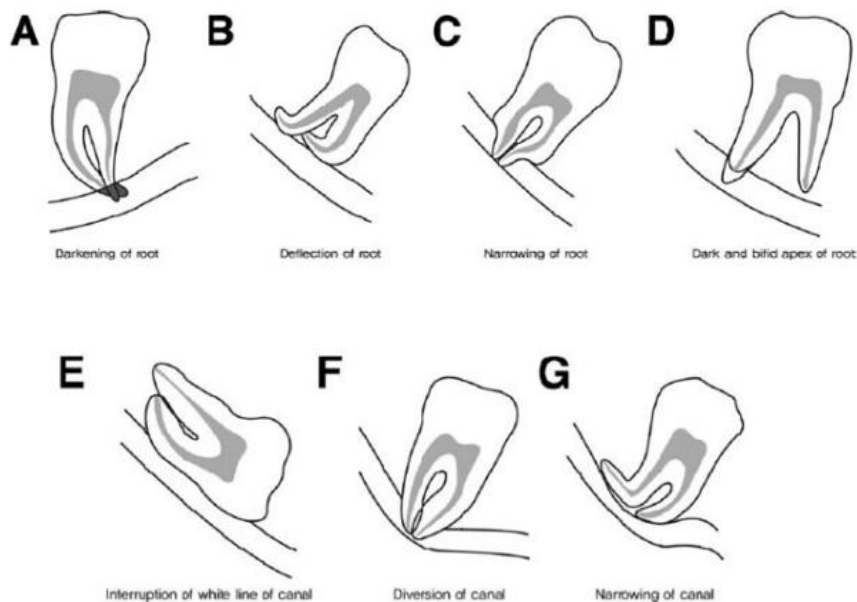
The aim of this study was to determine that there was correlation between the incidence of inferior alveolar nerve injury after odontectomy of lower third molar and Rood & Shehab's radiographic relationship of mandibular third molar root to mandibular canal.

## MATERIALS AND METHODS

This was a retrospective cross-sectional study. Data were collected from dental records in Oral and Maxillofacial Surgery Clinic Dental Hospital, Universitas Airlangga, Surabaya during 2 years period (2014-2015). Samples used in the study were cases of lower third molars odontectomy, which on pre-operative x-ray, showed a close relation between lower third molar roots and mandibular

canal. Included in case group were samples exhibiting sensory impairment of inferior alveolar nerve, while those which did not present with post operative nerve impairment were included in non-case group. Sample inclusive criteria in this study were (1) informed consents were taken prior to surgery and (2) all the inclusive cases were operated by senior residents. Samples collection was done using purposive sampling method without minimal number of sample.

Based on panoramic x-ray, both case and non-case samples were further assigned with Rood and Shehab (1990). Rood and Shehab (1990)<sup>7</sup> relationship categories notified with alphabet A, B, C, D, E, F, and G (Figure 1). Roods and Shehab's category was as follows. Relation "A" shows darkening of root indicating loss of cortical layer of the mandibular canal. Relation B shows deflection of root in which roots were acutely curved on approaching mandibular canal. Relation "C" shows narrowing of root in which the root tip was seen to become abruptly narrow across the mandibular canal indicating resorption of the roots. Relation "D" shows dark and bifid apex of root in which root tips seemed to darken and divert usually seen when mandibular canal was passing through molar roots. Relation "E" shows interruption of white line of mandibular canal. Relation "F" showed diversion of canal in which mandibular canal diverted its course on approaching the tip of tooth roots. Relation "G" shows narrowing of canal in which there seemed to be a decrease in diameter of mandibular canal on approaching the root tip of third molars. Relation which did not fall into any of Rood and Shehab's category was classified as "others".



**Figure 1.** Relation of mandibular third molar roots to mandibular canal based on Rood and Shehab.<sup>7</sup>

Note. darkening of root (A), deflection of root (B), narrowing of root (C), dark and bifid apex of root (D), interruption of white line of canal (E), diversion of canal (F) and narrowing of canal (G).

## RESULTS

Out of 975 cases of odontectomy performed in Oral and Maxillofacial Surgery Clinic within period of January 2014 through December 2015, there were 80 cases (8.20%) showing, radiographically, close relationship between third molar roots and mandibular canal, but only 15 cases (1.5%) showed sign and symptom of inferior alveolar nerve injury following odontectomy. Out of these 80 cases, only 32 cases met the criteria of Rood and Shehab's category while the other 48 cases did not meet any of the Rood and Shehab's criteria. Out of those 32 cases which met Rood and Shehab's criteria only 5 cases exhibited alveolar nerve injury paraesthesia, whereas from 48 cases of non-Rood & Shehab group, 10 cases showed paraesthesia of the same nerve.

From the total incidence of paraesthesia in this study which were 15 cases, 60% was found in males, while non-paraesthesia was dominated by females (67%). The incidence rate of paraesthesia was highest in age group of 26-35 (40%), while the highest rate of non-paraesthesia was found in age group of 17-25 (50.76%) (Table 1).

The result showed that the highest rate of appearance of Rood and Shehab's radiographic features was relation 'A' (12.50%) followed by relation 'B' and 'G' (7.50%) while the lowest rate of appearance was relation 'D' and 'F' (2.50%). However, the highest rate of appearance among total samples was relation "others" (60%) which was the relation other than those of Rood and Shehab's category (Table 1).

The result also showed that both relation 'A' and 'B' had the highest incidence rate (13.3%) of paraesthesia within Rood and Shehab category, while relation "others" which was the relation other than those of Rood and Shehab's category showed the highest incidence rate (66.67%) among total samples (Table 2).

**Table 1.** Incidence of paraesthesia and non-paraesthesia in study samples associated with sex and age

Variable	Paresthesia (%)	Non-paraesthesia (%)
Sex		
Male	9 (60.00)	21 (32.30)
Female	6 (40.00)	44 (67.69)
Age group		
12-16	1 (06.67)	0 (00.00)
17-25	5 (33.33)	33 (50.76)
26-35	6 (40.00)	22 (33.85)
36-45	2 (13.33)	8 (12.30)
46-55	1 (06.67)	2 (03.07)

Note: the study samples were 80 post odontectomy cases showing close relationship, radiographically, between lower third molar roots and mandibular canals.

**Table 2.** Distribution of incidence of paraesthesia and non-paraesthesia associated with relation of lower third molar root to mandibular canal according to Rood and Shehab's category

Relation in Rood and Shehab's category	Paresthesia (%)	No paraesthesia (%)	Total (%)
A	2 (13.33)	8 (12.30)	10 (12.50)
B	2 (13.33)	4 (6.15)	6 (7.50)
C	0 (0.00)	3 (4.61)	3 (3.75)
D	0 (0.00)	2 (3.07)	2 (2.50)
E	0 (0.00)	3 (4.61)	3 (3.75)
F	0 (0.00)	2 (3.07)	2 (2.50)
G	1 (6.67)	5 (7.69)	6 (7.50)
Others	10 (66.67)	38 (58.46)	48 (60.00)
Total	15 (100.00)	65 (100.00)	80 (100.00)

**Table 3.** Contingency table of Rood and Shehab's relation and incidence of paraesthesia

Relation	Paraesthesia (+)	Paraesthesia (-)	Total
Rood & Shehab (+)	5 (33.3)	27 (41.5)	32
Rood & Shehab (-)	10 (66.7)	38 (58.5)	48
Total	15	65	80

Chi-Square test using data analysis of the contingency table (Table 3) showed that p value = 0.770 ( $p > 0.05$ ) indicating that there was no correlation between Rood and Shehab's relation of third molar roots to mandibular canals and the incidence of inferior alveolar nerve paraesthesia.

## DISCUSSION

The result of the study showed that male was more predominant in paraesthesia group (Table 1) was consistent with the result of the study conducted by Tay and Go<sup>3</sup> in which the male was higher risk factor for the incidence of inferior alveolar nerve injury. An animal study by Miloro *et al.*,<sup>8</sup> associating nerve injury with few risk factors such as age, sex and anatomy, showed that spontaneous nerve recovery was evident in female group. However, other studies indicated that there was no correlation between sex and inferior alveolar nerve injuries after odontectomy of lower third molar.<sup>9,10</sup>

The result showing that paraesthesia of inferior alveolar nerve was most frequently found in age group of 26-35 was in line with few previous studies which revealed that

age was one of the most consistent factors in determining the degree of difficulty of odontectomy associated with the increase in bone density with age. Moreover, increase in age was also related with completion of root formation which may significantly increase the rate of complication related to nerve injury especially in patients above 25 years of age.<sup>6</sup> This was supported by result of other study which showed that age group of 26-30 had the highest risk of inferior alveolar nerve injury.<sup>9</sup> It was suggested that fully developed root tended to have close contact with nerve in mandibular canal.<sup>12</sup>

It was noted from the result above that the highest rate of appearance of Rood and Shehab's radiographic features, in this study, was relation 'A' followed by relation 'B'. The result was, surprisingly, consistent with Rood & Shehab's study whose result showed that darkening of the root (relation A) and deflection of root (relation B) had the highest rate of appearance.<sup>7</sup>

The highest incidence of inferior alveolar nerve paraesthesia, in this study, which was darkening of the root (A) and deflection of root (B) groups was also somewhat consistent with the result of Rood & Shehab's study which showed interruption of white line, darkening of the root and deflected root were the three highest incidence of lower lip impairment.<sup>7</sup> Few other studies revealed that darkening of the root, either isolated or in conjunction with other high-risk signs, seemed to be significant in predicting inferior alveolar nerve exposure.<sup>13,14</sup>

Statistic analysis result showed no significant correlation between Rood and Shehab's radiographic findings and incidence of inferior alveolar nerve paraesthesia was not consistent with few other studies suggesting that five radiographic features identified by Rood and Shehab were significantly related to inferior alveolar nerve injury except for narrowing of the canal and dark and bifid apex.<sup>7,13</sup> This findings may be explained as follows. First, there were only relatively few inclusive samples, i.e. cases showing radiographic features of Rood and Shehab category, and the low incidence of nerve injury (1.5%) in this study, in contrast to incidence rate of 0.4-8.4% in one study by Blondeu and Daniel.<sup>15</sup> Second, there most likely existed other radiographic features than those of Rood and Shehab category which could be the significant signs of close relationship between mandibular canal and third molar roots and, therefore, could be used as predictors of inferior alveolar nerve injury. Nevertheless, based on results of the study it was logical to assume that darkening of the root and deflection of the root were the two significant radiographic features of Rood and Shehab that could be

used as predictors of inferior alveolar nerve injury. Further studies are required to confirm this phenomenon. The conclusion of this study was that there was no correlation between Rood and Shehab's radiographic relation of lower third molar root to mandibular canal and the incidence of inferior alveolar nerve injury.

## REFERENCES

1. Sarikov R, Juodzbalys G. Inferior alveolar nerve injury after mandibular third molar extraction: a literature review. *J Oral Maxillofac Res* 2014; 5(4): e1.
2. Martini F, Timmons MJ, Tallitsch RB. *Human anatomy*. Upper Saddle River, N.J.: Prentice Hall; 2003. p. 195-7.
3. Tay AB, Go WS. Effect of exposed inferior alveolar neurovascular bundle during surgical removal of impacted lower third molars. *J Oral Maxillofac Surg* 2004; 62(5): 592-600.
4. Dimitroulis G. *Handbook of third molar surgery*. Bristol, England: Wright; 2001. p. 137-41.
5. Palma CC, Garcia MB, Larrazabal MC, Penarrocha DM. Radiographic signs associated with inferior alveolar nerve damage following lower third molar extraction. *Med Oral Patol Oral Cir Bucal* 2010; 15(6): e886-90.
6. Pogrel MA. What are the risks of operative intervention?. *J Oral Maxillofac Surg* 2012; 70(9 Suppl 1): S33-6.
7. Rood JP, Shehab B. The radiographic prediction of the inferior alveolar nerve during third molar surgery. *Br J Oral and Maxillofac Surgery* 1990; 28(1): 20-5.
8. Miloro, Ghali M, Larsen GE, Waite P. *Peterson's principles of oral and maxillofacial surgery*. London: BC Decker; 2004. p. 159-60.
9. Jerjes W, Upile T, Shah P, Nhembe F, Gudka D, Kafas P, McCarthy E, Abbas S, Patel S, Hamdoon Z, Abiola J, Vourvachis M, Kalkani M, Al-Khawalde M, Leeson R, Banu B, Rob J, El-Maaytah M, Hopper C. Risk factors associated with injury to the inferior alveolar and lingual nerves following third molar surgery-revisited. *Oral Surg Oral Med Oral Pathol Oral Radiol Endod* 2010; 109(3): 335-45.
10. Gulicher D, Gerlach KL. Sensory impairment of the lingual and inferior alveolar nerves following removal of impacted mandibular third molars. *Int J Oral Maxillofac Surg* 2001; 30(4): 306-12.
11. Valmaseda-Castellon E, Berini-Ayres L, Gay-Escoda C. Inferior alveolar nerve damage after lower third molar surgical extraction: a prospective study of 1117 surgical extractions. *Oral Surg Oral Med Oral Pathol Oral Radiol Endod* 2001; 92(4): 377-83.
12. Eyrich G, Seifert B, Matthews F, Matthiessen U, Heusser CK, Kruse AL, Obwegeser JA, Lübbers HT. 3-Dimensional imaging for lower third molars: is there an implication for surgical removal?. *J Oral Maxillofac Surg* 2011; 69(7): 1867-72.
13. Szalma J, Lempel E, Jeges S, Olasz L. Darkening of third molar roots: panoramic radiographic associations with inferior alveolar nerve exposure. *J Oral Maxfac Surg* 2011; 69(6): 1544-49.
14. Szalma J, Vajta L, Lempel E, Jeges S, Olasz L. Darkening of third molar roots on panoramic radiographs: is it really predominantly thinning of the lingual cortex?. *Int J Oral Maxfac Surg* 2013; 42(4): 483-88.
15. Blondeau F, Daniel NG. Extraction of impacted mandibular third molars: postoperative complications and their risk factors. *J Can Dent Assoc* 2007; 73(4): 325-325e.