

The effect of propolis extract and bovine bone graft combination on the number of osteoclast and osteoblast as an effort to preserve post-extraction socket (on *Cavia cobaya*)

Much Nizar, Utari Kresnoadi and Soekobagiono
Department Prosthodontics
Faculty of Dental Medicine, Universitas Airlangga
Surabaya – Indonesia

ABSTRACT

Background: Post-extraction alveolar bone height and width never reach the same dimensions as before extraction. A combination of propolis extracts and bovine bone graft (BBG) that are anti-inflammatory, antioxidant, osteoinductive and osteoconductive is expected to improve bone regeneration. **Purpose:** Knowing the effect of the combination of propolis extracts and BBG on the number of osteoclast and osteoblast as an effort to preserve the socket after extraction of *Cavia cobaya* teeth. **Methods:** 56 *Cavia cobaya* was divided into eight groups: the lower left incisor was extracted, and the socket was filled with 2% poly ethylene glycol (PEG), propolis extract+PEG, BBG+PEG, and a combination of propolis extract+BBG+PEG. The incisors socket of animals models were executed on the 14th and 30th days. Using HE for histopathological examination, the number of osteoclasts and osteoblasts were counted with a 400x magnification light microscope with nine visual fields. The data were analysed via one-way ANOVA and Tukey HSD tests. **Results:** The highest mean number of osteoclasts occurred in the BBG+PEG 14th day group and the lowest occurred in the propolis extract+BBG+PEG 14th day group. The highest mean number of osteoblasts occurred in the propolis + BBG + PEG combination 30th day group, the lowest occurred in the control group (PEG) on the 14th day. **Conclusion:** The 2% combination of propolis extracts and BBG effectively reduces the osteoclast number and increases the osteoblast number in preserving the socket after extracting *Cavia cobaya* teeth.

Keywords: bovine bone graft; osteoblast; osteoclast; propolis extract; socket preservation

Correspondence: Utari Kresnoadi, Department of Prosthodontics, Faculty of Dental Medicine, Universitas Airlangga. Jl. Mayjend. Prof. Dr. Moestopo 47 Surabaya 60132, Indonesia. E-mail: utari-k@fkg.unair.ac.id

INTRODUCTION

Tooth extraction is a common procedure in the field of dentistry. Alveolar ridge bone resorption is a condition that always accompanies tooth extraction. After healing, the height and width dimensions of the alveolar bone never reach their original dimensions. The process of alveolar bone resorption begins with the bond between the receptor activator nuclear kappa-B ligand (RANKL) produced by the osteoblast and the receptor activator nuclear kappa-B (RANK) presented by pre-osteoclasts. The binding between RANKL and RANK will activate osteoclasts. When osteoclast growth increases, alveolar bone resorption will occur. Without socket preservation after extraction, there will be a 50% reduction in alveolar ridge volume within

12 months. Therefore, socket preservation is needed to maintain the alveolar bone dimensions.¹⁻³

Autogenous bone graft is the best bone-grafting material/gold standard compared to allograft, xenograft and other synthetic materials. However, its application has some disadvantages because it requires a surgical procedure that presents difficulties regarding level of action, risk of infectious complications, pain, morbidity in donor area, hematoma, limited donor availability, the need for general anaesthesia, longer operative time, bleeding and the need for further surgery.⁴ Over the past few decades, researchers have focused on the field of bone regenerative materials to improve such characteristics as mechanical strength, molecular composition, biocompatibility and degradation capacity to determine bone's natural features. Xenograft,

using material originating from different species donors, is an alternative choice, as it offers osteoconductive features with limited resorptive potential and can be combined with growth factors or other sources of bone graft material; moreover, it can be mass produced at a relatively affordable cost.⁵ However, in the application of xenograft, post-surgery inflammation on a live host is inevitable. Surgical injuries are followed by inflammation, blood-biomaterial interactions and tissue fibrosis. Because xenograft is only osteoconductive and has no anti-inflammatory properties, inflammation can be prolonged and become chronic inflammation. Bone substitution by bone graft material can significantly increase the inflammatory response.⁶

Some researchers say that propolis extract has anti-inflammatory, antioxidant, anti-bacterial, anti-fungal, anti-viral and anti-cancer properties, as well as the ability to accelerate wound healing.⁷ The content of caffeic acid phenethyl ester (CAPE) in propolis, as an anti-inflammatory and antioxidant, can increase growth factors, increase extra cellular matrix (ECM) remodelling and increase re-epithelialisation so that it can improve socket healing after tooth extraction.⁸ Bovine bone graft (BBG) and propolis extract is a combination of materials that are osteoconductive and osteoinductive and have anti-inflammatory activity which is expected to be an alternative bone-grafting material.

This research focused on *Cavia cobaya* experimental animals which were treated by inserting a gel containing PEG, propolis extract, BBG, and a combination of propolis extract with BBG into the post-tooth extraction socket of *Cavia cobaya* with 2% active substance concentration for 14 days and 30 days, intended to determine the effectiveness of the administration of a combination of propolis and BBG extracts to decrease the number of osteoclasts and increase osteoblasts in the post-extraction tooth socket of *Cavia cobaya*.

MATERIALS AND METHODS

This study was approved by the Ethics Commission of the Faculty of Dental Medicine of Universitas Airlangga, as stated in the Ethical Clearance Certificate Number: 587/HRE.CCFODM/IX/2019. The experimental animal used was a healthy and active male *Cavia cobaya*, weighing around 300-350 gr, aged 3-3.5 months. Propolis extract was obtained from bees (*Apis mellifera*) from beekeeping in Lawang, Malang, East Java, which was carried out at the Surabaya Industrial Research and Consultation Center. BBG comes from good bovine bones, has passed screening and is free of infectious diseases. At the tissue bank of Dr. Soetomo General Hospital-Surabaya, BBG from good bovine processed through a dissection process to remove soft tissue, followed by cutting, washing, drying, deep-freezing, freeze drying, packing, sterilisation with x-ray gamma radiation to remove immunogenic properties and packaging in 150-355 μm powder.

Poly Ethylene Glycol (PEG) obtained from mixing PEG 400 and PEG 4000 in a ratio of 1: 1 is used as a carrier so that the mixture becomes a gel to facilitate its application into the socket.⁹ A 2% concentration of active substance is derived from 0.5 gr propolis and 0.5 gr BBG mixed with 24 gr PEG, so we get 25 gr propolis + BBG + PEG gel. The gel was filled as much as 0.1 cc according to the tooth extraction socket volume, then sewn with a sterile polyamide monofilament yarn (Braun Aesculap, DS 12 3 / 8c, 12 mm, 6/10 metric, 0.7). A total of 56 *Cavia cobaya* were divided into eight groups, seven in each. They were then separated into groups for 14 days (I, III, V, VII) and groups for 30 days (II, IV, VI, VIII). Each group received four treatments. The left lower incisor was extracted and the socket was given PEG (control), propolis extract + PEG, BBG + PEG, and a combination of propolis extract + BBG + PEG. Groups I and II, after extraction, had the socket filled with PEG only. For Groups III and IV, after extraction, the socket was filled with propolis extract + PEG. For Groups V and VI, after extraction, the socket was filled with BBG + PEG. For Groups VII and VIII, after extraction, the socket was filled with a combination of propolis extract + BBG + PEG. The lower jaw in the tooth extraction area was removed, softened with EDTA for \pm 3 months, and then a paraffin block preparation was made. The paraffin block was then cut using a rotary microtome with a thickness of \pm 4 μ , after which it was placed on a glass object wrapped in polylycin.

Deparaffinisation was achieved by dissolving the specimen in xylol for 2x3 minutes. The remainder of xylol was washed with absolute alcohol, 99%, 95%, 90%, 80%, 70%, for each of them for 2x1 min, followed by staining HE.⁹ Then, a histopathological examination (HPA) was performed to count the number of osteoclasts and osteoblasts with a 400x magnification light microscope with nine visual fields. The data tabulation was statistically analysed via one-way ANOVA and Tukey HSD tests.

RESULTS

The highest mean number of osteoclasts occurred in group V, with BBG + PEG 14th day treatment at $13.71 \pm \text{SD } 3.20$, and the lowest occurred in group VII with propolis + BBG + PEG 14th day treatment at $6.29 \pm \text{SD } 1.38$. Meanwhile, the highest mean number of osteoblasts occurred in group VIII with a combination treatment of propolis extract + BBG + PEG 30th day at $25.86 \pm \text{SD } 3.18$ and the lowest occurred in the I/control group (PEG) 14th day at $5.14 \pm \text{SD } 0.9$. A block diagram of the average number of osteoclasts and osteoblasts can be seen in Figures 1 and 2. Histological features can be seen in Figures 3 and 4.

The results of one-way ANOVA analyses in groups of 14 days and 30 days show a significant difference in the number of osteoclasts and the number of osteoblasts between the control group, propolis extract + PEG, BBG + PEG, and propolis extract + BBG + PEG, with a value

Table 1. Tukey HSD test results on osteoclasts on the 14th and 30th days

Group	I	II	III	IV	V	VI	VII	VIII
I		0.996	0.756	0.049*	0.023*	1.000	0.004*	0.049*
II			0.311	0.007*	0.136	1.000	0.000*	0.007*
III				0.756	0.000*	0.480	0.241	0.756
IV					0.000*	0.016*	0.988	1.000
V						0.070	0.000*	1.000
VI							0.001*	0.016*
VII								0.988
VIII								

* = significant (p< 0.05)

Table 2. Tukey HSD test results on osteoblasts on the 14th and 30th days

Group	I	II	III	IV	V	VI	VII	VIII
I		0.000*	0.000*	0.000*	0.032*	0.000*	0.000*	0.000*
II			0.968	0.000*	0.307	0.781	0.539	0.000*
III				0.000*	0.032*	1.000	0.985	0.000*
IV					0.000*	0.001*	0.004*	0.000*
V						0.008*	0.002*	0.000*
VI							1.000	0.000*
VII								0.000*
VIII								

* = significant (p< 0.05)

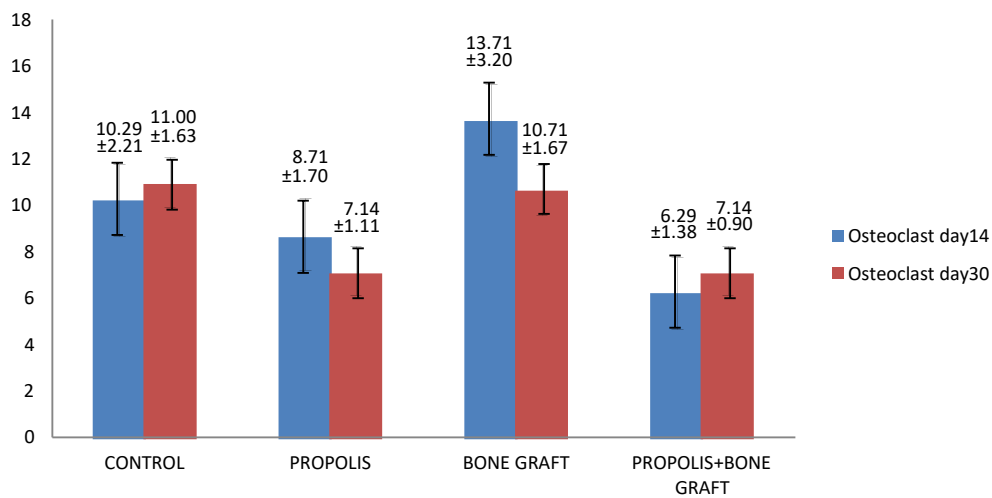


Figure 1. The mean and standard deviation of osteoclast number on the 14th and 30th days.

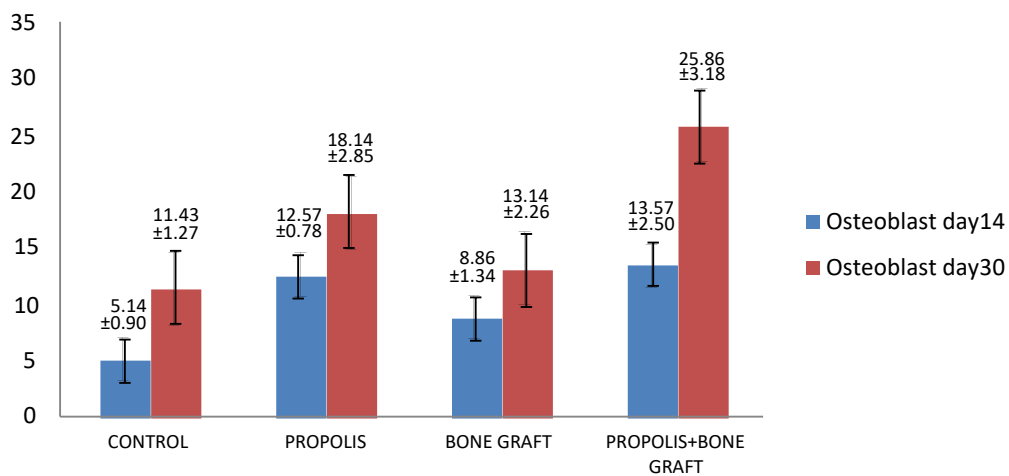


Figure 2. The mean and standard deviation of osteoblast number on the 14th and 30th days.

of $p = 0.000$ ($p < 0.05$). Tukey HSD test results can be seen in Tables 1 and 2. The microscopic images of osteoclasts and osteoblasts can be seen in Figure 3 (day 14) and Figure 4 (day 30).

DISCUSSION

The height and width of the alveolar ridge bone naturally heals after tooth extraction without socket preservation,

albeit never reaching the same height and width as before extraction. Therefore, it is important to develop socket-preservation procedures to maintain the height and width of the alveolar bone. The adequate height and width of the alveolar bone are very important in supporting the successful application of implants and conventional prostheses.^{1,2}

Based on research data, significant differences exist between treatment groups. The highest mean of osteoclasts number occurred in group V (BBG + PEG on day 14)

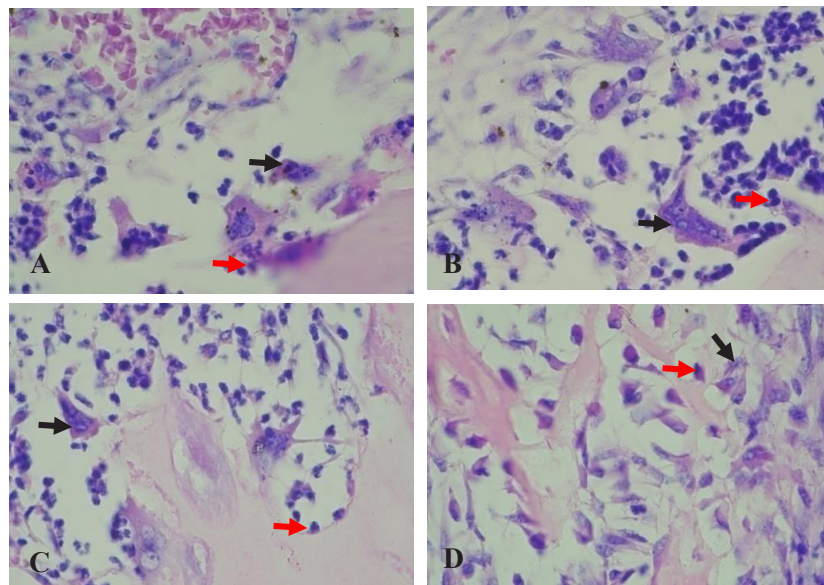


Figure 3. Osteoclasts (black arrows) and osteoblasts (red arrows) on the 14th day; new bone tissue density has not yet been seen. A. Group I (Control/PEG), with the lowest number of osteoblast ($5.14 \pm \text{SD } 0.9$); B. Group III (Propolis extract + PEG); C. Group V (BBG + PEG), with the highest number of osteoclasts ($13.71 \pm \text{SD } 3.2$); D. Group VII (Propolis + BBG + PEG extract), with the lowest number of osteoclasts ($6.29 \pm \text{SD } 1.38$).

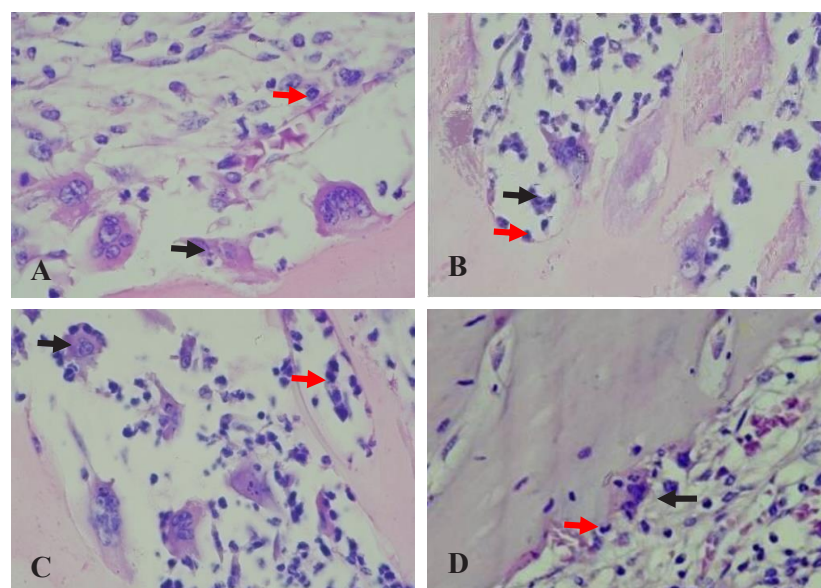


Figure 4. Osteoclasts (black arrows) and osteoblasts (red arrows) on day 30th, beginning to show the density of new bone tissue that has formed. A. Group II (Control / PEG); B. Group IV (Propolis extract + PEG); C. Group VI (BBG + PEG); D. Group VIII (Propolis + BBG + PEG Extract), with the highest number of osteoblast ($25.86 \pm \text{SD } 3.18$).

and the lowest occurred in group VII (propolis extract + PEG on day 14). While the highest mean of osteoblasts number occurred in group VIII (Propolis extract + BBG + PEG on day 30), and the lowest mean occurred in group I (Control on day 14). This was reinforced by the results of the one-way ANOVA test that showed a significant difference in the number of osteoclasts and osteoblasts between each treatment group. The highest number of osteoclasts occurred on day 14 (group V), indicating that osteoclastogenesis activity was still ongoing and thus suggesting a possibility that bone-grafting material can increase inflammatory response, thereby triggering an increased number of osteoclasts.

Markel *et al.* (2012),⁶ revealed that bone-graft material significantly triggers an increase in the inflammatory response. Inflammation can increase the number of osteoclasts, pro-inflammatory cytokines (Tumor Necrosis Factor- α /TNF- α and interleukin 1/IL-1), receptor activator nuclear factor kappa- β ligand (RANKL) and receptor activator nuclear factor kappa- β (RANK).¹⁰ These results are in line with Vieira's study which states that, on days 10 to 14, osteoclasts begin to absorb cortical margins and smooth sharp bones.¹¹ This did not occur in group VIII on day 30, other than a decrease in inflammation, which is also likely due to the role of propolis content that is anti-inflammatory, depressing osteoclastogenesis and decreasing the number of osteoclasts; on the other hand, osteoblastogenesis activity is increasing.

The number of osteoclasts in the group not treated with propolis extract (I, II, V, and VI) is higher than the group treated with propolis extract (III, IV, VII, and VIII). The decrease in the number of osteoclasts in this group is probably caused by the content of propolis extract, which is able to reduce the inflammatory response. The number of osteoblasts in the group treated with propolis extract (III, IV, VII, and VIII) is higher than the group not treated with propolis extract (I, II, V, and VI). The increased number of osteoblasts in this group is likely due to the propolis extract's ability to induce MSCs to differentiate into osteoblasts. This is in line with research by Darmadi and Mustamsir (2016)¹² and by Altan *et al.* (2013),¹³ which focused on the application of propolis extract on femoral fractured bones of wistar rats. In these studies, propolis extract appeared to inhibit osteoclastic activity and stimulate osteoblastic activity on bone metabolism, thus decreasing the number of osteoclasts and increasing the number of osteoblasts and chondrocytes.

The examination of the Surabaya Industrial Research and Consultation Institute showed that the ethanol extract of propolis from Lawang-Malang contained 2.5% caffeic acid (CAPE), 1.05% apigenin, 1.28% flavonoids, 0.82% saponin, 1.03% quersetin and 1.15% terpenoid. Propolis is a natural ingredient from bee products that has anti-inflammatory, anti-oxidant, anti-microbial, anti-cancer and anti-fungal properties, and is able to accelerate wound healing. These properties are closely related to the inherent flavonoid, phenolic acids, terpenoid and aromatic acid

compounds. Flavonoids and hydroxycinnamic acid, as the main components, are bioactive substances that act as antioxidants, preventing the negative effects of free radicals by binding to anion peroxide and hydroxide radicals, thereby reducing oxidative pressure. The decrease of oxidative pressure level suppresses the activation of nuclear factor kappa beta (NF- κ B) that acts as a transcription factor for the coding of pro-inflammatory cytokine genes, including TNF- α and IFN- γ so as to reduce inflammation.^{7,14}

Caffeic acid phenetyl ester (CAPE) is an antioxidant that can inhibit excessive oxidative reactions caused by inflammatory reactions and metabolic processes of cell injury. As an anti-inflammatory, CAPE acts to inhibit phospholipase in the arachidonic acid cascade, so that it does not release prostaglandins and leukotrin and inhibits the process of lipoxygenase (LOX) and cyclooxygenase (COX), which play a role in inflammatory metabolic pathways. CAPE is lipophilic and facilitates cell infiltration, releases anti-inflammatory cytokines (TGF- β , IL-10, IL-4), is a specific inhibitor of NF- κ B transcription, inhibits the release of pro-inflammatory cytokines (TNF- α , IL-1, IL-8, and IL-6) and increases the proliferation of fibroblasts, so as to accelerate the healing of the socket after tooth extraction.^{15,16}

The combination of propolis extracts and BBG, in addition to being anti-inflammatory and anti-oxidant, also has osteoconduction and osteoinduction characteristics in the bone-regeneration process. BBG acts as a scaffold and as a medium for stem cells and osteoblasts to attach, live and develop properly in bone defects. New blood vessels can attach to the scaffold and stimulate the apposition of new bone cells. Inorganic material from BBG is able to support the attachment and proliferation of osteoblasts, which is the first step in the process of new bone formation. The material can support the bone matrix for regulation through three mechanisms: (a) spacing out strong fillers; (b) providing osteoblast attachment and proliferation media; and (c) as a means for stimulating bone formation. Osteoblasts play important role in the process of bone remodelling.

Bone graft material in support of new bone formation occurs through several biological processes: osteoinduction, osteoconduction, osteopromosi and osteogenesis. Osteoinduction occurs when osteoprogenitor cells are stimulated to differentiate into osteoblast cells and begin new bone formation. Osteoconduction occurs when the material acts as a scaffold or framework for osteoblast cells in expanding the framework in new bone growth. Osteopromosi occurs when bone graft material is able to strengthen the osteoinduction process, whereas osteogenesis occurs when there are osteoblast cells derived from bone graft material that play a role in the growth of new bone during bone formation.¹⁷ In conclusion, the combination of propolis extracts and BBG effectively reduced the number of osteoclasts and increased the number of osteoblasts in the socket preservation of a post-extraction tooth with 2% active substance concentration.

REFERENCES

- Pagni G, Pellegrini G, Giannobile W V., Rasperini G. Postextraction alveolar ridge preservation: biological basis and treatments. *Int J Dent.* 2012; 2012: 1–13.
- Kresnoadi U, Hadisoesanto Y, Prabowo H. Effect of mangosteen peel extract combined with demineralized freeze-dried bovine bone xenograft on osteoblast and osteoclast formation in post tooth extraction socket. *Dent J (Majalah Kedokt Gigi).* 2016; 49(1): 43–8.
- Soekobagiono S, Alfiandy A, Dahlan A. RANKL expressions in preservation of surgical tooth extraction treated with *Moringa (Moringa oleifera)* leaf extract and demineralized freeze-dried bovine bone xenograft. *Dent J (Majalah Kedokt Gigi).* 2018; 50(3): 149–53.
- Periya SN, Hammad HGH. Bone grafting in dentistry: biomaterial degradation and tissue reaction: a review. *EC Dent Sci.* 2017; 9(6): 239–44.
- Titsinides S, Agrogiannis G, Karatzas T. Bone grafting materials in dentoalveolar reconstruction: A comprehensive review. *Jpn Dent Sci Rev.* 2019; 55(1): 26–32.
- Markel DC, Guthrie ST, Wu B, Song Z, Wooley PH. Characterization of the inflammatory response to four commercial bone graft substitutes using a murine biocompatibility model. *J Inflamm Res.* 2012; 5(1): 13–8.
- Khurshid Z, Naseem M, Zafar MS, Najeeb S, Zohaib S. Propolis: A natural biomaterial for dental and oral healthcare. *J Dent Res Dent Clin Dent Prospects.* 2017; 11(4): 265–74.
- Ernawati DS, Puspa A. Expression of vascular endothelial growth factor and matrix metalloproteinase-9 in *Apis mellifera* Lawang propolis extract gel-treated traumatic ulcers in diabetic rats. *Vet World.* 2018; 11(3): 304–9.
- Kresnoadi U, Rahayu RP, Rubianto M, Sudarmo SM, Budi HS. TLR2 signaling pathway in alveolar bone osteogenesis induced by Aloe vera and xenograft (XCB). *Braz Dent J.* 2017; 28(3): 281–6.
- Kresnoadi U, Ariani MD, Djulaeha E, Hendrijantini N. The potential of mangosteen (*Garcinia mangostana*) peel extract, combined with demineralized freeze-dried bovine bone xenograft, to reduce ridge resorption and alveolar bone regeneration in preserving the tooth extraction socket. *J Indian Prosthodont Soc.* 2017; 17(3): 282–8.
- Vieira AE, Repeke CE, De Barros Ferreira S, Colavite PM, Bigueti CC, Oliveira RC, Assis GF, Taga R, Trombone APF, Garlet GP. Intramembranous bone healing process subsequent to tooth extraction in mice: micro-computed tomography, histomorphometric and molecular characterization. *PLoS One.* 2015; 10(5): 1–22.
- Darmadi D, Mustamsir E. The effect of propolis on increasing the number of osteoblasts and chondrocytes, and decreasing the number of osteoclasts in Wistar rats (*Rattus norvegicus*) with femoral bone fracture. *J Dent Med Sci.* 2016; 15(12): 90–5.
- Altan BA, Kara IM, Nalcaci R, Ozan F, Erdogan SM, Ozkut MM, Inang S. Systemic propolis stimulates new bone formation at the expanded suture A histomorphometric study. *Angle Orthod.* 2013; 83(2): 286–91.
- Ningsih FN, Rifa'i M. Propolis action in controlling activated T cell producing TNF- α and IFN- γ in diabetic mice. *Turkish J Immunol.* 2017; 5(2): 36–44.
- Puspasari A, Harijanti K, Soebadi B, Hendarti HT, Radithia D, Ernawati DS. Effects of topical application of propolis extract on fibroblast growth factor-2 and fibroblast expression in the traumatic ulcers of diabetic *Rattus norvegicus*. *J Oral Maxillofac Pathol.* 2018; 22(1): 54–8.
- Günay A, Arpağ OF, Atilgan S, Yaman F, Atalay Y, Acikan İZ. Effects of caffeic acid phenethyl ester on palatal mucosal defects and tooth extraction sockets. *Drug Des Devel Ther.* 2014; 8: 2069–74.
- Kumar P, Vinitha B, Fathima G. Bone grafts in dentistry. *J Pharm Bioallied Sci.* 2013; 5(Suppl 1): S125–7.