

CASE REPORT

pISSN: 1907-3062 / eISSN: 2407-2230

Upper extremity deep vein thrombosis in an informal porter

Dewi S. Soemarko* and Herlinah****ABSTRACT****BACKGROUND**

Upper extremity deep vein thrombosis (UEDVT) is a rare condition, in which job-related arm movements and repetitive, forceful or overhead arm activities have been recognized as the predisposing factor for this condition. UEDVT can occur among informal porters. This report describes a case of UEDVT in an informal porter due to manual lifting of heavy goods and reviews the literature for occupational reports of this condition.

CASE DESCRIPTION

A 35-year-old male informal porter presented with marked swelling, pain, and numbness of his right arm 3 days after a prolonged episode of lifting heavy goods. A Doppler ultrasound showed thrombosis in the right subclavian and axillary veins and laboratory tests found elevated D-dimer. Patient was diagnosed as having axillo-subclavian thrombosis and treated with low molecular-weight heparin. One month after the last follow-up, patient returned to work with modified capacity and after 3 months of return to work, patient was able to resume his regular duties without impairment or disability.

CONCLUSION

The occupation of informal porter should be considered a risk factor for upper extremity deep vein thrombosis (UEDVT), thus the occupational medicine physician should be aware of this condition in the context of manual workers. Detailed occupational history to aid the diagnosis and future risk assessment are needed, and education for preventing UEDVT should be provided to porters.

Keywords: Informal porter, occupational medicine physician, upper extremity deep vein thrombosis

*Department of Community Medicine, Faculty of Medicine, Universitas Indonesia, Jakarta, Indonesia

**Occupational Medicine Specialist Program, Faculty of Medicine, Universitas Indonesia, Jakarta, Indonesia

Correspondence:

Herlinah
Occupational Medicine Specialist Program, Faculty of Medicine, Universitas Indonesia, Jakarta, Indonesia
Email: dr.herlina.tan81@gmail.com
ORCID ID: 0000-0001-9774-3270

Date of first submission, September 6, 2020

Date of final revised submission, October 12, 2020

Date of acceptance, October 14, 2020

This open access article is distributed under a Creative Commons Attribution-Non Commercial-Share Alike 4.0 International License

Cite this article as: Soemarko DS, Herlinah. Upper extremity deep vein thrombosis in an informal porter: a case report. *Univ Med* 2020;39:207-11. doi: 10.18051/UnivMed.2020.v39.207-211



INTRODUCTION

Lower limb deep vein thrombosis (DVT) is a common and well-described condition which has recently grown in public awareness. The risk factors for lower limb DVT arise from underlying components of Virchow's triad: venous stasis, hypercoagulability, and injury to the intima of veins.^(1,2) Upper extremity deep vein thrombosis (UEDVT) is a rare disorder, which usually refers to thrombosis of the axillary and/or subclavian veins and may be associated with significant morbidity and complications such as pulmonary embolism.⁽³⁾ The condition is subject to the same risk factors as the formation of lower limb DVT.⁽¹⁾

Upper extremity deep vein thrombosis is caused by problems anterior to the scalene triangle in a space bordered by the bony and ligamentous structures of the costoclavicular junction, as well as the subclavius muscle and tendon. The subclavian vein travels in the proximity of the clavicle, first rib, and anterior scalene and subclavius muscles. Upper extremity deep vein thrombosis is related to the compression and subsequent thrombosis of the subclavian vein due to these structures. With arm abduction, the subclavian vein is compressed at this costoclavicular space, a finding that can often be easily demonstrated, even in patients without effort thrombosis. In addition, hypertrophy of the anterior scalene muscle posteriorly or the subclavius muscle anteromedially, further narrows the constrained costoclavicular space.^(4,5)

That UEDVT may be due to narrowing of the costoclavicular junction, is demonstrated by the relatively constant finding that UEDVT frequently occurs with repetitive and vigorous arm abduction or external rotation of the shoulder during athletic or occupational activities.⁽⁴⁾ Given that UEDVT is associated with upper extremity activity, it seems plausible that there may be a preponderance of such cases among the working populations, particularly blue-collar occupations demanding

repetitive upper extremity activities on a daily basis throughout one's working career.⁽⁶⁾ In this case report we present a manual worker with UEDVT associated with prolonged episodes of lifting heavy goods and review the literature on the work-relatedness with the condition.

CASE PRESENTATION

A 35-year-old male with the occupation of informal porter presented with a sudden onset of marked swelling, redness, pain, and numbness of his right arm. This occurred 3 days after the most strenuous and prolonged episode of lifting heavy goods (approximately 40 kg) on his shoulder with the weight on both his shoulder and neck, his arm abducted and flexed, his forearm flexed and the hand vertical to help hold goods up. He recalled that it was really painful for the next few days and the pain worsened as he worked, requiring forceful bilateral arm movements with some degree of shoulder elevation. There was no previous medical history of note and in particular no family history of venous thromboembolism or coagulopathy.

On physical examination, the right arm was swollen with moderate enlargement compared to the left, and erythema and venous engorgement was noted. All peripheral pulses were easily palpable. The diagnosis of axillo-subclavian thrombosis was made, while Doppler ultrasound showed thrombosis in the right subclavian and axillary veins. Laboratory tests showed elevated D-dimer.

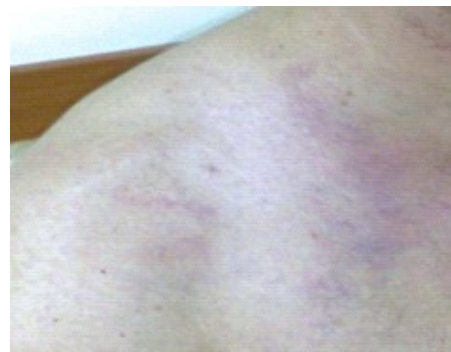

Figure 1. Clinical appearance of right upper extremity of the patient

The patient was put off work and treated with low molecular-weight heparin then warfarin anticoagulation and his signs and symptoms gradually resolved over the next 5 days. A few months later, on subsequent follow-up, he remained well and asymptomatic and repeat venous Doppler ultrasound revealed complete resolution of the thrombosis. One month after the last follow-up, patient returned to work with modified capacity. After 3 months of returning to work, patient resumed his regular duties without impairment or disability.

DISCUSSION

Upper extremity deep vein thrombosis (UEDVT) is a less known and less common phenomenon than lower limb thrombosis, accounting for up to 10% of all deep vein thrombosis (DVT) cases, with an incidence of 1-1.6 per 10,000 population. The axillary and subclavian veins are the sites most frequently affected. Secondary causes account for 80% of cases, most commonly provoked by indwelling central venous catheters.^(1,4) The most common primary cause is Paget-Schroetter syndrome (PSS), commonly known as primary effort thrombosis, which is UEDVT caused by strenuous or repetitive upper limb activity, for which it is sometimes referred to as effort-related thrombosis. Primary effort thrombosis was first described in the literature by James Paget in 1875 and was independently reported again by von Schroetter in 1884, giving UEDVT the name Paget-Schoetter syndrome. Its incidence is 2/100,000 people per year in the United States, equating to approximately 3,000 to 6,000 reported cases yearly.^(7,8) This condition is often referred to as effort thrombosis because 60% to 80% of patients with UEDVT report repetitive and vigorous overhead upper extremity activity, such as swimming, pitching, weight lifting, or even manual or overhead labor, at the onset of symptoms.^(8,9,10) Repetitive strain from vigorous physical activity and compression of the subclavian vein from adjacent anatomic structures

leads to venous injury and subsequent thrombosis. This impedes the venous return from the affected extremity leading to edema. Over time, the body forms collaterals to bypass the venous obstruction. In the chronic phase, the vein becomes fibrotic. Surrounding inflammatory changes from the thrombosis lead to scar tissue formation.⁽⁵⁾ Upper extremity swelling may be present in patients with lymphatic disorders or systemic conditions such as end stage renal disease and congestive heart failure. Upper extremity deep venous thrombosis can be seen with indwelling catheters as well.^(5,11)

A thorough history-taking and an appropriate physical examination are usually sufficient to suggest this diagnosis.⁽¹⁾ The gold standard for diagnosis is contrast venography, but Doppler ultrasonography may be an acceptable alternative, because it is cheap and non-invasive with reported specificity of 96% and sensitivity of 97% for UEDVT.^(7,12) Despite being a known cause of UEDVT, PSS is usually undiagnosed or misdiagnosed mainly due to lack of awareness of the syndrome.⁽¹³⁾

In the case of this worker, he had been working in his normal capacity as a porter. This included forceful right upper extremity activities. He identifies the onset of pain as occurring while lifting heavy goods. It is likely that these physical factors were significant contributing factors to the subsequent thrombosis. The description of the index event causing his subclavian and axillary vein thrombosis is the repeated compression damage of the subclavian vein intima with subsequent fibrosis and activation of the coagulation cascade by repetitive physical activity and prolonged heavy work in the arm, often in an elevated position.⁽¹⁴⁾ Compared with another case in a computer programmer, UEDVT also occurred in this latter worker when the upper extremity was in particular positions such as the rigid military style of sitting with the back straight and the shoulders placed posteriorly and inferiorly.⁽¹⁾

Upper extremity deep vein thrombosis is a deep venous thrombosis and as such the first step

in management is to initiate anticoagulation therapy, typically via an intravenous heparin drip. Duration of anticoagulation in patients with underlying hypercoagulability disorders remains unclear. In most patients, anticoagulation for 3 to 6 months following an episode of deep venous thrombosis is reasonable.^(5,15) The American College of Chest Physicians recommends anticoagulation for a minimum of 3 months for all patients identified with uncomplicated primary UEDVT.⁽¹⁾ In the present case, the patient was treated with oral anticoagulation for 3 months. While UEDVT is a less common phenomenon, much more commonly the condition is reported amongst athletes, but there are surprisingly few reports of specific work-related cases. Pysklywec and Cina⁽⁶⁾ reported on a case in a millwright who had been doing manual lifting, as did Beasley et al.⁽³⁾ in a TV cameraman. Consideration of these occupational tasks suggests that shoulder posture contributes to the condition. In particular, prolonged or forceful elevation of the arm in overhead work is commonly reported in affected workers. It is difficult to understand the relative paucity of occupational cases reported in the literature.⁽⁶⁾

CONCLUSION

This case of UEDVT is a rare upper extremity condition that may be seen in the working population. Occupational medicine physicians should be aware of this condition in the context of manual workers presenting with upper extremity vascular symptoms. Detailed occupational history aids diagnosis and future risk assessment. Repetitive and forceful overhead shoulder activities may lead to scalene swelling or hypertrophy causing subclavian vascular compromise in predisposed workers. Despite a scarcity of occupational cases reported in the literature, effort thrombosis should be recognized as an occupational condition in certain circumstances. Besides, employers and employees need to be educated about the risk of prolonged heavy lifting and about work practices.


CONFLICT OF INTEREST

The authors declare no conflict of interest in this study.

ACKNOWLEDGMENT

We would like to thank all residents of internal medicine of Universitas Indonesia and all the nurses of Fatmawati General Hospital for the opportunity to complete this case report.

CONTRIBUTORS

H contributed to conceptualization, preparing and writing the original draft. DS and MIM contributed to supervision. H contributed to review and editing. All authors have read and approved the final manuscript. 

REFERENCES

1. Chen AW, Oraii Yazdani K, Candilio L. Upper limb deep vein thrombosis: a case report of an increasingly common condition. *J Teh Univ Heart Ctr* 2018;13:73-5.
2. Miao J, Naik G, Muddana S, et al. An uncommon case of lower limb deep vein thrombosis with multiple etiological causes. *Am J Case Rep.* 2017;18:313–6. doi: 10.12659/AJCR.902391.
3. Beasley R, Braithwaite I, Evans R. Upper extremity deep vein thrombosis in a TV cameraman. *Occup Med* 2015;65:337-9. DOI: 10.1093/occmed/kqu212.
4. Bailey CJ, Illig KA. Contemporary management of axillosubclavian vein thrombosis. *Interv Cardiol* 2013;5:453-63.
5. Saleem T, Baril DT. Paget Schroetter Syndrome (Paget Von Schrotter Disease). Treasure Island (FL): Stat Pearls Publishing; 2019.
6. Pysklywec M, Cina CS. Work-related effort thrombosis in a millwright: a case report. *Am J Ind Med* 2011;54:244–7. <http://doi.wiley.com/10.1002/ajim.20888>.
7. Bullock C, Johnston AMD. Upper extremity deep vein thrombosis in a military patient. *J R Army Med Corps* 2016;162:299–301. doi:10.1136/jramc-2015-000418.
8. DeLisa LC, Hensley CP, Jackson S. Diagnosis of Paget-Schroetter syndrome/primary effort thrombosis in a recreational weight lifter. *Phys*

- Ther 2016;97:13–9. <https://doi/10.2522/ptj.20150692>.
9. Ibrahim R, Dashkova I, Williams M, et al. Paget-Schroetter syndrome in the absence of common predisposing factors: A case report. *Thromb J* 2017;15:20. doi: 10.1186/s12959-017-0146-0.
 10. Keene DJ. Upper extremity deep vein thrombosis (Paget-Schroetter syndrome) after surfing: a case report. *Man Ther* 2015;20:358–60. doi: 10.1016/j.math.2014.08.004.
 11. Delluc A, Le Mao R, Tromeur C, et al. Incidence of upper-extremity deep vein thrombosis in western France: a community-based study. *Haematologica* 2019;104:e29–31. doi: 10.3324/haematol.2018.194951.
 12. Sayin A, Güngör H, Bilgin M, Ertürk Ü. Paget-von Schrötter syndrome: Upper extremity deep vein thrombosis after heavy exercise. *Türk Kardiyol Dern Ars* 2012;40:354–7. <http://dx.doi.org/10.12687/phleb2256-4-2015>.
 13. Sharma H, Tiwari A. Recurrent upper extremity thrombosis associated with overactivity: a case of delayed diagnosis of Paget-Schroetter syndrome. *Case Rep Vasc Med* 2017;2017: 8764903. doi: 10.1155/2017/8764903.
 14. Noyes AM, Dickey J. The arm is not the leg: pathophysiology, diagnosis, and management of upper extremity deep vein thrombosis. *RI Med J* 2017;100:33-6.
 15. Engelberger RP, Kucher N. Management of deep vein thrombosis of the upper extremity. *Circulation* 2012;126:768–73. <https://doi.org/10.1161/CIRCULATIONAHA.111.051276>.