

LIGATION OF INTERSPHINCTERIC FISTULA TRACT AS AN ALTERNATIVE TREATMENT FOR PERIANAL FISTULA AT TERTIARY CARE HOSPITAL

Nawaz Ali Dal¹, Ishrat Raheem Katyar¹, Mohammad Qasim Mallah¹, Ahsan Laghari¹, Shiraz Shaikh¹, Abdul Ghafoor Dalwani¹

¹Department of Surgery, Liaquat University of Medical and Health Sciences, Jamshoro, Pakistan

Correspondence:

Nawaz Ali Dal
Department of Surgery, Liaquat University of Medical & Health Sciences, Jamshoro,
Pakistan
Email:
drnawazdal001@gmail.com

DOI:
10.38106/LMRJ.2021.3.03-02

Received: 09. 06.2021
Accepted: 28. 08..2021
Published: 30. 09.2021

ABSTRACT

This study was aimed to evaluate clinical outcome of patients with perianal fistula operated with the ligation of intersphincteric fistula tract (LIFT) technique. The study was conducted at Department of Surgery, Liaquat University of Medical & Health Sciences, Jamshoro from July 2018 and August 2019. A total of 22 patients diagnosed with perianal fistula operated with the Ligation of Intersphincteric Fistula Tract (LIFT) technique were selected using non-probability consecutive sampling technique. Physical examination and magnetic resonance imaging (MRI) and/or endosonography (ES) were performed to make a confirmed diagnosis of fistula. They were classified according to Parks classification. All patients were subjected to intersphincteric fistulous tract ligation using the technique defined by Rojanasakul modified. There were 16 males and 6 females. Mean age was 42 years (range 23-68 years of age). Out of 22 patients, 17 patients had a history of perianal abscess drainage prior to surgery and an average preoperative symptom presentation was 2.2 years (range 0-10 years). Therapeutic success with first surgery was achieved in 77% and with a second surgery in 90%. None of this patients modified their preoperative Wexner. It was concluded that LIFT technique appears to be a convenient, reproducible, and effective surgical alternative. This provides an appropriate closing rate and without continence modification, Therefore indicated for complex cryptoglandular fistulas.

Key Words: Ligation of intersphincteric fistula tract (LIFT); perianal fistula; magnetic resonance imaging; endosonography; fistulotomy.

INTRODUCTION

Anorectal fistula represents the chronic phase of anorectal abscess and is defined as the persistence of a fibrous path covered by granulatory tissue between an internal primary hole and one or multiple external secondary holes in the skin of the perianal region, clinically resulting in fouling, wet anus, cyclic perianal pain and chronic drainage of associated purulent material, abscess formation and intermittent spontaneous drainage.¹ Its origin is cryptoglandular in about 90% of cases and in the remaining it is due to other conditions such as Crohn's disease, local radiation, cancer and trauma. The cryptoglandular theory is based on the constant exposure of fecal load in the internal fistulous orifice associated with the tightness of the path, ultimately causing the septic focus to be perpetuated.²

The surgical treatment of the fistula is basically aimed at achieving healing of the fistulous tract without altering function of the anal sphincter and avoiding the recurrence of the path as much as possible.³ The literature shows a variety of surgical techniques for resolution of the complex fistulas, although some achieve efficient control of the disease, with an average recurrence of 5%. However incontinence resulting from procedures range between 10% and 57%.⁴

Currently, the best surgical alternative in complex anorectal fistula is being sought, unfortunately the evidence is low, given the series reported are heterogeneous, with variable and short post-operative follow-up.⁵ Classical techniques such as fistulotomy and the seton or cutting line technique have a recurrence rate of up

to 9%, causing variable deterioration of anorectal function with the figures already described. Fecal incontinence is one of the main problems of fistula treatment, since in both techniques the internal anal sphincter is sectioned.⁶

When considering aspects related to preservation of sphincter continence and rate of recurrence new techniques have been brought in order to solve the problem. Such as biological sealants have emerged (ie. Fibrin Glue Injection), use of caps of different materials, advanced therapies related to the use of Stem Cells and novel surgical techniques including LIFT.⁷

The LIFT fundamentally considers ligation and excision of the intersphincteric path, managing to block the entry of fecal material into it, eliminating the chronic cryptoglandular septic sinus.⁸ The technique contemplates the preservation of both anal sphincters, an aspect that almost completely reduces the risk of incontinence.⁹ The first report of this technique was a Thai experience developed by Rojanasakul et al.,¹⁰ In 2007, as a modification to the technique described by Matos et al. where the description of this technique was made in 18 patients with a rate of success as 94%, without reporting alterations in continence. Since then, other authors have published their experiences with success rates in relation to cure between 47% and 95%, not forgetting the real benefit regarding the maintenance of fecal continence.^{8,9}

One of the most important bias identified in systematic reviews was the variability detected in the technique with respect to the classic LIFT. In addition, hybrid LIFT techniques have been incorporated with the combined use of biomaterials, which makes evaluating the potential of the technique even more complex. The objective of this study was to present our results in terms of clinical efficacy and incontinence with the LIFT technique and to enhance its role as a treatment alternative for anorectal fistula.

METHODOLOGY

This study was conducted at department of Surgery, Liaquat University of Medical & Health Sciences, Jams-horo, from July 2018 and August 2019. Twenty-two patients diagnosed with perianal fistula operated with the LIFT technique were selected using non-probability consecutive sampling technique. Patients included in this study were informed of the procedure to be performed and the possible complications of the procedure. Detailed written informed consent for the operation was obtained from the hospital treatment chart. This study was approved by local Ethics Committee.

A physical examination and magnetic resonance imaging (MRI) and/or endosonography (ES) were performed to confirm diagnosis of fistula. They were classified according to Parks classification¹¹. Complex fistulas identified as medium and high trans-sphincter were exclusively included, depending on the proportion of external anal sphincter involved (> 30%) and anterior fistulas in women. Patients with fistulas whose origin was not cryptoglandular were excluded. Colonoscopy was performed on all patients to rule out Crohn's disease. All patients were subject to LIFT using the technique defined by Rojanasakul modified¹⁰.

Surgical procedure

The procedure was carried out under regional anesthesia. Curved incision in the intersphincteric space over the path of the fistula was made and dissected until it was released. Ligation and cutting of the fistula was done, curettage of the distal path and enlargement of the external orifice (OFE) was performed. The modified technique included curettage of the proximal path with gauze and invagination of the ligation ends with resorbable material. The internal orifice (OFI) was not closed (modification proposed in other series) due to the theoretical risk of a new abscess. Demographic and clinical data were recorded in a prospective database, all patients had a preoperative clinical evaluation and an average postoperative follow-up of 48 weeks. Clinical success was defined as the absence of symptoms and signs of fistula within 3 months of surgery. Incontinence was measured and classified by the Wexner scale¹².

Statistical methods

Data was recorded and analysed by using Statistical Package for Social Sciences (SPSS version 22.0). Mean of the continuous variables is presented along with range and frequency distribution was presented for categorical variables.

RESULTS

Out of 22 patients underwent surgery for perianal fistula using the LIFT technique, 16 were males and 6 were females, as shown in Figure 1. The mean age was 42 years ranging between 23 and 68 years. 18 patients were ASA I and 4 ASA II while 17 patients had a history of perianal abscess drainage prior to surgery and mean preoperative symptom presentation was 2.2 years (range 0-10 years). In 16 patients, it was decided to install a non-cutting seton prior to final surgery. This was done in order to manage the infectious part of the fistula and to obtain a more fibrous path. Mean time between seton and LIFT was 60 days.

The LIFT was performed on 6 patients without prior settling. In the preoperative study, 20 patients underwent enhanced contrast pelvic MRI and 1 endosonography as described in Table 1. Twenty patients had a Wexner score of 0 points and 2 of 1 point in the preoperative assessment. Mean duration of surgical procedure was 39.7 minutes. All patients received a prophylactic antibiotic with 1 gram IV ceftriaxone and 500 mg IV metronidazole. None of the patients had intraoperative complications and all were discharged 24 hours post-operatively. At discharge, all patients were given oral antibiotics for 7 days (ciprofloxacin 500 mg every 12 hours and metronidazole 500 mg every 8 hours), pain relievers and nonsteroidal anti-inflammatory drugs for 3-5 days.

An average follow-up of 48 weeks was performed with a range of 24 to 96 weeks. Complete closure was achieved in 77% (n=17 patients). In postoperative follow-up, fistula recurrence was observed in 5 patients (23%) with a simpler fistula. All of them underwent fistulotomy along the way. After this second intervention, 90% clinical success was obtained in the follow-up. None of the 5 cases had reported any incontinence. No patient out of 22 has modified their Wexner at follow-up as shown in Table 2.

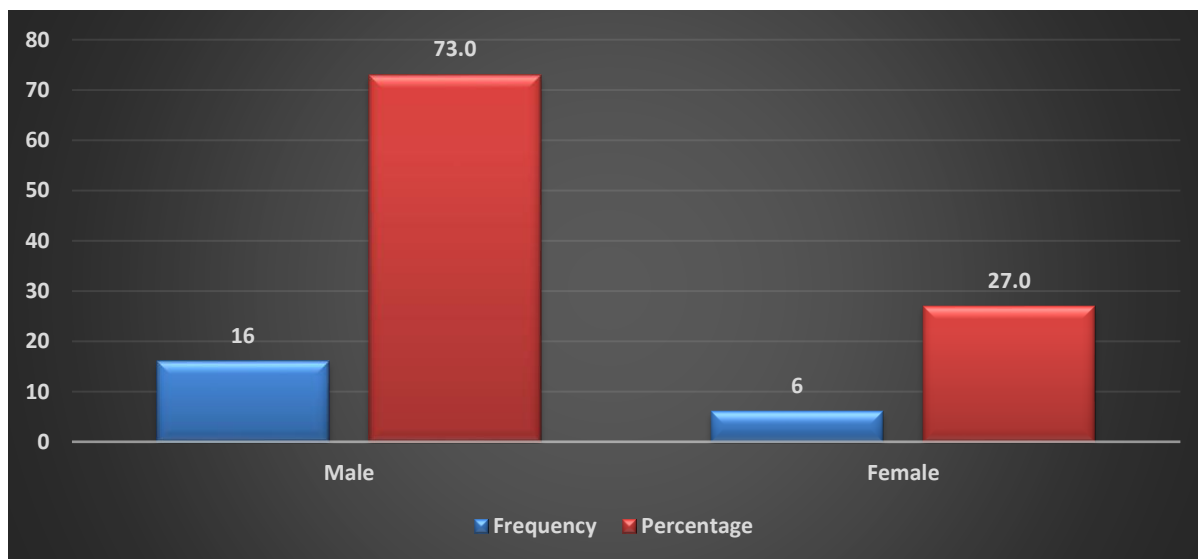


Figure 1. Distribution of the Gender of the patients included in the study

Tables 1. Characteristics of the study patients (n=22)

CHARACTERISTICS	NO. (% OR RANGE)
Mean age	42 years (23-68 years)
Mean symptoms time	2.2 years (0-10 years)
Previous abscess drainage	17
Fishing line 60 days prior	16
MRI-endosonography	20-2

Table 2. Summary of results (n=22)

Operated	22 patients
Mean operating time	39.7 minutes
ATB prophylaxis	22
Mean days of hospitalization	one
Mean postoperative EVA - High	0-1
Early complications	0
Tracing	48 weeks (24-96 weeks)
Full closure	In 2 stages *77% (17/22 patients)90% (20/22 patients)
Recurrence (all were treated with a simple fistulotomy)	23% (5 patients with OFE secretion, down staging)
Recurrence and previous line	4/5 had no line **
Wexner Modification	0

* After the first LIFT, primary closure was obtained in 77% of the cases, 90% of closure was achieved after a second intervention in the relevant cases. ** Recurrence occurred in 4 out of 5 patients, in whom a seton was not positioned in the first fistulotomy.

DISCUSSION

For a long time, the anal rectus mucosa advancement flap was considered the gold standard for the surgical treatment of complex fistulas with retention of sphincter function, showing success rates between 27-100%, but with incontinence rates of up to 35%^{8,9}. Precisely in order to improve these results, the LIFT procedure has recently emerged as an attractive alternative for the surgical treatment of complex anorectal fistulas. Its principle is to treat the fistula and its origin without compromising the apparatus of the sphincter. It presents a final closing rate of 47% to 94% in different reported series, with no continence commitment in any of these series¹³. Other advantages of the procedure are low postoperative pain, quick reintegration into the workplace and lower economic costs compared to other techniques requiring the use of biological materials. Reviewing the literature, there is only one national publication on the subject, from the Bahawal Victoria Hospital Bahawalpur Pakistan. This work shows an experience in 30 patients subjected to ligation of Intersphincteric fistula tract. Twenty-five (83%) patients were cured and only five (17%) patients had fistula recurrence and were thus considered as not cured. None of the patient was presented with incontinence¹⁴.

The present study shows similar results of those who experienced the LIFT treatment, recorded in the literature. While the number of patients was small, the proportion of patients who had an indication to fistulotomy or other non-surgical procedures for a complicated and alternative treatment was similar to that. It should be noted that during the study period, 240 fistulas were operated at the main study center (Department of Surgery at Liaquat Univeristy hospital, LUMHS Jamshoro), of which only 22 (9%) were operated in

the LIFT; this indicates that the option of performing the technique is very limited and is not currently one of preferred techniques of colorectal surgeons.

In relation to the patients in the present case, as in the series of patients with perianal fistula of cryptoglandular origin, these occur at intermediate ages, without significant comorbidities, and an outpatient procedure can be provided comfortably, with regional anesthesia, without greater analgesic requirements and with rapid functional and occupational recovery. No patient without recurrence had to consult urgently when monitoring patients during the postoperative period and all were able to control their surgery-related discomfort with the indications provided at discharge¹⁵.

Analyzing the findings, considering the closure of the fistula as the main goal, this series indicates a closure of 77% only with the LIFT treatment and if we find closure in two stages after a more basic (intersphincteric) recurrence, the closure rate is close to 90% (20 out of 22 patients), with 100% of them without sphincter continence modification, which is the main objective.

When analyzing the recurrence cases (ie 5 patients, which makes only 23% of the total), 4 of them had a recurrence that was intersphincteric, as the literature indicates as a "downstaging" of a complex process in which the recurrence corresponds to the most frequent, proximal portion of the fistula, and that a simple fistulotomy can show good results and protection in the sphincter can be solved in a second period.

It is interesting that most primary success patients have previously installed a line, indicating that previous drainage and pathway conduction may affect the success of fistula healing, but the literature is not categorical in this regard, given the limited number of cases, and this variable cannot be assigned a meaning. Neither can we assume that the modifications in the procedure affect the success rate, but we postulate that the installation of a line in advance, the curettage with gauze of the fistulous tract, the closure of the internal orifice and the invaginating muscle plasticity of the ends of the ligation may impact better healing of the closure by decreasing the risk of recurrence.

CONCLUSION

In conclusion, the LIFT technique appears to be a convenient, reproducible, and effective surgical alternative. This provides an appropriate closing rate and without continence modification, so we suggest it as a good option for cryptoglandular fistulas.

Ethical Consideration: The study was approved by Ethics Committee of Liaquat University of Medical & Health Sciences, Jamshoro, Pakistan

Conflict of Interest: There is no conflict of interest.

Funding: This study was not funded by any agency

REFERENCES

1. Whiteford M. Perianal Abscess/Fistula Disease. *Clin Colon Rectal Surg.* 2007 May;20(2):102–9.
2. Burney RE. Perianal abscess. In: *Clinical Scenarios in Surgery: Decision Making and Operative Technique.* Wolters Kluwer Health Adis (ESP); 2012. p. 229–34.
3. Fung A, Card G, Ross N, Yule S, Aly E. Operative strategy for fistula-in-ano without division of the anal sphincter. *Ann R Coll Surg Engl.* 2013 Oct;95(7):461–7.
4. Williams G, Williams A, Tozer P, Phillips R, Ahmad A, Jayne D, et al. The treatment of anal fistula: second ACPGBI Position Statement - 2018. *Color Dis.* 2018 Jul;20:5–31.
5. Adegbola S. Medical and surgical management of perianal Crohn's disease. *Ann Gastroenterol.* 2018;
6. Bubbers E, Cologne K. Management of Complex Anal Fistulas. *Clin Colon Rectal Surg.* 2016 Feb 16;29(01):043–9.
7. Limura E. Modern management of anal fistula. *World J Gastroenterol.* 2015;21(1):12.

-
8. Vergara-Fernandez O. Ligation of intersphincteric fistula tract: What is the evidence in a review? *World J Gastroenterol.* 2013;19(40):6805.
 9. Hong KD, Kang S, Kalaskar S, Wexner SD. Ligation of intersphincteric fistula tract (LIFT) to treat anal fistula: Systematic review and meta-analysis. *Tech Coloproctol.* 2014;18(8):685–91.
 10. Rojanasakul A, Pattanaarun J, Sahakitrungruang C, Tantiphlachiva K. Total anal sphincter saving technique for fistula-in-ano; the ligation of intersphincteric fistula tract. *J Med Assoc Thai.* 2007;90(3):581–6.
 11. Barredo C, Leiro F. Abscesos Y Fístulas Perianeales. *Cir Dig.* 2009;
 12. Claudio Wainstein G, Rodrigo Quera P, Maria Isabel QG. Incontinencia fecal en el adulto: Un desafío permanente. *Rev Médica Clínica Las Condes.* 2013 Mar;24(2):249–61.
 13. Scoglio D, Walker A, Fichera A. Biomaterials in the Treatment of Anal Fistula: Hope or Hype? *Clin Colon Rectal Surg.* 2014 Nov 10;27(04):172–81.
 14. Ch MS, Khan MI, Anwar M. Effectiveness of the ligation of intersphincteric fistula tract in the treatment of high lying perianal fistula. pdfs.semanticscholar.org.
 15. Holzheimer RG, Siebeck M. Treatment procedures for anal fistulous cryptoglandular abscess - How to get the best results. Vol. 11, *European Journal of Medical Research.* 2006.