

Encysted Hydrocele of Canal of Nück

Fadhil Ahmmed Mohialdeen¹, Muhammed Babakir-Mina^{1*}, Mohammed Ibrahim Mohialdeen Gubari¹

¹Department of Community Health, Sulaimani Polytechnic University, Sulaimani, Kurdistan Region, Iraq.

*Corresponding Author: babakir-mina@spu.edu.iq

Received | November 22, 2015

Accepted | January 17, 2016

Abstract

The canal of Nuck is analogous to a patent processus vaginalis in a male, which normally loses its communication to the peritoneal cavity within the first year of life. Failure of obliteration of this tract can result in a hydrocele. We present a case of 38 years old lady referred to our surgical unit from Gynecologist as left obstructed femoral hernia. A fluid filled sac (Encysted Hydrocele of Canal of Nück) with small indirect inguinal hernia.

Key words: Inguinal hernia, Hydrocele, herniorrhaphy, and Canal of Nück

Introduction

The canal of Nuck in female is analogous to the processus vaginalis of the male, and it is named after Anton Nuck, the 17th century Dutch anatomist. During embryological development the vaginalis processes is a peritoneal invagination into the inguinal canal and in the female it accompanies the round ligament or the gubernaculum. In both sexes it obliterates completely by the first year of life. When it fails to obliterate completely, it can result either in a congenital hernia or a hydrocele (Jedrzejewski et al., 2008).

The canal of Nuck is the persistence of the small processus vaginalis which usually obliterates and disappears long before birth. It is homologous to hydrocele of the spermatic cord in male and has been a rare cause of inguinal canal swelling in women (Stickel et al., 2004). Normally the

hydrocele of the canal of Nuck presents as a painless, translucent, irreducible lump in the groin. However the overlying fascia of external oblique may not allow transillumination.

Case report

A 38 years- old lady was referred to our surgical unit from Gynecologist as left obstructed femoral hernia. On examination there was a tender a swelling of the left inguinal region, tense, irreducible, but above the inguinal ligament. She had history of three years of this swelling. Inguinal exploration was performed and the findings were as follows:

A fluid filled sac (Encysted Hydrocele of Canal of Nück) with small indirect inguinal hernia. Excision of the sac was performed completely with the round ligament of the uterus, then inguinal herniorrhaphy with obliteration and

closure of the internal inguinal ring closure of the fascial layers was performed successfully without drain (Figure 1). The patient discharged home on the same day evening uneventfully.

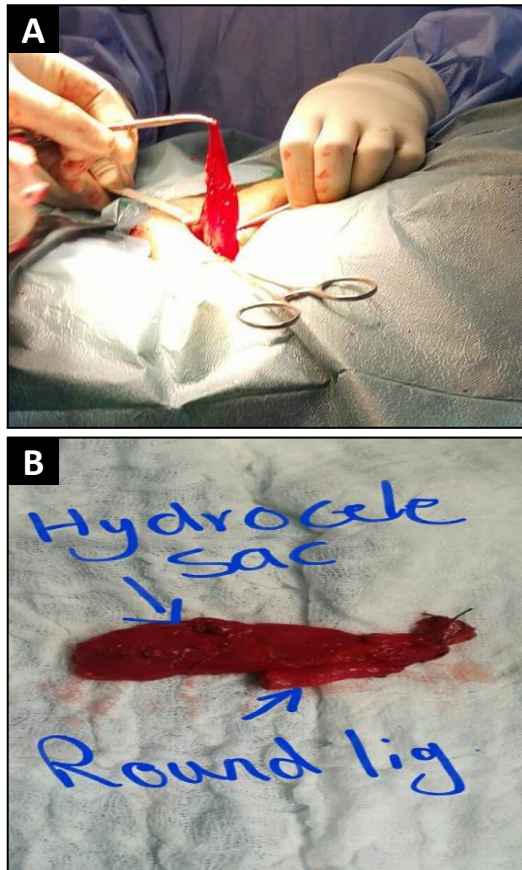


Figure 1: A) The female hydrocele. B) The cyst with the round ligament.

Discussion

During fetal development in the male, the testicle descends through the inguinal canal into the scrotum pulling along a sac-like extension of the peritoneum. By the first year of life, this extension condenses into a fibrous cord—the processus vaginalis, preventing the communication of peritoneal cavity with the scrotum. A thin membrane of this original extension remains surrounding the testicle which is named the tunica vaginalis. If this extension of peritoneum fails to close, based on the size of the defect, fluid or

abdominal contents may enter the inguinal canal, resulting in a hydrocele or hernia. Congenital hernia or hydrocele, though more common in males, is rarely seen in females. In the female fetal development, round ligament of the uterus descends into the inguinal canal to the labium major.

The peritoneal fold that descends the round ligament is named the canal of Nück. The canal of Nück cyst is thin walled, contains clear fluid and is lined by cuboidal or flattened mesothelial cells. Normally the hydrocele of the canal of Nück presents as a painless, translucent, irreducible lump in the groin. However, the overlying fascia of external oblique may not allow transillumination.

If by the first year of life this communication fails to close, it can also result in an indirect hernia or a hydrocele (Sternberg, 1999). The differential diagnosis for an inguinal mass in a female includes indirect hernia, lymphadenopathy, Cold abscess, Bartholin's cyst, post-traumatic hematoma, rarely cystic lymphangioma, neuroblastoma metastasis in groin and ganglion (Pandit et al., 2000, and Poenaru et al., 1999).

There are three types of a hydrocele of canal of Nück. The most common type is one with no communication with peritoneal cavity forming an encysted hydrocele along the tract of descent, from the inguinal ring to the vulva. Second type results when there is a persistent communication with the peritoneal cavity. A third type is a combination of the two as a result of the inguinal ring constricting the hydrocele like a belt so that part is communicating and part is enclosed, giving this the name of hour glass type.

However, any of these types of hydroceles are extremely rare in females (Counseller and Black, 1941). Hydroceles are more common in males probably because of the differences in migration of the gonads. A hydrocele can result from either a persistent patency of the processus vaginalis with peritoneal communication as in this patient, or with proximal obliteration at the deep ring with over-secretion and under-absorption in the distal segment. The canal of

Conclusions

The curative treatment of this condition is surgical excision of the cyst with closure of the neck at the deep ring.

References

- Counseller VS, Black BM (1941). Hydrocele of the Canal of Nuck: Report of Seventeen Cases. *Ann Surg.* (113) 625–30.
- Jedrzejewski G, Stankiewicz A, Wiczorek AP (2008). Uterus and ovary hernia of the canal of Nuck. *Pediatr Radiol.* (38) 1257–8.
- Pandit SK, Rattan KN, Budhiraja S, Solanki RS. (2000). Cystic lymphangioma with special reference to rare sites. *Indian J Pediatr.* (67) 339–41.
- Poenaru D, Jacobs DA, Kamal I (1999). Unusual findings in the inguinal canal: A report of four cases. *Pediatr Surg Int.* (15) 515–6.
- Stickel WH and Manner M (2004). Female Hydrocele (Cyst of the Canal of Nuck) Sonographic appearance of a Rare and Little-Known Disorder. *MDJ Ultrasound Med* (23) 429–32.
- Sternberg SS (1999). *Diagnostic surgical pathology*, 3rd edn. Philadelphia: Lippincott, Williams and Wilkins.