



REVIEW

Hepatocellular Carcinoma: A Review

Tarana Gupta

Department of Medicine, Pt. B.D. Sharma Post Graduate Institute of Medical Sciences, Rohtak, Haryana, India

Abstract

Hepatocellular carcinoma (HCC) is one of the leading causes of cancer-related death worldwide. Chronic liver disease due to viral hepatitis, alcohol, non-alcoholic fatty liver disease, etc are risk factors for HCC development. Triphasic contrast-enhanced computed tomography (CECT) and magnetic resonance imaging (MRI) abdomen are modalities for HCC diagnosis best for lesions >2 cm size. For lesions <2 cm size, liquid biopsy with the determination of cell-free DNA in the blood is a newly emerging technique for diagnosis as well as for the planning of molecular targeted therapy. With the new concept of “Treatment stage migration”, the updated Barcelona clinic liver cancer (BCLC) algorithm for HCC management allows the best treatment modality for an individual patient. In addition to definitive therapy of resection and liver transplantation, palliative therapies like ablation, transarterial embolization, and others can be used. Among molecular targeted therapies for advanced BCLC stage C HCC, lenvatinib as first line, regorafenib and cabozantinib as second line therapy have been approved recently. The checkpoint inhibitors (CPIs), nivolumab and pembrolizumab, have revolutionized oncology practice in other solid organ cancers and have shown promising results in HCC management.

Keywords: Barcelona clinic liver cancer; checkpoint inhibitors; hepatocellular carcinoma; liver transplantation

Received: 23 August 2020; *Accepted after Revision:* 11 September 2020; *Published:* 18 September 2020

Author for correspondence: Dr. Tarana Gupta, MD DM Hepatology, Professor, Department of Medicine, Pt. B.D. Sharma Post Graduate Institute of Medical Sciences, Rohtak, Haryana, India. Tel.: +91-99140 48899. Email: taranagupta@gmail.com

How to cite: Tarana Gupta. Hepatocellular carcinoma: A review. *J Ren Hepat Disord.* 2020;4(2): 51–60

Doi: <https://doi.org/10.15586/jrenhep.v4i2.84>

Copyright: Tarana Gupta

License: This open access article is licensed under Creative Commons Attribution 4.0 International (CC BY 4.0). <http://creativecommons.org/>

Background

Liver cancer has sixth ranking in new incident cancer cases all over the world and is the fourth leading cause of cancer-related deaths (1). The liver may have primary as well as metastatic involvement due to carcinoma. Overall, hepatocellular carcinoma (HCC) is the most common primary liver cancer. The highest worldwide prevalence is in China and Mongolia, followed by intermediate prevalence in central Europe and the lowest prevalence in North and South America, the Middle East, and Northern Europe. Variable prevalence exists in different parts of India. Asia contributes to about 75% of all liver cancer patients, out of these almost

50% of cases originate in China, due to the high prevalence of chronic hepatitis B (CHB).

Chronic liver disease is an important risk factor for HCC development. CHB, chronic hepatitis C (CHC), and alcoholic liver disease used to be the leading causes of HCC. Among viral-related causes, hepatitis B virus (HBV) is responsible for 75–80% of cases and hepatitis C virus (HCV) for 10–20% of cases (2). Hepatitis delta virus infection increases the risk of HCC in CHB patients. Universal immunization for HBV and highly effective direct-acting antivirals (DAAs) in HCV are expected to decrease the proportion of patients with HCC due to viral causes.

The emerging epidemic of metabolic syndrome and obesity has rapidly increased the prevalence of non-alcoholic fatty liver disease (NAFLD), which might become the leading cause of HCC in the near future as shown in liver transplant registry data from Western countries (3). The rising incidence of metabolic syndrome and NAFLD in Asian countries has also shown an increasing prevalence of HCC due to NAFLD. A study from Taiwan reported obesity having a four-fold increased risk of HCC in patients with CHC and two-fold risk of HCC in patients without viral infection. They also documented diabetes with two to three-fold increased risk of HCC development irrespective of viral infections (4). Almost 5–30% HCCs have no identifiable cause and are classified as cryptogenic HCC. The presence of metabolic syndrome, diabetes, obesity, and dyslipidemia in past suggest for burnt-out non-alcoholic steatohepatitis (NASH) (5, 6). Other risk factors for HCC are aflatoxin exposure, α 1-antitrypsin deficiency, tyrosinemia, hepatic porphyrias, etc.

Molecular Pathogenesis

Chronic liver disease (CLD) is associated with inflammation, fibrosis, and cirrhosis. The ongoing inflammation, injury, repair, and regeneration are responsible for the activation of genetic and epigenetic mechanisms of neoplasia resulting in the formation of dysplastic nodules which are precancerous lesions with high susceptibility to develop into HCC. HCC develops at a rate ~3.5% per year and an average 10 years median time is needed for the development of HCC in cirrhosis (7). Various somatic genetic and epigenetic mutations telomerase reverse transcriptase (TERT), catenin beta-1 (CTNNB1), axis inhibition protein 1 (AXIN1), tumor protein 53 (TP53), AT-rich interaction domain 1A (ARID1A), and ARID1B occur in CLD patients leading to activation of hepatocarcinogenic pathways like wntless-related integration site (WNT)- β -catenin signaling, receptor tyrosine kinase (RTK)-RAS-phosphatidylinositol 3-kinase (PI3K) cascades, oxidative stress, telomere shortening, and chromatin modification (8–12). Unlike in other solid tumors, no single gene mutation is responsible for HCC. This is why targeted molecular therapy for HCC has not been developed to date. HCC can also occur in the non-cirrhotic liver like in HBV infections, NASH, and uncommonly in benign lesions like hepatocellular adenomas (HCAs). TERT and CTNNB1 mutations have been documented to be associated with malignant transformation in <10% of HCAs (13). Almost 80% of HCC develop from mature hepatocytes; however, ~20% may develop from hepatic progenitor cells or dedifferentiated hepatocytes (14).

Molecular Classifications

Researchers all over the world have done extensive genomic, epigenomic, and transcriptomic profiling of resected tumors

to understand the tumor biology. Based on these findings, a molecular classification of HCC has been proposed which has clinical and prognostic implications as well as it may guide in the selection of therapeutic modality. Two classes proliferative and non-proliferative have been suggested. The proliferative class has chromosomal instability with more prevalence of TP53 inactivation, cyclin D1 (CCND1), and fibroblast growth factor 19 (FGF19) amplifications leading to activation of RAS-MAPK (mitogen activated protein kinase), phosphatidylinositol-3-kinase (PI3K)/Akt and the mammalian target of rapamycin (mTOR) and tyrosine-protein kinase Met signaling pathways affecting cell proliferation and survival. Two subclasses S1 and S2 based on their pathways and gene activation have been proposed. HBV-related HCC belongs to the proliferative class with poor outcomes (Figure 1).

The non-proliferative class has three subclasses with more heterogeneity. It is associated with HCV and alcoholic liver diseases. The canonical pathway of WNT-signaling and β -catenin mutation is characteristically involved in non-proliferative tumors.

As a part of “The Cancer Gene Atlas” (TCGA) research network, Wheeler et al. (15) performed a comprehensive integrated analysis of resected specimens of HCC among 363 patients which included six data platforms DNA exome sequencing, DNA methylation, mRNA expressions, miRNA expressions, copy number data, and proteomics to understand the molecular landscape of HCC. The aim was to understand the clinical correlation with mutations and molecular markers, prognostication of various molecular classes, and for identification of therapeutic targets based upon immunogenetics.

Chronic liver disease is associated with chronic inflammation with immune cell infiltration which over a long period increases the risk of HCC. Sia et al. (16) have suggested a novel immune-based classification of HCC. It comprises “Immune HCC” in ~30% HCC with increased immune cell infiltration like cytotoxic T cells, macrophages, etc. associated with increased expression of programmed cell death receptor 1 ligand 1 (PD-L1), PD-1, and IFN- γ signal and “Immune excluded” in ~25% HCC with less chromosomal aberrations and decreased immune cell infiltration with CTNNB1 mutation (16). Immune HCC class is further subdivided into “active immune” and “immune exhausted” classes. The immune HCC and immune excluded HCC classes overlap with proliferative and non-proliferative classes, respectively. However, 45% of HCC lie in the immune intermediate class at present due to their indeterminate genetic signatures. The immune-based classification may guide us for the development of immune checkpoint inhibitors (CPIs) for HCC in future.

Surveillance

Curative therapies like transplant and resection are recommended only for early-stage HCC with 5-year survival

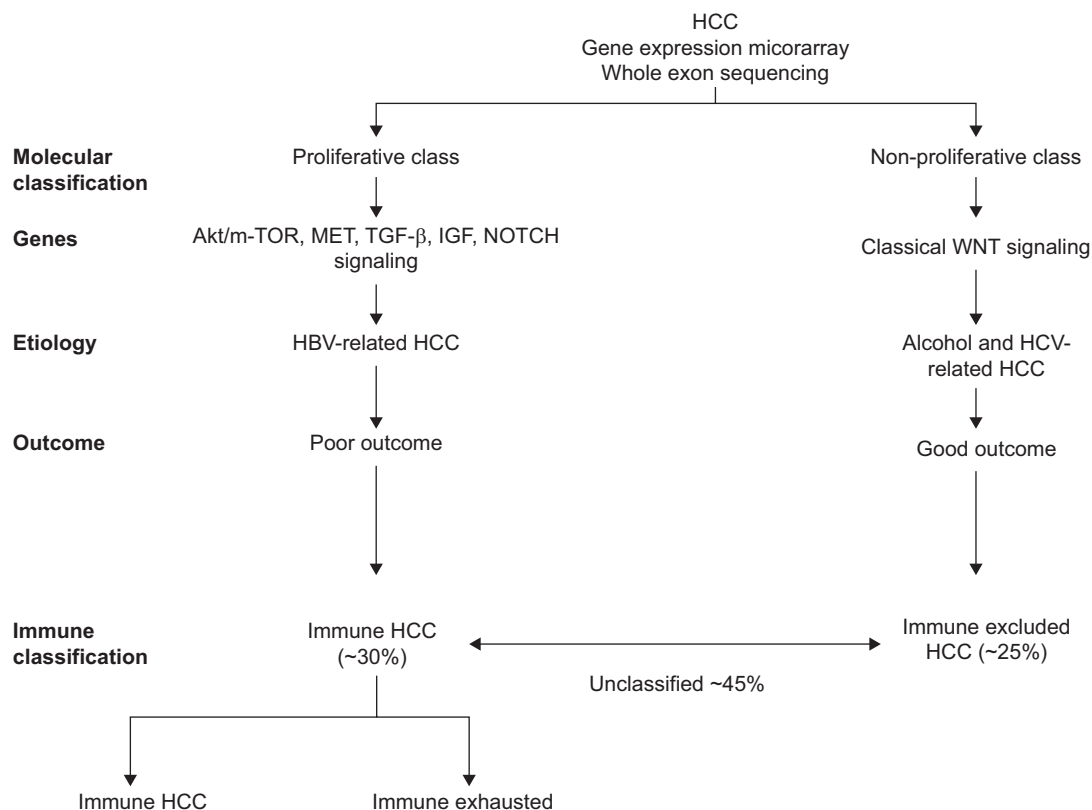


Figure 1: Molecular classification of HCC. Proliferation and non-proliferation class are characterized by mutations in different genes and associated with patients’ outcomes.

rates of 70% whereas only palliative treatment is possible for intermediate and advanced stage HCC with a median survival of 1–3 years. Chronic liver diseases pose a risk for HCC by chronic inflammation, fibrosis, and cirrhosis. CHB has a higher risk among males, African <40 years, with advanced fibrosis or cirrhosis (3–8% per year) and with a positive family history of HCC. Cirrhosis due to HCV (3–5% per year), NASH, alcohol, primary biliary cholangitis with stage 4 fibrosis, Wilson’s disease, hemochromatosis, and α 1-antitrypsin deficiency are other risk factors. Singal et al. (17) in a meta-analysis for HCC surveillance in patients with cirrhosis showed improvement in the detection rate of early-stage HCC (Odds ratio [OR] 2.08, 95% confidence interval [CI] 1.80–2.37), higher treatment rate (OR 2.24, 95% CI 1.99–2.52), and better survival (OR 1.90, 95% CI 1.67–2.17). HCC surveillance has uncertain benefits in HCV with stage 3 fibrosis, young HBV carriers’ Asian males <40 years and females <50 years, and NAFLD without fibrosis. American Association for the study of Liver Disease (AASLD) and European Association for Study of the Liver (EASL) guidelines jointly recommend HCC surveillance with ultrasonography (USG) and

alpha-fetoprotein (AFP) levels 20 ng/mL at regular intervals preferably every 6 months in cirrhosis of the liver to be cost-effective. Computed tomography (CT) or magnetic resonance imaging (MRI) scan at present is not recommended for HCC surveillance as they are not cost-effective and it is impractical to repeat them periodically except when ultrasound is inadequate (18). Park et al. (19) have shown limited non-enhanced MRI (Diffusion weighted imaging with T2; diffusion restriction with T2 hyperintensity) to be better than USG for HCC surveillance with higher sensitivity (79% vs 28%), comparable specificity (98% vs 94%), higher positive predictive value (62% vs 17%), and comparable negative predictive value (99% vs 97%). They showed limited MRI imaging having a study time duration of 6 min with room occupancy time of 15–25 min as compared to 10–15 min for USG. On the other hand, Labgaa et al. (20) have recently demonstrated the presence of cell-free DNA (cfDNA) in plasma samples of patients with HCC for detecting somatic mutations in tumor tissues as a new minimally invasive method for determination of HCC genetics. The new technique called “Liquid biopsy” holds great promise in future for diagnosing HCC especially in lesions

<2 cm in size, predicting the prognosis of the lesion based upon certain genetic mutations and better selection of therapeutic modality based upon immunogenetics (21, 22).

Diagnosis

Hepatocellular carcinoma classically arises from dysplasia of cirrhotic nodules (Figure 2). During the dysplasia, the vascular supply dominantly becomes arterial and with malignant transformation, there is the formation of arteriportal fistulas. The liver imaging by CT/MRI scan shows hyperenhancement of HCC during the arterial phase due to rapid fill-in of intravenous contrast and rapid washout of contrast during the portal venous phase when the rest of the liver shows enhancement which becomes more pronounced during delayed venous phases. A recent meta-analysis by Roberts et al. (23) has demonstrated higher sensitivity (0.82 vs 0.66), comparable specificity (0.91 vs 0.92) with lower negative likelihood ratio (0.20 vs 0.37), and comparable positive likelihood ratio (8.8 vs 8.1) for triphasic contrast MRI and CT scan, respectively. However, MRI for <1 cm size nodule had higher sensitivity (0.69 vs 0.49) and lower specificity (0.46 vs 0.69) than a CT scan. On the other hand, MRI should not be the first choice for patients with ascites (artefacts), poor breath-hold (artefacts), and decompensated liver disease (poor gadoxetate sodium uptake by liver parenchyma).

Contrast-enhanced ultrasound is a better modality for HCC diagnosis in patients with contrast allergy or renal dysfunction. The liver imaging reporting and data system (LI-RADS) version 2018 has provided the algorithm for surveillance, diagnosis, and assessment of treatment response for HCC to achieve a universal approach for standardization and consistency in image reporting (24). Features suggesting HCC include enhancing capsule, non-rim arterial phase hyperenhancement, non-peripheral washout, size of tumor, and threshold growth of tumor over a duration on multi-phase contrast-enhanced CT or MRI. On the USG size of the lesion, architectural distortion of the liver, venous thrombus in the liver, and refractive edge shadows around the lesion are features suggestive of HCC.

Staging

Hepatocellular carcinoma is a carcinoma that most frequently arises in the background of cirrhosis. In any staging system in addition to tumor nodule numbers and size, the severity of liver dysfunction is taken into consideration. Decompensated cirrhosis has a large impact on the outcome of any therapy for HCC. The Barcelona clinic liver cancer (BCLC) staging system (25) is most accepted in various guidelines and practiced (Figure 3). The staging in BCLC is linked to most appropriate therapy for HCC according to the stage of tumor which includes nodule size and number along

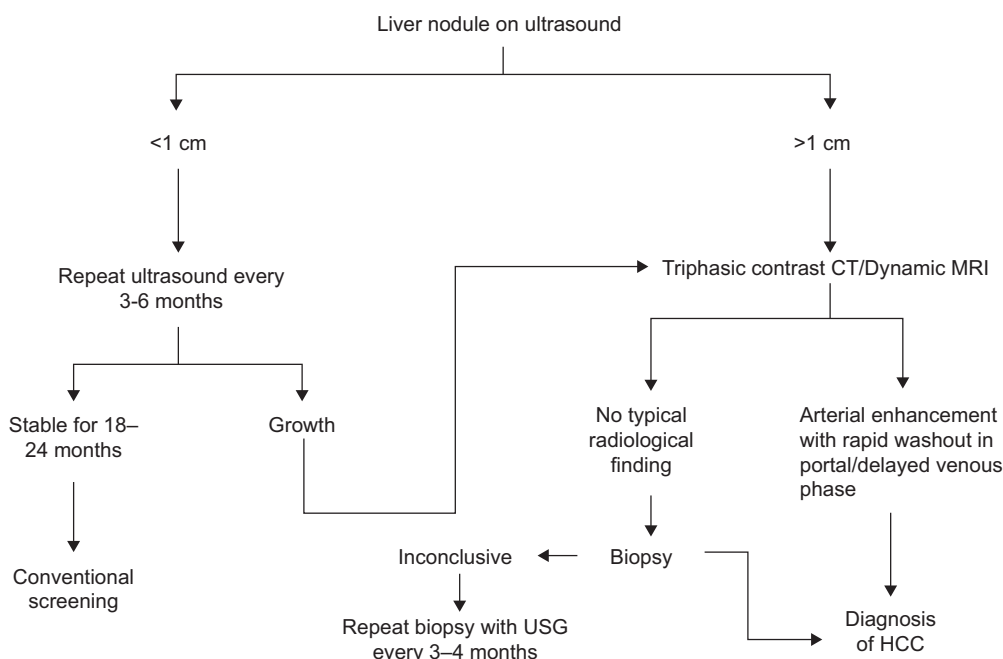


Figure 2: Algorithm for diagnosis of single liver nodule.

with intrahepatic or extrahepatic vascular invasion, extrahepatic metastases, Child–Pugh class for the severity of liver decompensation, and performance status of the patient as assessed by Eastern Cooperative Oncology Group (ECOG) criteria. This is imperative to understand that selection of therapy and its best outcome is always dependent on the extent of liver disease in a given patient. There are other staging systems like the Cancer of the Liver Italian Program (26) and the Hong Kong Liver Cancer staging system (27); however, they are more geographically restricted. Over the years, experts have found that the BCLC staging system has a rigid approach with a selection of patients best for stage associated therapy rather than the best treatment modality for a given patient. Various studies have also shown superior results for aggressive surgical approach than locoregional therapy in HCC. Therefore, the concept of “treatment stage migration” is emerging with either “left to right” or even “right to left” shift for selection of therapy in the BCLC algorithm (28). This means considering liver resection in patients with either vascular invasion or consideration of liver transplantation in patients with downstaging of tumor with locoregional therapy or outside Milan’s criteria (29–31).

Clinical Management

Surgical Modalities

Among all the treatment modalities available, surgical options like hepatic resection and liver transplantation are the best. Hepatic resection has evolved dramatically over time due to a laparoscopic/minimally invasive approach. In BCLC staging, there was a mono-parametric approach to the selection of patients with single tumors, Child A cirrhosis, early portal hypertension with hepatic vein portal system gradient (HVPG) ≤ 10 mmHg or bilirubin ≤ 17 $\mu\text{Mol/L}$ for hepatic resection. However, a multi-parametric approach based upon Child A cirrhosis with model for end stage liver disease (MELD) <10 with an acceptable grade of portal hypertension, acceptable remaining liver parenchyma after resection to achieve adequate hepatic function, and adopting a laparoscopic/minimally invasive approach for surgical treatment of HCC has come into practice (32). This allows to include patients who were previously denied liver resection. Post hepatic liver failure (PHLF) is the most important complication of hepatic resection. Prodeau et al. (33) have recently proposed an ordinal model based upon

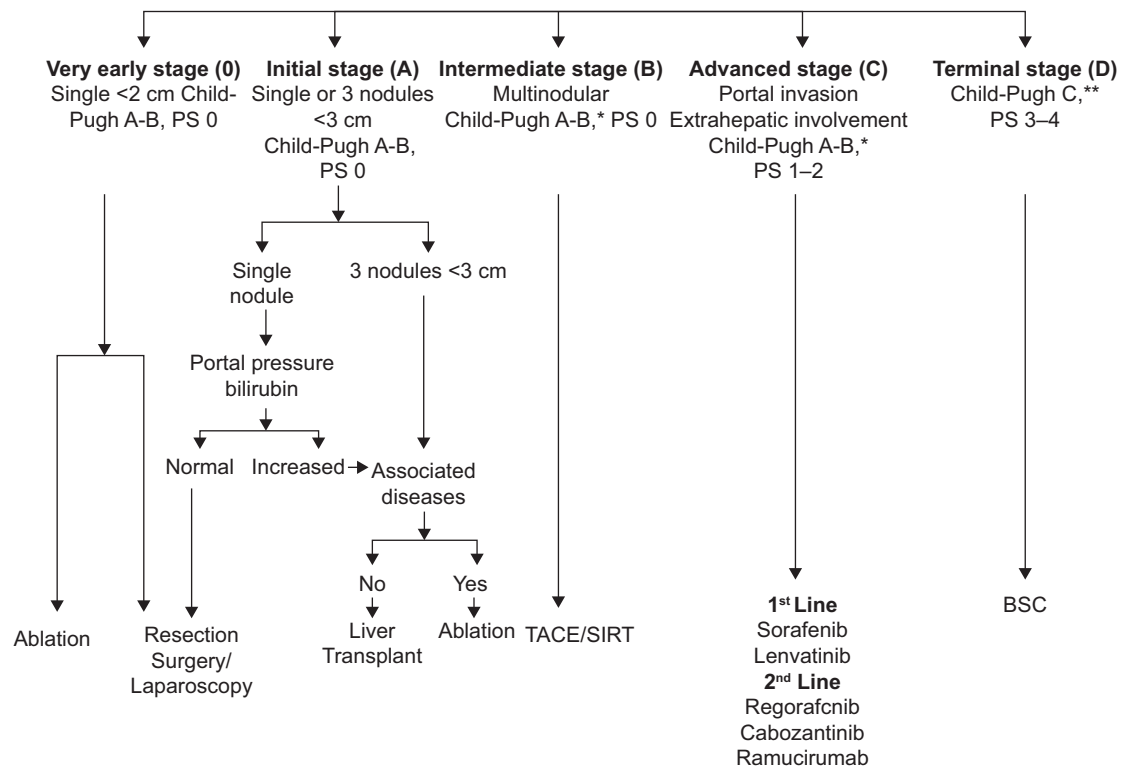


Figure 3: The Barcelona Clinic Liver Cancer (BCLC) staging system. PS: performance status.

pre-operative variables such as liver remnant volume ratio, platelet count, and intent-to-treat laparoscopy with intra-operative variables like intra-operative blood loss and per protocol, laparoscopy to predict symptomatic PHLF in cirrhosis with HCC patients. Overall resection provides 60% survival with an HCC recurrence rate of ~70% at 5 years (34).

Liver transplantation (LT) is the next surgical option for patients with HCC in whom liver resection is not feasible. LT not only removes the tumor but also cures liver disease. The BCLC algorithm allocates orthotopic LT (OLT) for HCC fulfilling Milan's criteria (35) (single tumor ≤ 5 cm and ≤ 3 nodules ≤ 3 cm size). OLT has a survival rate of 60–80% at 5th year and 50% at 10th year with tumor recurrence rate of 15%. The University of California San Francisco (UCSF) criteria are more relaxed including larger tumor size albeit with low survival rates. Mazaferro et al. (36) introduced the concept of Metroticket 2.0 model where tumor size and AFP levels were used to make a model with an expected 5-year survival of 70% after OLT. The model depicted that with AFP < 200 ng/mL, the sum of tumor number and size (cm) should be ≤ 7 ; with AFP 200–400 ng/mL tumor size and number sum should be ≤ 5 ; with AFP 400–1000 ng/mL tumor number and size sum should be ≤ 4 . Today in the Era of neoadjuvant therapies for downstaging of HCC, Cucchetti et al. (37) have recently demonstrated better prediction of post-liver transplant HCC related 5-year mortality after the addition of mRECIST criteria to Metroticket 2.0 model especially in patients with partial/stable response and progressive disease as assessed by mRECIST criteria. The hepatic resection leaves the cirrhotic liver behind which may have unidentified dysplastic nodules at the time of resection or naïve nodules developing later on resulting in a high tumor recurrence rate than LT. However, LT is not the first surgical modality due to donor organ availability issues and transplant waitlist mortality.

Tumor Ablation

BCLC stage 0 or A HCC, which are ineligible for surgical options are taken up for ablative therapies. Various ablative modalities like radiofrequency ablation (RFA), microwave, and cryotherapy are available. RFA unipolar or multipolar is most commonly practiced. It ablates the tumor with heat effect which is applied through an electrode placed inside the tumor under USG guidance. Zhang et al. (38) showed 5- and 10-year survival of 66 and 35% with RFA, respectively. A recent meta-analysis for RFA in HCC revealed that albumin-bilirubin score 0, Child A cirrhosis, single tumor nodule < 2 cm, and AFP < 20 ng/mL were predictive of overall survival (OS) and recurrence-free survival (RFS) (39). Another meta-analysis analyzed studies comparing surgical resection with RFA and found resection to be superior for overall and disease-free survival (DFS) in patients with resectable HCC (40).

Trans Arterial Therapies

The conventional trans arterial chemoembolization (TACE) is a therapeutic modality for intermediate-stage HCC (stage B) without any vascular invasion or extrahepatic spread in which cytotoxic agent mixed with lipiodol is infused intra-arterially into the tumor followed by vessel embolization by gel foam or microspheres. The drug-eluting beads TACE (DEB-TACE) uses non-absorbable embolic microspheres loaded with anthracyclines which stay in the tumor. Studies have shown non-superiority of DEB-TACE in terms of 1- and 2-year survival rates, tumor response rates, and a median time to progression of tumor to conventional TACE (cTACE) (41). A recent meta-analysis has shown no statistically significant difference in adverse events between the two groups (42). The recently updated algorithm has included the use of TACE as bridging therapy to liver transplant, for HCC with segmental portal vein thrombosis, use of TACE in combination with sequential therapy with ablation for lesions up to 7 cm or for recurrent intrahepatic lesions up to 3 cm (43).

Selective internal radiation therapy (SIRT) is the next trans arterial mode of therapy using microspheres loaded with radioisotope yttrium-90 without embolization for anti-tumoral activity. The Sorafenib versus Radioembolization in Advanced Hepatocellular carcinoma (SARAH) trial from France and Selective Internal Radiation Therapy vs. Sorafenib (SIRveNIB) trial from the Asia-pacific region in advanced HCC found no significant difference in OS between SIRT and sorafenib for BCLC stage C patients (44, 45).

Molecular Targeted Therapies

Sorafenib, a multikinase inhibitor, was first approved in 2008 for advanced unresectable HCC BCLC stage C where other curative therapies are futile (46, 47). It inhibits several tyrosine kinases like platelet-derived growth factor receptor (PDGF-R), vascular endothelial growth factor receptor (VEGFR), Flt3, c-Kit, and Raf kinases of MAPK/ERK pathway. It provided a survival benefit of 10.7 months as compared to 7.9 months with placebo (46, 47). Subsequently, many drugs were investigated like brivanib, erlotinib, tivantinib, linifanib, sunitinib, and everolimus which did not show a survival benefit in comparison with placebo (48–52). In 2018, the FDA approved lenvatinib based upon a non-inferiority trial with a median survival of 13.6 months as compared to 12.3 months with sorafenib (53). Both sorafenib and lenvatinib are first-line therapy for HCC.

Regorafenib is another multikinase inhibitor targeting PDGFR, VEGFR, KIT, RET, FGFR1, and TIE-2 and has got FDA approval in 2017 as second-line therapy for advanced HCC (54). Cabozantinib based upon Celestial trial (55) got approval as second- or third-line therapy for HCC in 2019. Ramucirumab, a monoclonal antibody against VEGFR2 has shown an extended OS of 8.5 months

Table 1: Phase III trials in advanced BCLC stage C HCC⁵³⁻⁵⁶.

Line of therapy	Drug	Trial	Patient population	Number of patients	Primary end-point median OS (months)
First line	Sorafenib vs placebo	SHARP	BCLC stage C	299 vs 303	10.7 vs 7.9
	Lenvatinib vs sorafenib	REFLECT	BCLC stage C	478 vs 476	13.6 vs 12.3
Second line	Regorafenib vs placebo	RESORCE	Advanced HCC progressing on sorafenib	379 vs 194	10.6 vs 7.8
	Cabozantinib vs placebo	CELESTIAL	Advanced HCC progressing on sorafenib	470 vs 237	10.2 vs 8
Approval still awaited	Ramucirumab vs placebo	REACH-2	Advanced HCC with AFP >400 ng/mL progressing on sorafenib	197 vs 95	8.5 vs 7.3

OS: overall survival.

as compared to placebo 7.3 months ($P = 0.019$) in advanced HCC progressed after sorafenib with AFP >400 ng/mL (56). However, its approval is still awaited (Table 1).

Cancer immunotherapy is a new field revolutionizing oncology practice. T cell activation for destroying tumor cells is inhibited by the interaction of PD-L1 and B7 with PD-1 and CTLA-4, respectively. Checkpoint inhibitors are the drugs that target PD-1, PD-L1, CTLA-4, etc. In HCC, nivolumab (PD-1 monoclonal antibody) has been shown in Checkmate 040 trial to achieve tumor shrinkage of 20% with a median response duration of 17 months which is better than sorafenib (57). Pembrolizumab is another CPI shown to have tumor response up to 17% with a durable response of 9 months (58). Both nivolumab and pembrolizumab have got FDA approval for advanced HCC with sorafenib failure. However, CPIs have issues like immune-mediated toxicities such as hepatitis, myocarditis, pneumonitis, etc. Although the durable response has been shown, many patients on immunotherapy have subsequently relapsed. Due to genetic heterogeneity in individual HCC, CPIs can have varying effects from tumor regression to rarely tumor progression. A recent study from Korea has shown hyperprogressive disease (HPS) in HCC based upon a four-fold increase in tumor growth kinetics (TGK) and tumor growth rate (TGR) in 12.7% of patients treated with nivolumab (59). HPS carries a dismal prognosis and even after discontinuation of CPIs, due to the rapid downhill course of illness, other therapies for HCC become impractical in a given case.

Conclusions

Although the incidence of chronic viral hepatitis B and C is decreasing, HCC prevalence is expected to rise due to

the emerging epidemic of NASH and metabolic syndrome. Emerging research on the molecular landscape of HCC shall improve surveillance and diagnostic modalities. The concept of “Treatment stage migration” with “right to left” or “left to right” shift in the BCLC algorithm has improved the selection of treatment modality for an individual patient. The immune classification of HCC may open ways to better understanding for use of CPIs. Further translational research is needed to correctly identify patients who will do best on multikinase inhibitors, VEGFR inhibitors, or immunotherapy. Finally, a lot more research is needed to identify the effective combination of different modalities of HCC treatment to achieve the best results.

References

- Agency for Research on Cancer, World Health Organization. Cancer today [Internet]. [accessed 20 Mar 2020]. Available from: <https://gco.iarc.fr/today/home>
- Perz JF, Armstrong GL, Farrington LA, Hutin YJ, Bell BP. The contributions of hepatitis B virus and hepatitis C virus infections to cirrhosis and primary liver cancer worldwide. *J Hepatol.* 2006;45:529–38. <https://doi.org/10.1016/j.jhep.2006.05.013>
- Younossi Z, Stepanova M, Ong JP, Jacobson IM, Bugianesi E, Duseja A, et al. Nonalcoholic steatohepatitis is the fastest growing cause of hepatocellular carcinoma in liver transplant candidates. *Clin Gastroenterol Hepatol.* 2019;17:748–55. <https://doi.org/10.1016/j.cgh.2018.05.057>
- Chen CL, Yang HI, Yang WS, Liu CJ, Chen PJ, You SL, et al. Metabolic factors and risk of hepatocellular carcinoma by chronic hepatitis B/C infection: A follow-up study in Taiwan. *Gastroenterology.* 2008;135:111–21. <https://doi.org/10.1053/j.gastro.2008.03.073>
- Siegel AB, Zhu AX. Metabolic syndrome and hepatocellular carcinoma: Two growing epidemics with a potential link. *Cancer.* 2009;115:5651–61. <https://doi.org/10.1002/cncr.24687>

6. Dongiovanni P, Romeo S, Valenti L. Hepatocellular carcinoma in nonalcoholic fatty liver: Role of environmental and genetic factors. *World J Gastroenterol.* 2014;20:12945–55. <https://doi.org/10.3748/wjg.v20.i36.12945>
7. Sangiovanni A, Del Ninno E, Fasani P, De Fazio C, Ronchi G, Romeo R, et al. Increased survival of cirrhotic patients with a hepatocellular carcinoma detected during surveillance. *Gastroenterology.* 2004;126:1005–14. <https://doi.org/10.1053/j.gastro.2003.12.049>
8. Nault JC, Mallet M, Pilati C, Calderaro J, Bioulac-Sage P, Laurent C, et al. High frequency of telomerase reverse-transcriptase promoter somatic mutations in hepatocellular carcinoma and preneoplastic lesions. *Nat Commun.* 2013;4:2218. <https://doi.org/10.1038/ncomms3218>
9. Ahn SM, Jang SJ, Shim JH, Kim D, Hong SM, Sung CO, et al. Genomic portrait of resectable hepatocellular carcinomas: Implications of RB1 and FGF19 aberrations for patient stratification. *Hepatology.* 2014;60:1972–82. <https://doi.org/10.1002/hep.27198>
10. Wheeler DA. Comprehensive and integrative genomic characterization of hepatocellular carcinoma. *Cell.* 2017;169:1327–41. <https://doi.org/10.1016/j.cell.2017.05.046>
11. Schulze K, Imbeaud S, Letouzé E, Alexandrov LB, Calderaro J, Rebouissou S, et al. Exome sequencing of hepatocellular carcinomas identifies new mutational signatures and potential therapeutic targets. *Nat Genet.* 2015;47:505–11. <https://doi.org/10.1038/ng.3252>
12. Totoki Y, Tatsuno K, Covington KR, Ueda H, Creighton CJ, Kato M, et al. Trans-ancestry mutational landscape of hepatocellular carcinoma genomes. *Nat Genet.* 2014;46:1267–73. <https://doi.org/10.1038/ng.3126>
13. Nault JC, Couchy G, Balabaud C, Morcrette G, Caruso S, Blanc JF, et al. Molecular classification of hepatocellular adenoma associates with risk factors, bleeding, and malignant transformation. *Gastroenterology.* 2017;152:880–94. <https://doi.org/10.1053/j.gastro.2016.11.042>
14. Sia D, Villanueva A, Friedman SL, Llovet JM. Liver cancer cell of origin, molecular class, and effects on patient prognosis. *Gastroenterology.* 2016;152:745–61. <https://doi.org/10.1053/j.gastro.2016.11.048>
15. Wheeler DA. Comprehensive and integrative genomic characterization of hepatocellular carcinoma. *Cell.* 2017;169:1327–41. <https://doi.org/10.1016/j.cell.2017.05.046>
16. Sia D, Jiao Y, Martinez-Quetglas I, Schwartz M, Villanueva A, Llovet JM. Identification of an immune-specific class of hepatocellular carcinoma, based on molecular features. *Gastroenterology.* 2017;153:812–26. <https://doi.org/10.1053/j.gastro.2017.06.007>
17. Singal AG, Pillai A, Tiro J. Early detection, curative treatment, and survival rates for hepatocellular carcinoma surveillance in patients with cirrhosis: A meta-analysis. *PLoS Med.* 2014;11:e1001624. <https://doi.org/10.1371/journal.pmed.1001624>
18. Marrero JA, Kulik LM, Sirlin CB, Zhu AX, Finn RS, Abecassis MM, et al. Diagnosis, staging, and management of hepatocellular carcinoma: 2018 practice guidance by the American Association for the Study of Liver Diseases. *Hepatology.* 2018;68:723–50. <https://doi.org/10.1002/hep.29913>
19. Park HJ, Jang HY, Kim SY, Lee SJ, Won HJ, Byun JH, et al. Non-enhanced magnetic resonance imaging as a surveillance tool for hepatocellular carcinoma: Comparison with ultrasound. *J Hepatol.* 2020;72:718–24. <https://doi.org/10.1016/j.jhep.2019.12.001>
20. Labgaa I, Villacorta-Martin C, D'Avola D, Craig AJ, von Felden J, Martins-Filho SN, et al. A pilot study of ultra-deep targeted sequencing of plasma DNA identifies driver mutations in hepatocellular carcinoma. *Oncogene.* 2018;37:3740–52. <https://doi.org/10.1038/s41388-018-0206-3>
21. Tommaso LD, Spadaccini M, Donadon M, Personeni N, Elamin A, Aghemo A, et al. Role of liver biopsy in hepatocellular carcinoma. *World J Gastroenterol.* 2019;25:6041–52. <https://doi.org/10.3748/wjg.v25.i40.6041>
22. Wu X, Li J, Gassa A, Buchner D, Alakus H, Dong Q, et al. Circulating tumor DNA as an emerging liquid biopsy biomarker for early diagnosis and therapeutic monitoring in hepatocellular carcinoma. *Int J Biol Sci.* 2020;16:1551–62. <https://doi.org/10.7150/ijbs.44024>
23. Roberts LR, Sirlin CB, Zaiem F, Almasri J, Prokop LJ, Heimbach JK, et al. Imaging for the diagnosis of hepatocellular carcinoma: A systematic review and meta-analysis. *Hepatology.* 2018;67:401–21. <https://doi.org/10.1002/hep.29487>
24. Chernyak V, Fowler KJ, Kamaya A, Kielar AZ, Elsayes KM, Bashir MR, et al. Liver Imaging Reporting and Data System (LI-RADS) version 2018: Imaging of hepatocellular carcinoma in at-risk patients. *Radiology.* 2018;289:816–30. <https://doi.org/10.1148/radiol.2018181494>
25. Llovet JM, Br. C, Bruix J. Prognosis of hepatocellular carcinoma: The BCLC staging classification. *Semin Liver Dis.* 1999;19:329–38. <https://doi.org/10.1055/s-2007-1007122>
26. The Cancer of the Liver Italian Program (CLIP) Investigators. A new prognostic system for hepatocellular carcinoma: A retrospective study of 435 patients. *Hepatology.* 1998;28:751–5. <https://doi.org/10.1002/hep.510280322>
27. Yau T, Tang VYF, Yao T-J, Fan S-T, Lo C-M, Poon RTP. Development of Hong Kong Liver Cancer staging system with treatment stratification for patients with hepatocellular carcinoma. *Gastroenterology.* 2014;146:1691–700. <https://doi.org/10.1053/j.gastro.2014.02.032>
28. Vitale A, Trevisani F, Farinati F, Cillo U. Treatment of hepatocellular carcinoma in the Precision Medicine era: From treatment stage migration to therapeutic hierarchy. *Hepatology.* 2020 Feb 16. doi: 10.1002/hep.31187. Epub ahead of print. <https://doi.org/10.1002/hep.31187>
29. Kokudo T, Hasegawa K, Matsuyama Y, Takayama T, Izumi N, Kadoya M, et al. Liver Cancer Study Group of Japan. Survival benefit of liver resection for hepatocellular carcinoma associated with portal vein invasion. *J Hepatol.* 2016;65:938–43. <https://doi.org/10.1016/j.jhep.2016.05.044>
30. Yin L, Li H, Li AJ, Lau WY, Pan ZY, Lai EC, et al. Partial hepatectomy vs. transcatheter arterial chemoembolization for resectable multiple hepatocellular carcinoma beyond Milan Criteria: A RCT. *J Hepatol.* 2014;61:2–88. <https://doi.org/10.1016/j.jhep.2014.03.012>
31. Yao FY, Mehta N, Flemming J, Dodge J, Hameed B, Fix O, et al. Downstaging of hepatocellular cancer before liver transplant: Long-term outcome compared to tumors within Milan criteria. *Hepatology.* 2015;61:1968–77. <https://doi.org/10.1002/hep.27752>
32. Vitale A, Majno-Hurst P. Towards a personalized approach to hepatic resection in cirrhotic patients. *J Hepatol.* 2019;71:859–61. <https://doi.org/10.1016/j.jhep.2019.09.005>

33. Prodeau M, Drumez E, Duhamel A, Vibert E, Farges O, Lassailly G, et al. An ordinal model to predict the risk of symptomatic liver failure in patients with cirrhosis undergoing hepatectomy. *J Hepatol.* 2019;71:920–9. <https://doi.org/10.1016/j.jhep.2019.06.003>
34. Roayaie S, Jibara G, Tabrizian P, Park JW, Yang J, Yan L, et al. The role of hepatic resection in the treatment of hepatocellular cancer. *Hepatology.* 2015;62:440–51. <https://doi.org/10.1002/hep.27745>
35. Mazzaferro V, Regalia E, Doci R, Andreola S, Pulvirenti A, Bozzetti F, et al. Liver transplantation for the treatment of small hepatocellular carcinomas in patients with cirrhosis. *N Engl J Med.* 1996;334:693–9. <https://doi.org/10.1056/NEJM199603143341104>
36. Mazzaferro V, Sposito C, Zhou J, Pinna AD, Carlis LD, Fan J, et al. Metroticket 2.0 model for analysis of competing risks of death after liver transplantation for hepatocellular carcinoma. *Gastroenterology.* 2018;154(1):128–39. <https://doi.org/10.1053/j.gastro.2017.09.025>
37. Cucchetti A, Serenari M, Sposito C, Sandro SD, Mosconi C, Vicentin I, et al. Including mRECIST in the Metroticket 2.0 criteria improves prediction of hepatocellular carcinoma-related death after liver transplant. *J Hepatol.* 2020;73:342–8. <https://doi.org/10.1016/j.jhep.2020.03.018>
38. Zhang W, Luo E, Gan J, Song X, Bao Z, Zhang H, et al. Long-term survival of hepatocellular carcinoma after percutaneous radiofrequency ablation guided by ultrasound. *World J Surg Oncol.* 2017;15:122. <https://doi.org/10.1186/s12957-017-1189-1>
39. Casadei Gardini A, Marisi G, Canale M, Canale M, Foschi FG, Donati G, et al. Radiofrequency ablation of hepatocellular carcinoma: A meta-analysis of overall survival and recurrence-free survival. *Oncol Targets Ther.* 2018;11:6555–67. <https://doi.org/10.2147/OTT.S170836>
40. Li JK, Liu XH, Cui H, Xie XH. Radiofrequency ablation vs. surgical resection for resectable hepatocellular carcinoma: A systematic review and meta-analysis. *Mol Clin Oncol.* 2020;12:15–22. <https://doi.org/10.3892/mco.2019.1941>
41. Facciorusso A, Di Maso M, Muscatello N. Drug-eluting beads versus conventional chemoembolization for the treatment of unresectable hepatocellular carcinoma: A meta-analysis. *Dig Liver Dis.* 2016;48:571–7. <https://doi.org/10.1016/j.dld.2016.02.005>
42. Golfieri R, Giampalma E, Renzulli M, Cioni R, Bargellini I, Bartolozzi C, et al. Randomised controlled trial of doxorubicin-eluting beads vs conventional chemoembolization for hepatocellular carcinoma. *Br J Cancer.* 2014;111:255–64. <https://doi.org/10.1038/bjc.2014.199>
43. Raoul JL, Forner A, Bolondi L, Cheung TT, Kloeckner R, Baere T. Updated use of TACE for hepatocellular carcinoma treatment: How and when to use it based on clinical evidence. *Cancer Treat Rev.* 2019;72:28–36. <https://doi.org/10.1016/j.ctrv.2018.11.002>
44. Vilgrain V, Pereira H, Assenat E, Guiu B, Ilonca AD, Pageaux GP, et al. Efficacy and safety of selective internal radiotherapy with yttrium-90 resin microspheres compared with sorafenib in locally advanced and inoperable hepatocellular carcinoma (SARAH): An open-label randomised controlled phase 3 trial. *Lancet Oncol.* 2017;18:1624–36. [https://doi.org/10.1016/S1470-2045\(17\)30683-6](https://doi.org/10.1016/S1470-2045(17)30683-6)
45. Chow PKH, Gandhi M, Tan SB, Khin MW, Khasbazar A, Ong J, et al. SIRveNIB: Selective internal radiation therapy versus sorafenib in Asia-Pacific patients with hepatocellular carcinoma. *J Clin Oncol.* 2018;36:1913–21. <https://doi.org/10.1200/JCO.2017.76.0892>
46. Llovet JM, Ricci S, Mazzaferro V, Hilgard P, Gane E, Blanc JF, et al. Sorafenib in advanced hepatocellular carcinoma. *N Engl J Med.* 2008;359:378–90. <https://doi.org/10.1056/NEJMoa0708857>
47. Cheng AL, Kang YK, Chen Z, Tsao CJ, Qin S, Kim JS, et al. Efficacy and safety of sorafenib in patients in the Asia-Pacific region with advanced hepatocellular carcinoma: A phase III randomised, double-blind, placebo-controlled trial. *Lancet Oncol.* 2009;10:25–34. [https://doi.org/10.1016/S1470-2045\(08\)70285-7](https://doi.org/10.1016/S1470-2045(08)70285-7)
48. Cheng AL, Kang YK, Lin DY, Park JW, Kudo M, Qin S, et al. Sunitinib versus sorafenib in advanced hepatocellular cancer: Results of a randomized phase III trial. *J Clin Oncol.* 2013;31:4067–75. <https://doi.org/10.1200/JCO.2012.45.8372>
49. Cainap C, Qin S, Huang WT, Chung IJ, Pan H, Cheng Y, et al. Linifanib versus sorafenib in patients with advanced hepatocellular carcinoma: Results of a randomized phase III trial. *J Clin Oncol.* 2015 Jan 10;33(2):172–9. Erratum in: *J Clin Oncol.* 2017;35:2590. <https://doi.org/10.1200/JCO.2013.54.3298>
50. Johnson PJ, Qin S, Park JW, Poon RT, Raoul JL, Philip PA, et al. Brivanib versus sorafenib as first-line therapy in patients with unresectable, advanced hepatocellular carcinoma: Results from the randomized phase III BRISK-FL study. *J Clin Oncol.* 2013;31:3517–24. <https://doi.org/10.1200/JCO.2012.48.4410>
51. Rimassa L, Assenat E, Peck-Radosavljevic M, Pracht M, Zagonel V, Mathurin P, et al. Tivantinib for second-line treatment of MET-high, advanced hepatocellular carcinoma (METIV-HCC): A final analysis of a phase 3, randomised, placebo-controlled study. *Lancet Oncol.* 2018;19:682–93. [https://doi.org/10.1016/S1470-2045\(18\)30146-3](https://doi.org/10.1016/S1470-2045(18)30146-3)
52. Zhu AX, Kudo M, Assenat E, Cattani S, Kang YK, Lim HY, et al. Effect of everolimus on survival in advanced hepatocellular carcinoma after failure of sorafenib: The EVOLVE-1 randomized clinical trial. *JAMA.* 2014;312:57–67. <https://doi.org/10.1001/jama.2014.7189>
53. Kudo M, Finn RS, Qin S, Han KH, Ikeda K, Piscaglia F, et al. Lenvatinib versus sorafenib in first-line treatment of patients with unresectable hepatocellular carcinoma: A randomised phase 3 non-inferiority trial. *Lancet.* 2018;391:1163–73. [https://doi.org/10.1016/S0140-6736\(18\)30207-1](https://doi.org/10.1016/S0140-6736(18)30207-1)
54. Bruix J, Qin S, Merle P, Granito A, Huang YH, Bodoky G, et al. Regorafenib for patients with hepatocellular carcinoma who progressed on sorafenib treatment (RESORCE): A randomised, double-blind, placebo-controlled, phase 3 trial. *Lancet.* 2017;389:56–66. Erratum in: *Lancet.* 2017;389:36. [https://doi.org/10.1016/S0140-6736\(16\)32453-9](https://doi.org/10.1016/S0140-6736(16)32453-9)
55. Abou-Alfa GK, Meyer T, Cheng AL, El-Khoueiry AB, Rimassa L, Ryou BY, et al. Cabozantinib in patients with advanced and progressing hepatocellular carcinoma. *N Engl J Med.* 2018;379:54–63. <https://doi.org/10.1056/NEJMoa1717002>
56. Zhu AX, Kang YK, Yen CJ, Finn RS, Galle PR, Llovet JM, et al. Ramucicromab after sorafenib in patients with advanced hepatocellular carcinoma and increased α -fetoprotein concentrations (REACH-2): A randomised, double-blind, placebo-controlled, phase 3 trial. *Lancet Oncol.* 2019;20:282–96. [https://doi.org/10.1016/S1470-2045\(18\)30937-9](https://doi.org/10.1016/S1470-2045(18)30937-9)
57. El-Khoueiry AB, Sangro B, Yau T, Crocenzi TS, Kudo M, Hsu C, et al. Nivolumab in patients with advanced

- hepatocellular carcinoma (CheckMate 040): An open-label, non-comparative, phase 1/2 dose escalation and expansion trial. *Lancet*. 2017;389:2492–502. [https://doi.org/10.1016/S0140-6736\(17\)31046-2](https://doi.org/10.1016/S0140-6736(17)31046-2)
58. Zhu AX, Finn RS, Edeline J, Cattan S, Ogasawara S, Palmer D, et al. Pembrolizumab in patients with advanced hepatocellular carcinoma previously treated with sorafenib (KEYNOTE-224): A non-randomised, open-label phase 2 trial. *Lancet Oncol*. 2018;19:940–52. [https://doi.org/10.1016/S1470-2045\(18\)30351-6](https://doi.org/10.1016/S1470-2045(18)30351-6)
59. Kim CG, Kim C, Yoon SE, Kim KH, Choi SJ, Kang B, et al. Hyperprogressive disease during PD-1 blockade in patients with advanced hepatocellular carcinoma. *J Hepatol*. 2020;S0168-8278(20)30540-7.