Journal of Renal and Hepatic Disorders

REVIEW ARTICLE

Cholemic Nephropathy: Hyperbilirubinemia and its Impact on Renal Function

Jonathan S. Chávez-Iñiguez[1,2], Alejandra Meza-Ríos[3], Arturo Santos-Garcia[3], Guillermo García-García[1,2], Juan Armendariz-Borunda[3,4]

[1]Servicio de Nefrología, Hospital Civil de Guadalajara Fray Antonio Alcalde, Guadalajara, Jalisco, México; [2]Centro Universitario de Ciencias de la Salud CUCS, Universidad de Guadalajara, Guadalajara, Jalisco, México; [3]Tecnologico de Monterrey, Campus Guadalajara, Mexico; [4]Instituto de Biología Molecular en Medicina y Terapia Génica, CUCS, Universidad de Guadalajara, Jalisco, México

Abstract

Cholemic nephropathy represents a spectrum of renal injury, from proximal tubulopathy to intrarenal bile cast formation, found in patients with severe liver dysfunction. It is caused by hyperbilirubinemia, usually in jaundiced patients. Acute kidney injury is one of the most important complications in patients with end-stage liver disease. The relationship between liver disease and renal impairment, especially the effect of hyperbilirubinemia on renal tissue and renal function, has not been fully elucidated. These considerations deem necessary for nephrologists, when performing a clinical evaluation of patients with liver diseases, for the implementation of an integrated medical approach. This review focuses on the current knowledge on cholemic nephropathy with emphasis on the role of hyperbilirubinemia on renal impairment. The treatment strategies and outcome are also discussed.

Keywords: cholemic nephropathy; extracorporeal albumin dialysis; hyperbilirubinemia; molecular adsorbent recirculating system; ursodeoxycholic acid

Received: 09 January 2019; *Accepted after revision*: 20 February 2019; *Published*: 18 March 2019

Author for correspondence: Juan Armendariz-Borunda, Instituto de Biología Molecular y Terapia Génica, CUCS, Universidad de Guadalajara, Mexico. Email: armdbo@gmail.com

How to cite: Chávez-Iñiguez JS et al. Cholemic nephropathy: Hyperbilirubinemia and its impact on renal function. J Ren Hepat Disord. 2019;3(1):33–39.

Doi: http://dx.doi.org/10.15586/jrenhep.2019.52

Copyright: Chávez-Iñiguez JS et al.

License: This open access article is licensed under Creative Commons Attribution 4.0 International (CC BY 4.0). http://creativecommons.org/licenses/by/4.0

Introduction

Cholemic nephropathy (CN) is the clinical manifestation of hyperbilirubinemia that encompasses acute kidney injury (AKI) with characteristic histological changes in the distal segment of the nephron and intraluminal casts in jaundiced patients (1). Since the pioneer studies of Hecher and Schroeder, it has been known that impairment of kidney function is a common event in the clinical course of cirrhosis, and it is associated with poor prognosis (2, 3). An important non-vasomotor mechanism of AKI in cirrhosis is the nephrotoxicity of bilirubin and bile acids (4). Nephrologists are frequently asked to evaluate patients with liver disease-associated kidney disease, and the spectrum can include both acute and chronic kidney diseases. Kidney disorders occur in up to 25% of patients with liver disease (5). An understanding of the kidney–liver interaction is essential for the implementation of an integrated medical approach. Herein we present our current understanding of CN, the effect of

hyperbilirubinemia on renal dysfunction, and the treatment strategies, although mostly experimental, for the management of CN.

Hyperbilirubinemia

Bilirubin is a metabolite of ferroprotoporphyrin IX (heme), a potentially toxic metabolite, for which the body has developed detoxification and disposition mechanisms. Eighty percent of bilirubin comes from the breakdown of the hemoglobin of senescent red blood cells in the reticuloendothelial system and other erythroid cells destroyed in the bone marrow. The remaining 20% originates from the turnover of heme-containing proteins from other tissues like liver and muscles, and sources such as myoglobin, cytochromes, catalase, peroxidase, and tryptophan pyrrolase. Kupffer cells in the liver take up the heme where the enzyme heme oxygenase acts on them liberating the chelated iron; this reaction leads the formation of the green pigment, biliverdin. Biliverdin is acted on by a nicotinamide adenine dinucleotide phosphate (NADPH)-dependent enzyme, biliverdin reductase, releasing an orange–yellow pigment known as bilirubin. Bilirubin is insoluble in aqueous solution and is carried in circulation bound to albumin and transported throughout the body (6).

Hyperbilirubinemia can be the result of disorders that lead to excessive bilirubin production (hemolysis), or a decrease in bilirubin clearance (hepatic or intestinal), or a combination of the two (7). Hyperbilirubinemia in adult patients can be the result of many benign or life-threatening disorders. The causes could be prehepatic, intrahepatic, or posthepatic. Prehepatic causes include hemolysis and hematoma resorption, leading to an increase in unconjugated bilirubin levels. Intrahepatic disorders can generate either unconjugated or conjugated hyperbilirubinemia. Causes of conjugated hyperbilirubinemia include (i) hepatocellular diseases like viral infections, chronic alcohol consumption, and autoimmune disorders; (ii) drug toxicity; (iii) pregnancy; (iv) parenteral nutrition; (v) sarcoidosis; (vi) Dubin–Johnson syndrome; (vii) Rotor´s syndrome; (viii) primary biliary cirrhosis; and (ix) primary sclerosing cholangitis. Posthepatic or extrahepatic disorders that elevate conjugated bilirubin can be either intrinsic or extrinsic to the ductal system—intrinsic factors include gallstones, surgical strictures, infections, intrahepatic malignancy, and cholangiocarcinoma, while extrinsic factors include extrahepatic malignancy and pancreatitis (8). Patients with high levels of unconjugated bilirubin are at risk of developing bilirubin encephalopathy (kernicterus). The adverse effects of bilirubin could be the result of inhibition of DNA synthesis, uncoupling oxidative phosphorylation, and inhibition of adenosine triphosphatase (ATPase) activity of brain mitochondria. Furthermore, bilirubin-mediated inhibition of some enzyme systems, RNA and protein synthesis in the brain and liver, and modification of carbohydrate metabolism in the brain contribute to its toxicity. The abnormal accumulation of bilirubin in plasma and tissues lead to a yellow discoloration of tissues known as icterus or jaundice (9).

AKI in cirrhosis patients in the context of hyperbilirubinemia

AKI that occurs in patients with cirrhosis due to severe hypoperfusion and impairment in the systemic arterial circulation has been known as hepatorenal syndrome (HRS) (10). In addition, impairment of kidney function can be the result of a variety of other causes, particularly volume depletion, bacterial infections, nephrotoxic agents, chronic kidney disease, intratubular deposition of bilirubin, or a combination thereof (11–14). Bilirubin can cause adverse effects on kidney cells. A study using cortical slices of kidney showed that bilirubin was internalized by renal epithelial cells via the organic anion transport system, leading to the inhibition of adenosine triphosphate (ATP) production, induction of mitochondrial structural defects, alteration of membrane permeability, and modification of electrolyte content and cell volume (4). The clinical picture to distinguish CN from HRS is that, in HRS, the following alterations are usually present: altered hemodynamic function characterized by peripheral vasodilation and renal vasoconstriction, and tubular dysfunction with increased water and sodium reabsorption. In contrast, the above pathophysiological mechanisms are absent or rarely present in CN.

Previous studies on cirrhosis in which impairment of kidney function was diagnosed with criteria other than AKI underscore the importance of kidney function in determining prognosis in cirrhosis (15, 16). One of the problems is the stratification of AKI by urinary thresholds; these patients may have an increased urine output because of diuretic treatment. Thus, urine collection is often inaccurate in clinical practice and the use of kinetic changes in serum creatinine (sCr) has now become the key for AKI diagnosis in cirrhosis. However, it should be noted that the use of sCr in patients with cirrhosis is affected by decreased formation of creatinine from creatine in muscles secondary to muscle wasting, increased renal tubular secretion of creatinine, increased volume distribution that could dilute sCr, and interference of elevated serum bilirubin with assays of sCr (17, 18). Because of the negatively charged reactant, bilirubin interferes with creatinine/picrate reaction (18). Watkins et al. were the first to report the considerable negative interference on the part of bilirubin; they found, comparing the Automatic Clinical Analyzer (ACA) and end point Technicon SMA 6/60 method to measure sCr, that the ACA kinetic method gave considerably lower results with samples that were highly jaundiced (19). As a consequence, measurement of sCr in patients with cirrhosis overestimates glomerular filtration rate (GFR) or kidney function. Also, in patients with cirrhosis, sCr is an unreliable tool in assessing kidney function owing to the low production rate of creatine (the precursor of creatinine) by the liver with reduced muscle mass (5). Cystatin C has been

proposed as an alternative marker to assess kidney function, but using cystatin C–based formulas to assess kidney function in cirrhotic patients also has yielded mixed results (20).

AKI is a common and serious complication in patients with liver disease; among the etiologies, those related to hyperbilirubinemia have been less explored (15) and therefore our knowledge is scarce. It has been overlooked in recent medical literature despite its frequency (21). In addition, the lack of kidney biopsy in patients with liver dysfunction makes it difficult to establish the association between liver and kidney disorders (4). AKI in patients with hepatic diseases or cirrhosis is now defined according to the proposal of the Kidney Disease Improving Global Outcome (KDIGO) Criteria, as an increase in sCr of >0.3 mg/dL (22). AKI affects almost 50% of hospitalized patients with cirrhosis and is associated with poor prognosis with mortality rates reaching as high as 90% (23). In 2012, the International Club of Ascites (ICA) organized a consensus in order to reach a new definition of AKI in patients with cirrhosis (Table 1). In the new ICA criteria for the diagnosis of AKI, the use of urine output as one of the criteria has been removed as it does not apply to patients with cirrhosis. Further, two other changes to the KDIGO criteria were adopted: (i) an sCr within the last 3 months before admission is considered a baseline value for the diagnosis of AKI when a value within the previous 7 days is not available and (ii) the calculation of the baseline sCr by the reverse application of the Modification of Diet in Renal Disease (MDRD) formula using an arbitrarily defined normal value of GFR of 75 mL/min/1.73 m^2 was not included (17). The main differences between these new criteria and the conventional criteria in patients with cirrhosis are the following: (i) an absolute increase in sCr is considered; (ii) the threshold of sCr > 1.5 mg/dL (133 μmol/L) is abandoned; and (iii), a staging system of AKI based on a change in sCr over a slightly longer time frame, arbitrarily set at 1 week, to enable assessment of progression as well as regression of stage (modified from AKIN staging) (Table 1).

Even a minor increment in sCr in patients with cirrhosis is strongly associated with mortality. Fagundes et al. demonstrated that, in cirrhotic patients, the occurrence of AKI and its stage were associated with 3-month survival. While there was no statistically significant difference in survival rate between stages 2 and 3, when stage 1 patients were categorized into two groups according to the level of sCr used in the classical definition of kidney impairment (1.5 mg/dL), those with sCr less than 1.5 mg/dL, had a better survival (24). In another study, AKI was attributed to hyperbilirubinemia based on the following rationale: (i) alternative diagnoses were actively ruled out; (ii) the onset of AKI coincided with the onset of severe hyperbilirubinemia; (iii) renal pathology showed large bile tubular casts and a marked tubular necrosis; and (iv) sCr dramatically decreased when bilirubin levels improved (25).

Diagnosis of cholemic nephropathy

CN represents a spectrum of renal injury, from proximal tubulopathy to intrarenal bile cast formation, found in patients with severe liver dysfunction. CN and its numerous synonyms (i.e., icteric nephrosis, jaundice-related nephropathy, bile cast nephropathy, bile acid nephropathy) (1) have been reported in many liver diseases (Table 2). Essentially, CNcan be suspected in any disorders that increases the bilirubin levels. There is a strong interaction between the bile salts and the kidney. Elevated plasma concentrations of bile salts and bilirubin, conjugated or not, putatively mediate nephrotoxicity. However, it seems that a total serum bilirubin less than 15.1 mg/dL is not enough to trigger AKI (26). Sitprija et al. showed that in obstructive jaundice (OJ) due

Table 1. Definition of AKI in patients with cirrhosis

Stage	Criteria
1	Increase in sCr ≥ 0.3 mg/dL (26.5 μmol/L) or an increase in sCr ≥ 1.5-fold to 2-fold from baseline
2	Increase in sCr > 2-fold to 3-fold from baseline
3	Increase of sCr > 3-fold from baseline or sCr ≥ 4.0 mg/dL (353.6 μmol/L), with an acute increase ≥ 0.3 mg/dL (26.5 μmol/L) or initiation of renal replacement therapy

sCr, serum creatinine.

Table 2. Disorders reported in cholemic nephropathy

Condition	Disorder
Liver failure	Subacute liver failure, autoimmune hepatitis, alcoholic steatohepatitis, cirrhosis
Hepatic obstruction	Cholangiocarcinoma, gallstones in the bile duct, obstructive cholestasis, cholangiocellular carcinoma
Systemic diseases	Hodgkin's lymphoma, infectious mononucleosis, Falciparum malaria
Drug-induced	Anabolic steroids, antibiotics, flucloxacillin

to cholangiocarcinoma, patients with bilirubin level >26 mg/dL, presented with severe renal dysfunction (26). Van Slambrouck et al. proposed that renal abnormalities that accompany hyperbilirubinemia be named bile cast nephropathy as the appropriate pathological term (21). Mohapatra et al presented microscopy findings of centrifuged urine that characteristically showed bile-stained casts, leucocytes, and renal epithelial cells containing granular or crystalline bilirubin (27). There may be some clues in the urinalysis of patients with CN, but these findings are nonspecific and lacks sensitivity and specificity for diagnosis. To the best of our knowledge, the biomarkers used for AKI have not been explored in the setting of CN. CN diagnosis relies mostly on kidney biopsy. It may otherwise be overlooked in these patient populations because of the obvious concern of complication related to the procedure, which carries almost a 12% risk of significant bleeding (5). Whether a transjugular approach may represent a suitable and safe alternative to significantly reduce such risks in this difficult-to-manage group of patients needs to be explored (1).

Cholemic nephropathy with dysfunctional tubular manifestation

Since 1930, it has been observed that patients with OJ are prone to kidney damage as a result of urinary excretion of bilirubin and bile salts. Bilirubin accumulation in tubular cells directly damages the mitochondria, decreasing ATPase activity. It also alters the hemodynamic response to angiotensin II and catecholamines, together with increased natriuresis and reduced renal flow (28). When the bilirubin levels reach >20 mg/dL, exceeding the binding capacity of albumin to bilirubin, it accumulates in mitochondria and renal tubules, resulting in tubular dysfunction and acute tubular necrosis in conjunction with intratubular bilirubin cast (28). Martinez et al. demonstrated that in patients with OJ, an increase in lipid peroxidation products, higher levels of total bilirubin, and the depletion activity of superoxide dismutase in blood were all related to renal dysfunction. Patients with OJ showed a marked increase in plasma levels of oxidative stress markers; higher levels in blood were predictors of renal dysfunction in OJ patients (29).

The hypothetical mechanisms implicated in renal impairments largely come from experimental studies. In a murine model, Fickert et al. ligated the common bile duct and, 3 days later, observed renal tubular epithelial lesions; at 7 days, there was dilation and partial, but progressive, occlusion of the distal and collecting tubules, followed by overexpression of proinflammatory cytokines, progressive interstitial nephritis, and tubulointerstitial fibrosis. This model reinforces the hypothesis that the accumulation and consequent excessive urinary excretion of potentially toxic bile acids are the main causes of injury (30). Odell et al. in homozygous icteric rats, noted accumulation of bilirubin in the renal papilla (31). However, there are few studies that have documented the effects on kidney function of hyperbilirubinemia in humans.

Increased serum levels of bile acids or bilirubin can impair proximal tubular function (proximal tubulopathy), which resolves as the serum levels normalize (21). As proof of tubular dysfunctions by bilirubins, Bairaktari et al. demonstrated in 35 patients with OJ that uricosuria and phosphaturia, imitating Fanconi syndrome, were present (32). They performed a noninvasive study of the renal tubular function, by evaluating the excretion pattern of low-molecular weight endogenous metabolites. On admission, patients with OJ had significantly lower serum uric acid and phosphate levels and higher bile acid concentrations compared with 40 age- and sex-matched controls. Serum uric acid levels presented a negative correlation with total and direct bilirubin as well as fractional excretion of uric acid. These patients were more prone to developing proximal tubular dysfunction such as glucosuria, phosphaturia, and increased excretion of alpha (1)-microglobulin, decreased levels of citrate and Hippurate, and increased levels of 3-hydroxybutyrate and acetate. In 12 patients, partial or complete remission of jaundice was followed by an improvement of the proximal renal tubular damage, which can be interpreted as transitory tubular renal dysfunction caused by bilirubin (32). Increased urinary sodium excretion and decreased free and negative water clearances were observed in patients with total serum bilirubin >27.0 mg/dL. These were further exacerbated in the presence of f hypoalbuminemia. These findings suggest that bilirubin inhibits sodium chloride reabsorption in the thick ascending limb of Henle's loop and alters Anti-diuretic hormone (ADH) function in the collecting tubules, resulting in increased hydraulic conductivity and decreased free water clearance (26)

Cholemic nephropathy and histologic lesions of the renal tubules

The vast majority of histologic lesions in CN have been reported in the tubular segment of the nephron (Figure 1). Holmes studied 68 autopsies of OJ patients and observed swelling of the tubular epithelium, pigmented casts, hypertrophy, and hyperplasia of the parietal layer of Bowman's capsule in 50 (73.5%) cases (33). Van Slambprouck et al. carried out a clinicopathological study in 44 jaundice patients and identified that biliary pigments cause obstructive and inflammatory renal damage, identical to myeloma or myoglobin nephropathy (21). This study described the presence of tubular bile casts across the renal tubules, and the casts significantly correlated with higher total and direct bilirubin levels in serum, and a trend toward higher sCr, aspartate transaminase (AST), and alanine transaminase (ALT) levels. Most interestingly, bile casts were predominantly present in jaundice patients with cirrhosis, especially in those related to alcohol (21). Krones et al. have described the typical appearance of kidneys macroscopically and microscopically (1).

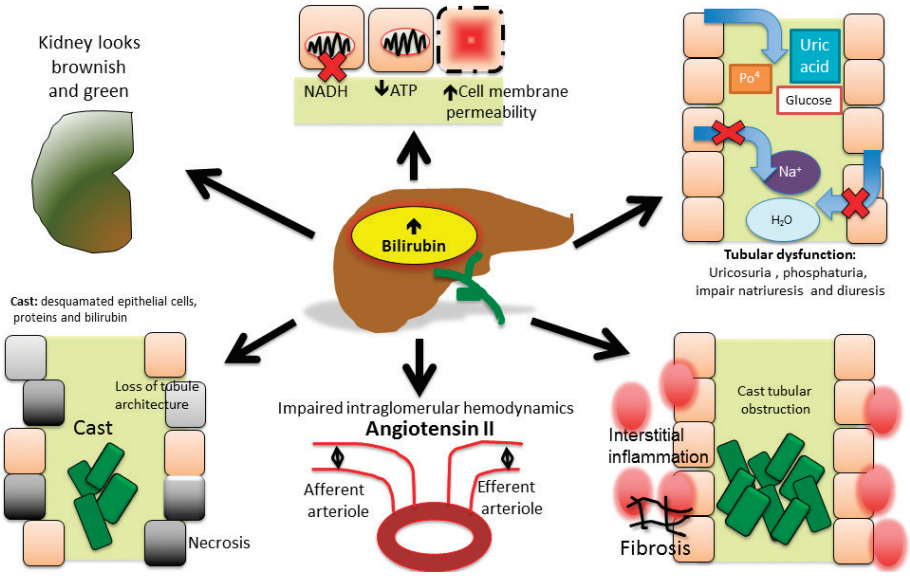

Figure 1. Interactions between hyperbilirubinemia and kidney. Macroscopically, the kidney may look brownish or greenish. In renal tubular cells, hyperbilirubinemia affects mitochondrial function, causes phosphaturia, uricosuria, and glycosuria. Hyperbilirubinemia also changes the tubular architecture with necrosis and apoptosis, modulates the tonicity of the afferent and efferent arteriole, and, through the formation of casts, it generates obstruction and tubulointerstitial inflammation.

Macroscopically, kidneys looked yellow or green due to the high concentration of bilirubin. Histologically, normal glomeruli are found with dilated tubules, obstructed by intraluminal casts. With Hall (or Fouchet) histochemical stain, these casts appear as green to yellow casts, and with periodic-acid Schiff (PAS) staining, they appear as red to dark red-colored casts. In Masson trichrome staining using aniline green, bile casts show a green color. In addition to bile casts, kidney histology may show variable degrees of acute tubular injury as in tubular acute necrosis and intense inflammatory reaction.

Treatment and outcome

The lack of specific therapeutic options remains an important limitation for the clinical management of CN (34). As the liver injury resolves and renal function recovers, the bile-stained casts in the urine decrease in frequency until they disappear altogether (35, 36).

The treatment is primarily supportive; renal replacement therapy has no role in directly treating CN but may be instituted for other indications. The total bilirubin is also a strong predictor of mortality in patients with cirrhosis and kidney failure. In a retrospective univariate analysis, high bilirubin values >3.6 mg/dL were associated with 30-day mortality (OR 7.20, 1.55-33.56 CI) (37).

In a prospective study, Nazar et al. assessed the predictive factors of response to treatment with terlipressin and albumin in patients with type 1 HRS. One of the independent predictive factors of response to therapy was baseline serum bilirubin levels, and the cutoff level of serum bilirubin that best predicted response to treatment was 10 mg/dL (area under the curve (AUC) 0.77; $P < 0.0001$; sensitivity, 89%; specificity, 61%). Response rates in patients with serum bilirubin <10 mg/dL or ≥10 mg/dL were 67 and 13%, respectively ($P = 0.001$) (38).

Ursodeoxycholic acid (UDCA) is thought to reduce bile toxicity by increasing the hydrophilicity index of biliary bile acids, exerting an anti-apoptotic effect, and initiating possible anti-inflammatory action related to its glucocorticoid receptor agonist activity (39); however, the effect of UDCA in CN has not been clinically proven yet. In addition, norursodeoxycholic acid (NorUDCA) has antilipotoxic, antiproliferative, antifibrotic as well as anti-inflammatory effects, potentially helping improve bile duct injury (40). Krones et al. explored the therapeutic efficacy and mechanisms of (NorUCDA) in CN in a murine model. In CBDL mice fed with NorUDCA, they found that NorUDCA significantly lowered the serum urea and uNGAL levels, resulting in less severe CN as demonstrated by normal urine cytology and significantly reduced tubulointerstitial nephritis and renal fibrosis as compared to controls. Potentially, norUDCA may represent an option for the treatment of CN (41). Other treatments aiming to reduce bilirubin levels in patients with CN, such as farsenoid X receptors, peroxisome proliferator-activated receptor α, pregnane X receptor, and glucocorticoid receptor, might be used in future studies (40).

Removing bilirubin from the circulation makes sense and has been previously tried by means of extracorporeal treatment. Sens et al. reported the case of a 37-year-old male

who presented with a sudden alteration of his clinical status in the context of the onset of jaundice and pruritus. Laboratory findings showed hyperbilirubinemia (344 mmol/L), mostly conjugated (260 mmol/L), and AKI. In order to decrease the hyperbilirubinemia and limit its nephrotoxicity, the patient received nine extracorporeal albumin dialysis (ECAD) sessions: one with molecular adsorbent recirculating system (MARS) and eight with single-pass albumin dialysis (SPAD). The first four sessions reduced the bilirubin level from 480 to 172 mmol/L, and the sCr from 444 to 248 mmol/L without requiring hemodialysis. The aim of ECAD was to reduce endogenous albumin-bound toxins accumulated during liver failure. The two methods used in this case report, namely the MARS and SPAD techniques, proved their feasibility and efficacy to reduce bilirubin levels in plasma to a similar extent (25).

Conclusion

CN is renal dysfunction due to hyperbilirubinemia, appearing when bilirubin is greater than 20 mg/dL. Although it occurs frequently, it is underdiagnosed. It is obstructive and cytotoxic. The mechanisms of injury, although not precisely known, appears to involve inflammation. There is no established therapeutic approach for its management. It seems plausible to explore the use of antioxidants that limit the secondary reaction of bilirubin with renal tubules, drugs that limit the production of bile salts, and affordable treatments such as extracorporeal removal of bilirubin from blood.

Conflict of interest

The authors declare no potential conflicts of interest with respect to research, authorship, and/or publication of this article.

References

1. Krones E, Pollheimer MJ, Rosenkranz AR, Fickert P. Cholemic nephropathy—Historical notes and novel perspectives. Biochim Biophys Acta Mol Basis Dis. 2018;1864(4 Pt B):1356–66. http://dx.doi.org/10.1016/j.bbadis.2017.08.028
2. Hecher R, Sherlock S. Electrolyte and circulatory changes in terminal liver failure. Lancet 1956;2:1121–5. http://dx.doi.org/10.1016/S0140-6736(56)90149-0
3. Schroeder ET, Shear L, Sancetta SM, Gabuzda GJ. Renal failure in patients with cirrhosis of the liver. 3. Evaluation of intrarenal blood flow by para-aminohippurate extraction and response to angiotensin. Am J Med. 1967;43(6):887–96. http://dx.doi.org/10.1016/0002-9343(67)90247-1
4. Aniort J, Poyet A, Kemeny JL, Philipponnet C, Heng AE. Bile cast nephropathy caused by obstructive cholestasis. Am J Kidney Dis. 2017;69(1):143–6. http://dx.doi.org/10.1053/j.ajkd.2016.08.023
5. Gonwa TA, Wadei HM. Kidney disease in the setting of liver failure: Core curriculum 2013. Am J Kidney Dis. 2013;62(6):1198–212. http://dx.doi.org/10.1053/j.ajkd.2013.07.017
6. Kalakonda, A. John, S. Physiology: Bilirubin. Treasure Island, FL: StatPearls Publishing; 2018.
7. Memon N, Weinberger BI, Hegyi T, Aleksunes LM. Inherited disorders of bilirubin Clearance. Pediatr Res. 2016;79(3):378–86. http://dx.doi.org/10.1038/pr.2015.247
8. Roche SP, Kobos R. Jaundice in the adult patient. Am Fam Physician. 2004;69(2):299–304.
9. Sticova E, Jirsa M. New insights in bilirubin metabolism and their clinical implications. World J Gastroenterol. 2013;19(38):6398–407. http://dx.doi.org/10.3748/wjg.v19.i38.6398
10. Angeli P, Merkel C. Pathogenesis and management of hepatorenal syndrome in patients with cirrhosis. J Hepatol. 2008;48:S93–103. http://dx.doi.org/10.1016/j.jhep.2008.01.010
11. Follo A, Llovet JM, Navasa M, Planas R, Forns X, Francitorra A, et al. Renal impairment after spontaneous bacterial peritonitis in cirrhosis: Incidence, clinical course, predictive factors and prognosis. Hepatology. 1994;20(6):1495–501. http://dx.doi.org/10.1002/hep.1840200619
12. Thabut D, Massard J, Gangloff A, Carbonell N, Francoz C, Nguyen-Khac E, et al. Model for end-stage liver disease score and systemic inflammatory response are major prognostic factors in patients with cirrhosis and acute functional renal failure. Hepatology. 2007;46(6):1872–82. http://dx.doi.org/10.1002/hep.21920
13. Fasolato S, Angeli P, Dallagnese L, Maresio G, Zola E, Mazza E, et al. Renal failure and bacterial infections in patients with cirrhosis: Epidemiology and clinical features. Hepatology. 2007;45(1):223–9. http://dx.doi.org/10.1002/hep.21443
14. Montoliu S, Ballesté B, Planas R, Alvarez MA, Rivera M, Miquel M, et al. Incidence and prognosis of different types of functional renal failure in cirrhotic patients with ascites. Clin Gastroenterol Hepatol. 2010;8(7):616–22. http://dx.doi.org/10.1016/j.cgh.2010.03.029
15. Ginès P, Schrier RW. Renal failure in cirrhosis. N Engl J Med. 2009;361:1279–90. http://dx.doi.org/10.1056/NEJMra0809139
16. Martín-Llahí M, Guevara M, Torre A, Fagundes C, Restuccia T, Gilabert R, et al. Prognostic importance of the cause of renal failure in patients with cirrhosis. Gastroenterology 2011;140(2):488–96. http://dx.doi.org/10.1053/j.gastro.2010.07.043
17. Angeli P, Ginès P, Wong F, Bernardi M, Boyer TD, Gerbes A, et al. Diagnosis and management of acute kidney injury in patients with cirrhosis: Revised consensus recommendations of the International Club of Ascites. J Hepatol. 2015;62(4):968–74. http://dx.doi.org/10.1016/j.jhep.2014.12.029
18. Spencer K. Analytical reviews in clinical biochemistry: The estimation of creatinine. Ann Clin Biochem 1986;23(Pt. 1):1–25. http://dx.doi.org/10.1177/000456328602300101
19. Watkins RE, Felkamp CS, Thibert RJ, Zak B. Interesting interferences in a direct serum creatinine reaction. Microchem J. 1976;21(4):370–84. http://dx.doi.org/10.1016/0026-265X(76)90056-4
20. Poge U, Gerhardt T, Stoffel-Wagner B, Klehr HU, Sauerbruch T, Woitas RP. Calculation of glomerular filtration rate based on cystatin C in cirrhotic patients. Nephrol Dial Transplant. 2006;21(3):660–4. http://dx.doi.org/10.1093/ndt/gfi305
21. van Slambrouck CM, Salem F, Meehan SM, Chang A. Bile cast nephropathy is a common pathologic finding for kidney injury associated with severe liver dysfunction. Kidney Int. 2013;84(1):192–7. http://dx.doi.org/10.1038/ki.2013.78
22. Kellum JA, Lameire N, Aspelin P, Barsoum RS, Burdmann EA, Goldstein SL et al. Kidney disease: Improving global outcomes (KDIGO) acute kidney injury work group. KDIGO clinical practice guideline for acute kidney injury. Kidney Int Supplements. 2012;1;2(1):1–138.

23. Fede G, D'Amico G, Arvaniti V, Tsochatzis E, Germani G, Georgiadis D, et al. Renal failure and cirrhosis: A systematic review of mortality and prognosis. J Hepatol. 2012;56(4):810–18. http://dx.doi.org/10.1016/j.jhep.2011.10.016
24. Fagundes C, Barreto R, Guevara M, Garcia E, Solà E, Rodríguez E, et al. A modified acute kidney injury classification for diagnosis and risk stratification of impairment of kidney function in cirrhosis. J Hepatol. 2013;59(3):474–81. http://dx.doi.org/10.1016/j.jhep.2013.04.036
25. Sens F, Bacchetta J, Rabeyrin M, Julliard L. Efficacy of extracorporeal albumin dialysis for acute kidney injury due to cholestatic jaundice nephrotoxicity. BMJ Case Rep. 2016;2016:1–5. http://dx.doi.org/10.1038/ki.1990.296
26. Sitprija V, Kashemsant U, Sriratanaban A, Arthachinta S, Poshyachinda V. Renal function in obstructive jaundice in man: Cholangiocarcinoma mode. Kidney Int. 1990;38(5):948–55. http://dx.doi.org/10.1038/ki.1990.296
27. Mohapatra MK, Behera AK, Karua PC, Bariha PK, Rath A, Aggrawal KC, et al. Urinary bile casts in bile cast nephropathy secondary to severe falciparum malaria. Clin Kidney J. 2016;9(4):644–8. http://dx.doi.org/10.1093/ckj/sfw042
28. Betjes M, Bajema I. The pathology of jaundice-related renal insufficiency: Cholemic nephrosis revisited. J Nephrol. 2006;19(2):229–33.
29. Martínez-Cecilia. D, Reyes-Díaz M, Ruiz-Rabelo J, Gomez-Alvarez M, Villanueva CM, Álamo J, et al. Oxidative stress influence on renal dysfunction in patients with obstructive jaundice: A case and control prospective study. Redox Biol. 2016;8:160–4. http://dx.doi.org/10.1016/j.redox.2015.12.009
30. Fickert P, Krones E, Pollheimer MJ, Thueringer A, Moustafa T, Silbert D, et al. Bile acids trigger cholemic nephropathy in common bile-duct-ligated mice. Hepatology. 2013;58(6):2056–69. http://dx.doi.org/10.1002/hep.26599
31. Odell GB, Bolen JL, Poland RL, Seungdambong S, Cukier JO. Protection from bilirubin nephropathy in jaundiced Gunn rats. Gastroenterology. 1974;66(6):1218–24.
32. Bairaktari E, Liamis G, Tsolas O, Elisaf M. Partially reversible renal tubular damage in patients with obstructive jaundice. Hepatology. 2001;33(6):1365–9. http://dx.doi.org/10.1053/jhep.2001.25089
33. Holmes TW Jr. The histologic lesion of cholemic nephrosis. J Urol. 1953;70(5):677–85. http://dx.doi.org/10.1016/S0022-5347(17)67968-0
34. Jain K, Gupta A, Singh HK, Nickeleit V, Kshirsagar AV. Bile cast nephropathy. Kidney Int. 2015;87(2):484. http://dx.doi.org/10.1038/ki.2014.233
35. Elsom KA. Renal function in obstructive jaundice. Arch Intern Med (Chic). 1937;60 (6):1028–33. http://dx.doi.org/10.1001/archinte.1937.00180060081008
36. Thompson LL, Frazier WD, Ravdin LS. The renal lesion in obstructive jaundice. Am J Med Sci. 1940;199:305–12. http://dx.doi.org/10.1097/00000441-194003000-00001
37. Licata A, Maida M, Bonaccorso A, Macaluso FS, Cappello M, Craxì A, et al. Clinical course and prognostic factors of hepatorenal syndrome: A retrospective single-center cohort study. World J Hepatol. 2013;27;5(12):685–91.
38. Nazar A, Pereira GH, Guevara M, Martín-Llahi M, Pepin MN, Marinelli M, et al. Predictors of response to therapy with terlipressin and albumin in patients with cirrhosis and type 1 hepatorenal syndrome. Hepatology. 2010;51(1):219–26. http://dx.doi.org/10.1002/hep.23283
39. de Vries E, Beuers U. Management of cholestatic disease in 2017. Liver Int. 2017;37(Suppl. 1):123–9. http://dx.doi.org/10.1111/liv.13306
40. Moustafa T, Fickert P, Magnes C, Guelly C, Thueringer A, Frank S, et al. Alterations in lipid metabolism mediate inflammation, fibrosis, and proliferation in a mouse model of chronic cholestatic liver injury. Gastroenterology. 2012;142(1):140–51. http://dx.doi.org/10.1053/j.gastro.2011.09.051
41. Krones E, Eller K, Pollheimer MJ, Racedo S, Kirsch AH, Frauscher B, et al. Nor Ursodeoxycholic acid ameliorates cholemic nephropathy in bile duct ligated mice. J Hepatol. 2017;67(1):110–19. http://dx.doi.org/10.1016/j.jhep.2017.02.019