

## Stromal Expression of CD-10 in Breast Carcinoma and its Association with Estrogen, Progesterone receptors, Her2Neu and Tumor Grade

Qudsia Ishaq<sup>1</sup>, Nosheen Nabi<sup>2</sup>, Armaghana Qamar Khan<sup>3</sup>, Summaya Sohail Chaudry<sup>4</sup>, Anam Ishaq<sup>5</sup>, Ashok Kumar Tanwani<sup>6</sup>

<sup>1</sup>Senior Lecturer, Pathology Department, Rawal Institute of Health Sciences, Islamabad

<sup>2</sup>Assistant Professor, Pathology Department, Rawal Institute of Health Sciences, Islamabad

<sup>3,4</sup>Medical Officer, Pathology Department, Pakistan Institute of Medical Sciences, Islamabad

<sup>5</sup>Senior Clinical Fellow, Medicine, Manchester Royal Infirmary, Manchester, UK

<sup>6</sup>Head of Department and Professor of Pathology, HBS Medical & Dental College, Islamabad

### ABSTRACT

**Introduction:** In previous studies, role of stromal component in epithelial malignancies has been highlighted. CD10 is a member of metalloproteinase family that breaks down the protein components of extracellular matrix and epithelial tissue remodeling thus playing an important role in carcinogenesis and metastasis.

To evaluate CD 10 expression in breast carcinoma and assess its association with grade of the tumor, ER, PR and Her 2 Neu status.

**Methodology:** The study was carried in Federal Government Polyclinic Hospital (FGPH) and Pakistan Institute of Medical Sciences (PIMS), Islamabad. Immunohistochemical panel of CD 10, ER, PR and Her 2 was applied to 171 cases of invasive breast carcinoma. The association of CD 10 and ER/PR status was evaluated.

**Results:** Among 171 cases of breast carcinoma, 77.8% cases were CD-10 positive. A total of 65.5% of ER negative cases expressed strongly positive CD-10 in the stroma as compared to 37.2% of ER positive cases ( $P=0.001$ ). In 64.4% of PR negative cases expressed strong positivity of CD-10 in the stroma compared with 37.5% (42/112) PR positive cases ( $P=0.001$ ). The association of CD-10 with HER-2-NEU was not significant ( $P=0.749$ ). Association of high-grade tumor with CD 10 was not statistically significant ( $P=0.258$ ).

**Conclusion:** It was observed that CD10 expression is associated with negative ER, PR status and with higher grades of the tumors, showing its prognostic significance.

**Key Words:** Breast cancer, CD 10, Estrogen receptors, HER2neu, Progesterone receptors

#### Authors' Contribution:

<sup>1,2</sup>Conception; Literature research; manuscript design and drafting; <sup>2,3</sup>Critical analysis and manuscript review; <sup>5,6</sup>Data analysis; Manuscript Editing.

#### Correspondence:

Nosheen Nabi  
Email: nosheen.nabi@yahoo.com

#### Article info:

Received: January 31, 2022  
Accepted: March 28, 2023

**Cite this article.** Ishaq Q, Nabi N, Khan A Q, Chaudry S S, Ishaq A, Tanwani A K. Stromal Expression of CD-10 in Breast Carcinoma and its Association with Estrogen, Progesterone receptors, Her2Neu and Tumor Grade. J Islamabad Med Dental Coll. 2023; 12(2): 82-87  
DOI: <https://doi.org/10.35787/jimdc.v12i2.845>

**Funding Source:** Nil

**Conflict of interest:** Nil

### Introduction

Breast carcinoma is the second leading cause of cancer related deaths in women.<sup>1</sup> Breast carcinomas make the majority of cases of breast malignancies

while sarcomas arising in breast are rare. Breast carcinomas arise in glandular epithelium so majority of researches are oriented towards carcinogenesis involving glands.<sup>2</sup> Many research studies have found that stroma plays an equally important role in the

progression of carcinoma by providing suitable environment for invasion and metastasis.<sup>3</sup> So the most recent researches, though limited, have been focusing towards new stromal markers for the assessment of prognostic outcomes in invasive breast carcinoma.<sup>4-6</sup>

CD-10 also known as Neprilysin and Common Acute lymphoblastic leukemia/lymphoma Antigen (CALLA) is a Metalloproteinase released by myofibroblasts. It causes extracellular matrix (ECM) degradation. Its expression is not constantly observed in the stromal cells of the normal breast. Nonetheless, it has been observed that CD-10 is expressed in the stromal cells of invasive ductal carcinoma and is associated with biological aggressiveness in the form of higher grades and poor outcome.<sup>7</sup> Studies on CD-10 have also demonstrated its correlation with other established markers of prognosis in breast cancer like Estrogen receptors (ER), Progesterone receptors (PR) and Her-2-neu. Results of these studies revealed that CD10 expression correlates strongly with unfavorable prognostic markers like high tumor grade, ER negativity and decreased overall survival. These earlier results lead to the hypothesis that stromal CD10 may be further explored as an independent prognostic marker and may eventually promote development of newer therapeutic strategies.<sup>8-11</sup>

Present study was planned to evaluate the role of stromal CD10 expression in breast carcinoma and to assess its association with known prognostic factors such as ER, PR and Her2 neu and tumor grade in our local population. The prognostic information would help in individualized treatment planning for better outcomes.

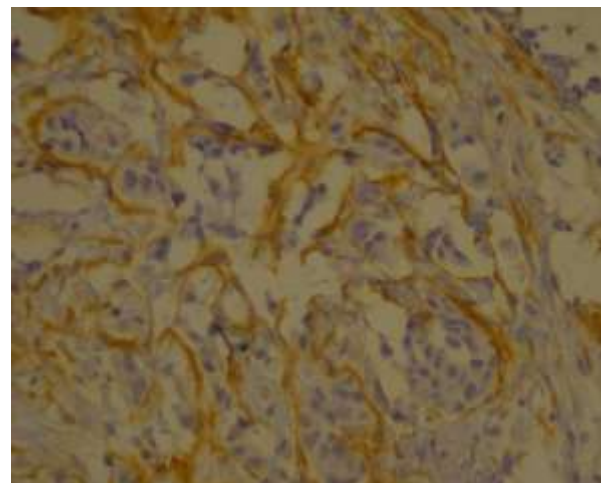
## Methodology

This cross-sectional study was conducted in the Department of Pathology, PIMS (affiliated with Shaheed Zulfiqar Ali Bhutto Medical University (SZABMU) and FGSH Islamabad from 31<sup>st</sup> March

2017 to 31<sup>st</sup> August 2019. In total 171 patients with clinical and histological diagnosis of Invasive Ductal Carcinomas (both ductal and lobular), from age 20-80 years were enrolled in the study. Sample size was calculated according to WHO sample size calculator. Other variants and non-epithelial malignancies were excluded from the study.

After approval from hospital ethical committee and informed consent, data were collected. The surgical specimen and biopsies were collected, fixed in 10% formalin. After fixation the tissue sections were processed in automatic tissue processor and embedded in paraffin followed by cutting, slide preparation and staining with hematoxylin and eosin (H&E) stain. Immunohistochemical staining of CD10 was done with monoclonal mouse anti-human CD10 antibody (monoclonal IgG1 colon (56c6) Labvision USA. ER, PR and Her 2 neu was reported according to Allred scoring system while CD10 staining was scored semi quantitatively as negative (less than 10%), weak (either diffuse weak staining or weak or strong focal staining in less than 30% of stromal cells per core) and strong (defined as strong staining of 30% or more of the stromal cells).<sup>12</sup> (Figure:1)

The data were analyzed on SPSS version17. For quantitative variables (age) mean and standard deviation was estimated. For qualitative variables



**Figure 1: IHC stain with Strong positive CD10 membranous staining in fusiform cells of the stroma (magnification: 400x)**

(grade of tumor and ER, PR, Her2 neu and CD 10 expression groups) frequencies and percentages were estimated. Chi square test was applied to assess the association between CD-10 and ER/PR expression and tumor grade. P-value of  $\leq 0.05$  was taken as statistically significant.

## Results

In total 171 patients with median age of 48 years, 170 patients were invasive ductal carcinomas and only one case was invasive lobular carcinoma. Among total of these patients, 8.8% (15/171) of cases were diagnosed with grade I, 71.3% (122/171) grade II and 19.9% (34/171) grade III invasive breast carcinoma. (Figure 2)

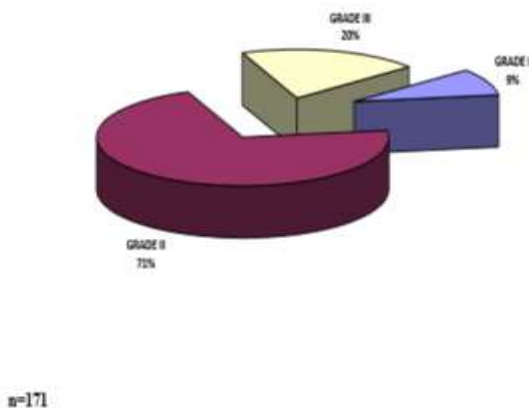


Figure 2. Grading of tumor

Total number of CD 10 positive cases was 77.8% (133/171). Out of them 31% (53/171) were weak positive and 46.8% (80/171) were strongly positive. A total of 66.1% (113/171) cases were ER positive, 65.5% (112/171) cases were PR positive and 29.2% (50/171) were Her-2-Neu positive. (Table 1)

Our results showed a significant association between ER-negative status and CD-10 expression, 65.5% (38/58) of ER negative cases showed strongly

**Table I: Immunohistochemical results of CD 10, ER, PR and Her2 neu (n=171)**

Marker	Frequency	Percentage
ER	Positive	113
	Negative	58
PR	Positive	112
	Negative	59
Her 2 Neu	Positive	50
	Equivocal	38
	Negative	83
CD 10	Negative	38
	Weak positive	53
	Strong	80

positive CD-10 expression in the stroma, compared with 37.2% (42/113) ER positive cases ( $P=0.001$ ). The association between PR and CD-10 was also significant, 64.4% (38/59) of PR negative cases had strongly positive CD-10 expression in the stroma compared with 37.5% (42/112) PR positive cases ( $p$  value-0.001) (Table 2)

The association between HER-2-NEU and CD-10 was not significant (Table 3), 47.0% (39/83) of Her-2-neu negative cases expressed strong positivity of CD-10 in the stroma compared with 50.0% (25/50) Her-2-neu positive cases ( $P=0.749$ ). (Table 3)

The association between higher tumor grade and CD-10 expression was also not significant statistically. (Table 4), 55.9% (19/34) of grade III, 45.1% (55/122) of grade II showed strongly positive CD-10 expression in the stroma compared with 40.0% (06/15) grade 1 cases ( $P=0.258$ ).

**Table II: Association of CD 10 with ER and PR expression**

CD-10 Expression	PR STATUS		Total	p-value
	Positive (n=112)	Negative (n=59)		
Negative	38 (33.9%)	0 (0%)	38 (22.2%)	0.001
Weak Positive	32 (28.6%)	21 (35.6%)	53 (31.0%)	
Strong Positive	42 (37.5%)	38 (64.4%)	80 (46.8%)	

CD-10 Expression	HER-2-NEU STATUS			Total	P-Value
	Positive (n=50)	Equivocal (n=38)	Negative (n=83)		
Negative	12 (24.0%)	7 (18.4%)	19 (22.9%)	38 (22.2%)	0.749
Weak positive	13 (26.0%)	15 (39.5%)	25 (30.1%)	53 (31.0%)	
Strong positive	25 (50.0%)	16 (42.1%)	39 (47.0%)	80 (46.8%)	

CD-10 Expression	Tumor Grade			Total (n=171)	P-Value
	Grade I (n=15)	Grade II (n=122)	Grade III (n=34)		
Negative	6 (40.0%)	28 (23.0%)	4 (11.7%)	38 (22.2%)	0.258
Weak Positive	3 (20.0%)	39 (32.0%)	11 (32.4%)	53 (31.0%)	
Strong Positive	6 (40.0%)	55 (45.0%)	19 (55.9%)	80 (46.8%)	

## Discussion

The stromal involvement in carcinogenesis is important as it provides the microenvironment which facilitates in tumor invasive properties.<sup>13</sup> Studying this interaction between epithelium and stroma can be helpful in finding the prognostic markers and novel therapeutic agents. CD-10 is a stromal marker studied in invasive breast carcinomas and its association with other well established prognostic markers was evaluated.<sup>14</sup> In our study, we found that majority of cases (77.8%) were CD-10 positive. Ulaganathan S. et al assessed CD-10 expression in 30 women and reported CD10 positivity in stroma of 22 (73%) cases.<sup>15</sup> Makretsov NA. et al in the similar type of study reported that 79% (205/258) cases were CD-10 positive.<sup>16</sup> Stromal CD-10 expression was found to be negatively associated with ER and PR expression,

which was statistically significant ( $P=0.001$ ) and positively associated with tumor grade, which was also fairly strong ( $P=0.258$ ). Chattopadhyay M et al. also demonstrated similar results i.e. positive correlation between CD-10 and tumor grade and negative correlation with ER ( $P<0.05$ ). However, they also demonstrated statistically significant correlation between CD10 expression and Her-2 neu positivity.<sup>17</sup> The possible explanation of CD-10 positivity and its association with ER and PR negativity in the present study may be attributed to the ability of CD-10 as a part of an independent signaling pathway which leads to down-regulation of ER, PR expression in the tumor cells, or may lead to differentiating of tumor cells which lack ER and PR receptors expression. Results of another study, reported by Jana SH, et al, are quite similar to our results. They demonstrated significant association between stromal CD-10 expression and increasing tumor grades, worse prognosis and ER negativity ( $P<0.05$ ). They did not find any significant association between CD-10 expression and PR and Her-2-neu expression status ( $P>0.05$ ).<sup>18</sup>

Devi ABV, et al in his study demonstrated significant association of stromal expression of CD10 with increasing size of tumor, higher grades, lymph node positivity and poor prognosis ( $P<0.05$  in all cases). In the present study similar trend was observed for tumor grades, however, we did not determine the association with tumor size and lymph node status.<sup>19</sup> Louhichi T et al concluded in his study that CD 10 positivity is related to high tumor grade.<sup>20</sup> Since majority of cases in our study population were Her 2-neu negative, therefore, the results did not reach statistically significant conclusion.

Results of present study, and substantial evidence in the literature suggest a significant role of stromal CD10 in invasive breast carcinoma pathogenesis and prognosis. We conclude that CD10 expression correlates strongly with well-established negative prognostic markers that is ER/PR negativity, and higher tumor grade. This indicates that CD10 can be used as independent marker indicating poor

prognosis and predicting response to chemotherapy. It may prove to be a potential target for development of novel therapies.

## Conclusion

Present study showed that in women with invasive breast carcinoma, expression of CD-10 in stroma was found to be significantly associated with ER and PR negative status. It may be used as potential prognostic marker and a target for development of new therapeutic drugs.

## Limitations

There are few limitations of the present study:

- We were not able to follow the patients for longer durations, so the exact implications of study results on long term survival could not be determined. Secondly, the sample size was relatively smaller. A similar study with large sample size and follow up of patients is recommended.
- Most cases in our study population were grade II, we recommend more studies with larger sample size to find associations with all grades of tumor.
- We did not take the tumor size and lymph node metastases into account to measure their association with CD 10 status in the present study. It is thus recommended to look into association of these variables with CD-10 in future trials.

## References

1. Watkins EJ. Overview of breast cancer. *Journal of the American Academy of PAs*. 2019 Oct 1;32(10):13-7.
2. Rizk AM, Abdelzaher E, Gowil AG, Elsaka RO. Stromal expression of CD10 in invasive breast carcinoma and its correlation with clinicopathological parameters. *Egyptian Journal of Pathology*. 2017 Jul 1;37(1):1-7.
3. Dhande AN, Khandeparkar SG, Joshi AR, Kulkarni MM, Pandya N, Mohanapure N et al . Stromal expression of CD10 in breast carcinoma and its

- correlation with clinicopathological parameters. *South Asian journal of cancer*. 2019 Jan;8(01):18-21.
4. Puri V, Jain M, Mahajan G, Pujani M. Critical appraisal of stromal CD10 staining in fibroepithelial lesions of breast with a special emphasis on expression patterns and correlation with WHO grading. *J Cancer Res Ther*. 2016;12(2):667-70
5. Witkiewicz AK, Freydin B, Chervoneva I, Potoczek M, Rizzo W, Rui H, Brody JR, Schwartz GF, Lisanti MP. Stromal CD10 and SPARC expression in ductal carcinoma in situ (DCIS) patients predicts disease recurrence. *Cancer biology & therapy*. 2010 Aug 15;10(4):391-6.
6. Mishra D, Singh S, Narayan G. Role of B cell development marker CD10 in cancer progression and prognosis. *Molecular biology international*. 2016. Volume 2016, Article ID 4328697, 9 pages <http://dx.doi.org/10.1155/2016/4328697>
7. Qatleesh S, Sammoun A, Chatty ME. CD10 Expression in Breast Carcinoma and Its Correlation with CD105. *Annals of the Romanian Society for Cell Biology*. 2021 Jul 10;25(6):16266-74.
8. Lengare PV, Khandeparkar SG, Joshi AR, Gogate BP, Solanke SG, Gore SH. Immunohistochemical expression of cyclin D1 in invasive breast carcinoma and its correlation with clinicopathological parameters. *Indian Journal of Pathology and Microbiology*. 2020 Jul 1;63(3):376.
9. Vo TN, Mekata E, Umeda T, Abe H, Kawai Y, Mori T et al. Murata S. Prognostic impact of CD10 expression in clinical outcome of invasive breast carcinoma. *Breast cancer*. 2015 Mar;22(2):117-28.
10. Mohammadzadeh F, Salavati M, Moghaddam NA. CD10 expression in stromal component of invasive breast carcinoma: A potential prognostic determinant. *J Res Med Sci*. 2012 Mar 1;2:194-9.
11. Thomas S, Babu RJ, Agarwal K, Puri V, Jain M, Andley M, Tudu SK. Effect of neoadjuvant chemotherapy on stromal CD10 antigens in breast cancer-A preliminary study. *Indian Journal of Cancer*. 2013 Jan 1;50(1):46.
12. Ali HD, Jalal JA, Ismail AT, Alnuaimy WM. Stromal CD10 expression in invasive breast carcinoma. *Zanco Journal of Medical Sciences (Zanco J Med Sci)*. 2018 Apr 1;22(1):41-8.
13. Clegg J, Koch MK, Thompson EW, Haupt LM, Kalita-de Croft P, Bray LJ. Three-dimensional models as a new frontier for studying the role of proteoglycans in the normal and malignant breast microenvironment. *Frontiers in Cell and Developmental Biology*. 2020 Oct 9;8:1080.
14. Kamal M, Khan R, Hasan SH, Maheshwari V. Evaluation of stromal CD10 expression and its correlation with other clinico-pathological factors in

- invasive breast carcinoma. *Indian Journal of Pathology and Oncology*. 2019 Jul;6(3):417-21.
15. Ulaganathan S. An Analysis of Correlation of Stromal CD10 Expression in Carcinoma Breast NOS Type with ER, PR and HER2/Neu. *Int. J. Adv. Res.* 10(07), 212-217. doi:10.21474/IJAR01/15022
  16. Makretsov NA, HayesM, CarterBA, Dabiri S,Gilks CB, HuntsmanDG. Stromal CD10 expression in invasive breast carcinoma correlates with poor prognosis, estrogen receptor negativity, and high grade. *Mod Pathol*. 2007;20(1):84-9.
  17. Chattopadhyay M, Giri R, Senapati U. CD10 expression by stromal cells in carcinoma of breast and its correlation with ER, PR, HER2neu and Ki67-A tissue microarray study in a tertiary care hospital. *Indian Journal of Pathology and Oncology*. 2019 Jul;6(3):445-7.
  18. Jana SH, Jha BM, Patel C, Jana D, Agarwal A.CD10-a new prognostic stromal marker in breast carcinoma, its utility, limitations and role in breast cancer pathogenesis. *Indian J Pathol Microbiol*. 2014;57(4):530-6.
  19. Devi ABV, S. Sekhar SC, Anil SS, H. Rani HS. A study on stromal CD10 expression in invasive breast carcinoma. *IAIM*, 2016; 3(6): 142-47.
  20. Louhichi T, Saad H, Dhiab MB, Ziadi S, Trimeche M. Stromal CD10 expression in breast cancer correlates with tumor invasion and cancer stem cell phenotype. *BMC cancer*. 2018 Dec 1;18(1):49.