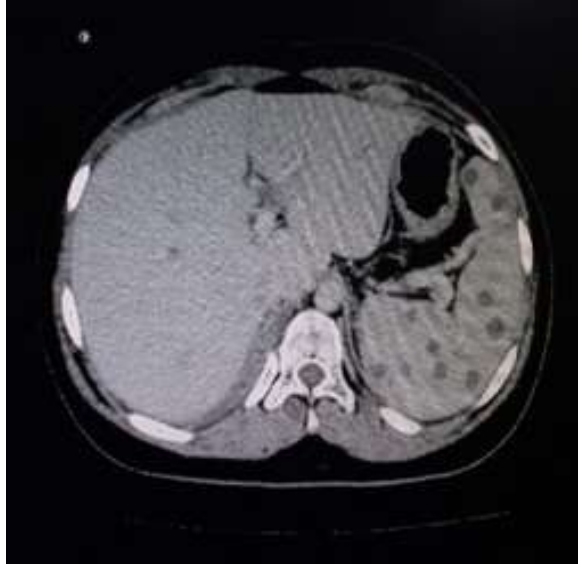
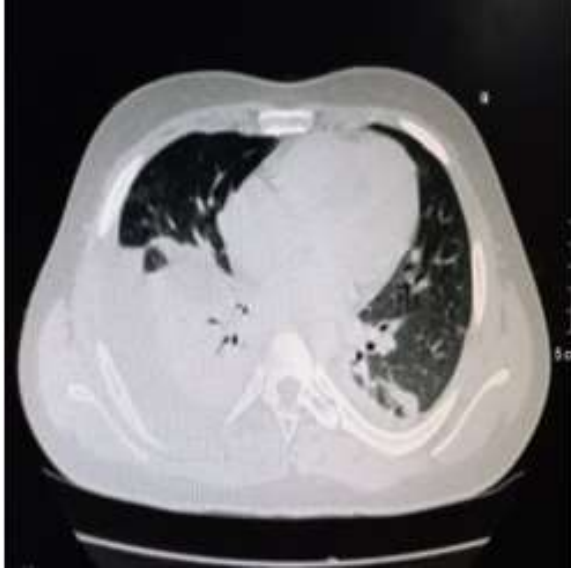
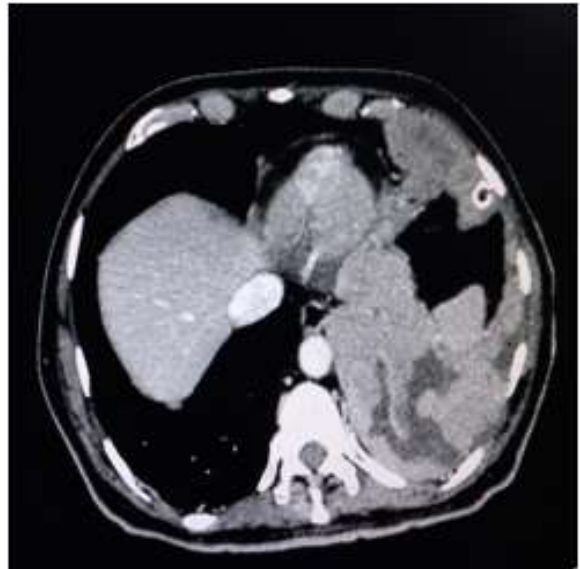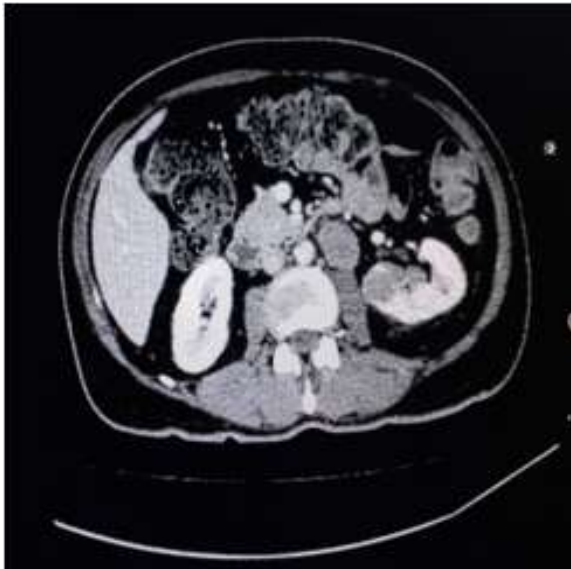## Radiological Images

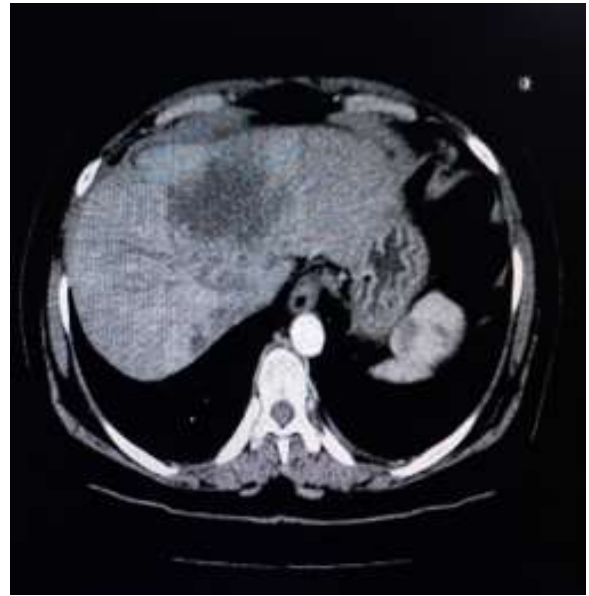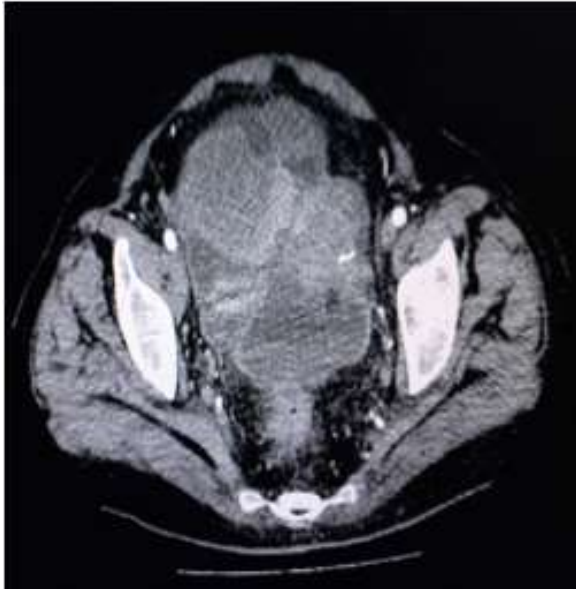
**Post Bone Marrow Transplant--- Engraftment Syndrome and Disseminated Fungal Infection**



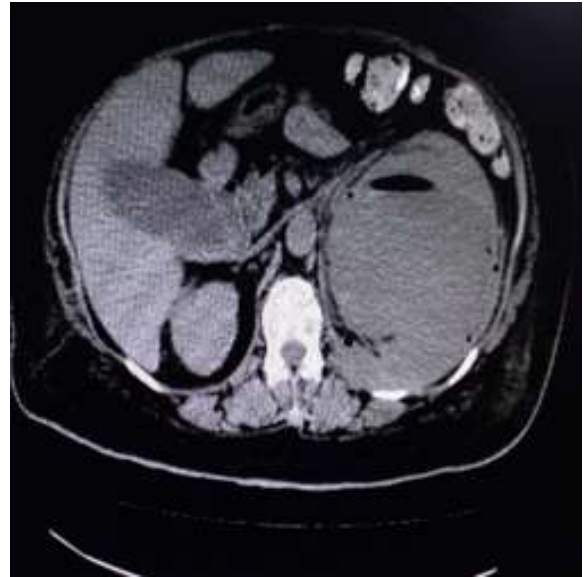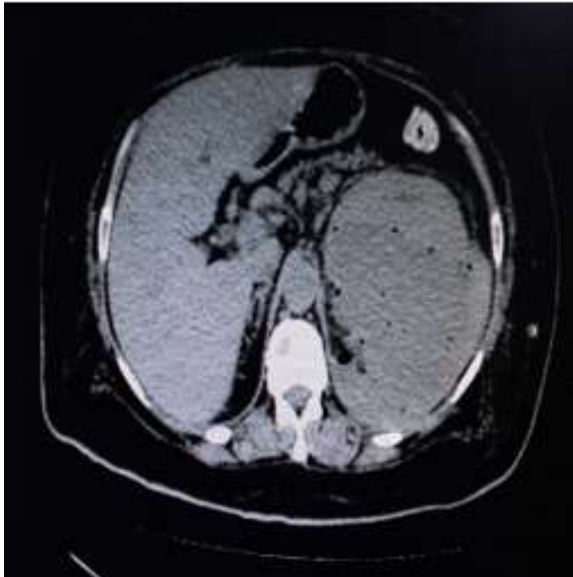**Left Renal Cell Carcinoma with Pleural Metastases**



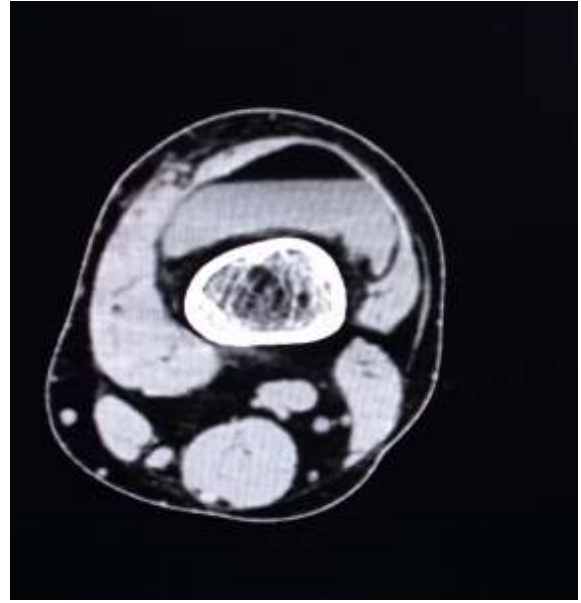
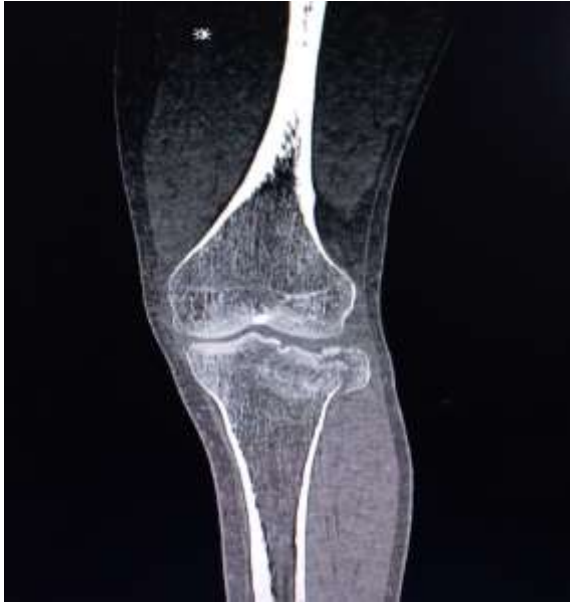**Endometroid Carcinoma of Ovary with Hepatic Metastases**



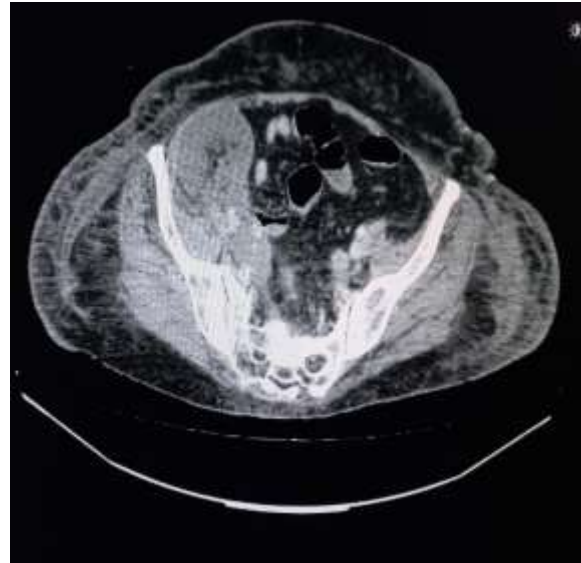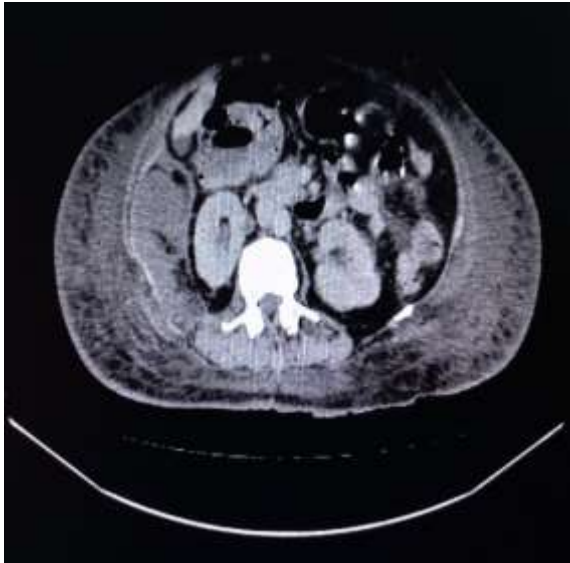**Large Left Renal Subcapsular Abscess in a Diabetic Patient**



## Tibial Plateau Fracture with Lipoarthrosis



## Large Retroperitoneal Hematoma



### Contributed by:

*Department of Radiology  
Dr. Akbar Niazi Teaching Hospital, Islamabad*