

High Resolution Computed Tomography Chest Findings Among Post-COVID Patients

Rabia Shahid¹, Muhammad Saleem Akhter², Muhammad Waseem³, Maryam Rafiq³

¹House officer, Department of Pulmonology, Sahiwal Teaching hospital, Sahiwal.

²Assistant Professor and Head of Department, Radiology, Sahiwal Teaching Hospital, Sahiwal.

³Assistant Professor and Head of Department, Pulmonology, Sahiwal Teaching Hospital, Sahiwal.

⁴Assistant Professor, Department of Chemical Pathology, Sahiwal Teaching Hospital, Sahiwal.

ABSTRACT

Background: High resolution computed tomography (HRCT) chest has proven to be a helpful radiological modality to assess the course of disease. The main objective of the study was to analyze the pattern of lung involvement on HRCT chest among post-Covid patients.

Methodology: This cross-sectional study was carried out in the post Covid patients (30 days after discharge) from Nov 2020 to July 2021 in Sahiwal Teaching Hospital, Pakistan. Total 180 patients were selected through non probability consecutive sampling technique. Whole body Multi Slice CT scan, 128 Slices by GE discovery was used to get HRCT of chest and to document various patterns and stages of pulmonary fibrosis in the post-COVID patients. The data was analyzed using the IBM SPSS 28.0.0 2021. Various radiological findings were expressed in percentages.

Results: A total of 77.8% patients had bilateral lung involvement, while 22.2% had unilateral lung involvement after one month of disease. Ground Glass Haze was the commonest radiological pattern, found in 140 (77.8%) cases. Other radiological patterns were Air Space Opacification (47.2%), Septal Thickening (20%) and Fibrotic Bands (26.1%). Traction Bronchiectasis (10%) and Honey Combing (7.8%) were among the lesser ones reported. About 62% patients had mixed findings on HRCT Chest. Diagnosis of Organizing Pneumonia was made in 166 (92.22%) patients while 14 (7.78%) patients were labelled as Usual Interstitial Pneumonia (UIP) with honey-combing in HRCT chest. The involvement of Right Lower Lobe was in 165 (91.7%) of cases. Right Middle Lobe remained fairly spared and was seen in 120 (66.7%) cases.

Conclusion: Patchy ground glass haze seen bilaterally in lower lung lobes are the commonest abnormalities in HRCT chest of post-COVID patients.

Keywords: Covid-19, Pneumonia, Radiology

Authors' Contribution:

¹Conception; Literature research; manuscript design and drafting; ^{2,3}Critical analysis and manuscript review; ⁴Data analysis; Manuscript Editing.

Correspondence:

Maryam Rafiq
Email: mariamsheikh15@yahoo.com

Article info:

Received: September 21, 2021
Accepted: September 9, 2022

Cite this article. Shahid R, Akhter S M, Waseem M, Rafiq M. High Resolution Computed Tomography (HRCT) Chest Findings Among Post-COVID Patients. J Islamabad Med Dental Coll. 2022;11(3): 164-168

Funding Source: Nil
Conflict of Interest: Nil

DOI: <https://doi.org/10.35787/jimdc.v11i3.789>

Introduction

The modern-day world is plagued by many disease epidemics. Once every few decades, there comes a microorganism that puts human life at halt. Arising

from Wuhan, China in December 2019, the disease caused by Novel Coronavirus or SARS-CoV-2 was declared as a Public Health Emergency of International Concern on 30th January 2020. It was

labelled a Global Pandemic by the World Health Organization on 11th March 2020.¹ While the leading researchers and scientists took it upon themselves to serve humanity by developing cure and preventive vaccines within record time, the virus had already wreaked havoc. As of August 2021, there have been a total of more than 200 million confirmed cases and over 4 million deaths worldwide.¹

The disease presents itself as a respiratory tract infection with symptoms such as fever, cough, dyspnea, muscle pain and fatigue.² With the newer variants, such as, delta, the symptoms had broadened to include diarrhea and flu.³ Diagnosis is made chiefly, based on a combination of history of exposure, symptoms and radiological and laboratory findings. Chest X-rays are helpful in establishing diagnosis; however, High Resolution Computed Tomography chest has been employed as a useful tool in observing the course of disease recovery and/or fibrosis in post-COVID patients.⁴ A raised CRP (C-Reactive Protein) and LDH (Lactate Dehydrogenase) along with a low lymphocyte count have been found to be associated with severe disease and predict poor prognosis.⁵

Though the death rate of the disease is still around 2%, the after-effects of Covid continue to alarm the world.⁶ Moving forward, more and more research is being conducted and proving that this is deadlier than the infectious diseases that normally prevail in the community, with an increased propensity of harming the old and the immunocompromised.

The burden on healthcare has been crippling for even the most developed of nations. The most worrisome part remains to be the fact that long after the virus leaves the person's body, its damaging effects persist. Those with pre-existing comorbidities are thought to be somewhat more susceptible than those who have a perfectly healthy immune system.⁷ The various stages of lung parenchymal involvement in post COVID-19 patients are documented in this study using HRCT chest, to better visualize lung damage in affected individual

after hospital discharge. There are limited studies which involve radiological follow up of COVID patients so this study will add to the existing body of knowledge by detecting post Covid changes in lung parenchyma these may help health care providers to detect those adverse changes timely and treat them effectively.

Methodology

This cross-sectional study was conducted in the Pulmonology Department of Sahiwal Teaching Hospital, Sahiwal, after approval from the institutional ethical review board through letter no 155/DME/SLMC/SWL dated 08-10-2020. The study was conducted from Nov 2020 to July 2021 in District Sahiwal, Punjab, Pakistan. A sample size of 151 was calculated through open epi website by taking confidence level as 95%, level of precision as 5% and prevalence of post covid HRCT changes in COVID patients as 89 %.⁸ In total 180 patients of both genders were included by non-probability consecutive sampling technique. Inclusion criteria was COVID PCR Positive patients admitted in hospital with follow up HRCT chest done 30 days after discharge. Patients with active COVID-19 virus, pregnant females and those with history of chronic interstitial lung disease and preexisting lung conditions like allergic alveolitis, tuberculosis or other infections were excluded from the study.

Whole body Multi Slice CT scan 128 Slices by GE discovery was used to get HRCT of chest and to visualize and document various patterns and stages of pulmonary fibrosis in the post-COVID patients. The changes on HRCT chest were evaluated and reported by three consultant radiologists, having experience of more than five years in reporting HRCT chest. The data was documented and analyzed using the IBM SPSS 28.0.0 2021. Various radiological findings were expressed in percentages.

Results

Out of 180 post-Covid patients, 108(60%) were males and 72(40%) females. The mean age of the participants was found to be 54.1 ± 14.525 years. A wide array of radiological findings was seen in the HRCT chest of 1-month post-COVID patients. These varied from slight ground glass haze or mild air space opacification to traction bronchiectasis and honeycombing. The frequency of these changes, as seen in the HRCT chest of patients has been tabulated below in Table 1.

RADIOLOGICAL FINDINGS	NO. OF CASES (Percentage)
Ground Glass Haze	140 (77.8)
Air Space Opacification	85 (47.2)
Fibrotic Bands	47 (26.1)
Septal Thickening	36 (20.0)
Mediastinal Lymphadenopathy	23 (12.8)
Consolidation	22 (12.2)
Traction Bronchiectasis	18 (10.0)
Honeycombing	14 (7.8)

140 out of 180 patients (77.8%) had bilateral lung involvement, while 40 (22.2%) had unilateral lung involvement after one month of the disease.

Right Lower Lobe was found to be the most commonly involved, with involvement in 165 (91.7%) cases. Right Middle Lobe was the least

commonly involved, with changes shown in only 120 (66.7%) out of 180 cases. Different patterns of distribution were also observed, with patchy distribution being the most common (85.3%). The different patterns of distribution, along with the frequency of involvement of various lung lobes are shown in table 2.

Pattern	Distribution	No. of cases (Percentage)
	Patchy	151(85.3%)
	Diffuse	15(8.5%)
	Sub-Pleural	75(42.4%)
	Peripheral	76(42.9%)
Lobes Involved	Right Upper Lobe	159(88.3%)
	Right Middle Lobe	120(66.7%)
	Right Lower Lobe	165(91.7%)
	Left Upper Lobe	137(76.1%)
	Left Lower Lobe	145(80.6%)

Radiological diagnosis of 166 (92.22%) patients was made to be Organizing Pneumonia while 14 (7.78%) patients were labelled as Usual Interstitial Pneumonia (UIP) with honey-combing depicted in their HRCT chest.

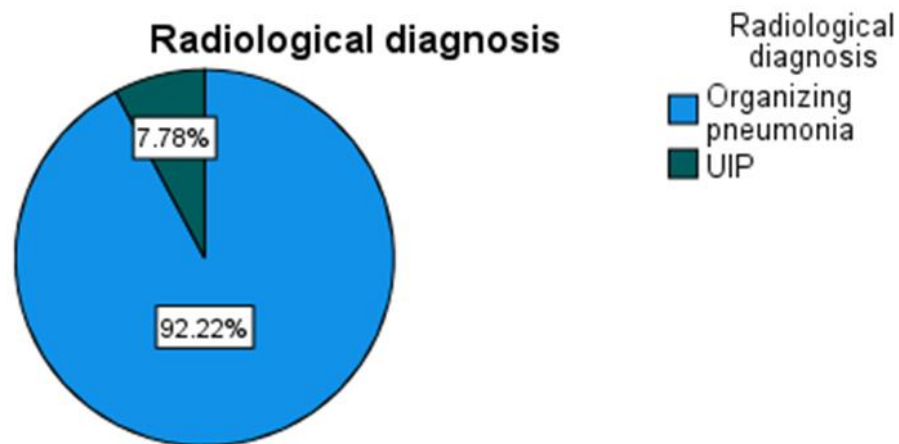


Figure 1: Radiological Diagnosis on the basis of HRCT Chest in Post-COVID patients.

Discussion

COVID-19 has trapped the world in a frenzy, where scientific knowledge is limited and our resources are being exhausted at an alarming rate. It is imperative to play our part in these trying times and gather enough reliable information for the betterment of humanity. This study is one of few conducted in Pakistani Patients. COVID-19 is posing enormous threat to our healthcare system because of the continued damage that might lead to lung fibrosis in the absence of timely intervention.^{9,10}

As shown by previous research data, males are at an increased risk of developing COVID and resultantly post-COVID interstitial lung disease (ILD)/fibrosis.¹¹ 60% of the cases were males while 40% were females, which is consistent with similar studies conducted worldwide.

Increased age has been shown to be a significant risk-factor via different studies.¹² The mean age of affected patients was 54.1 ± 14.52 years consistent with study reported by Shi in which mean age of infected individuals was reported to be 49 years.¹³

Role of repeat CT scan in follow up of Lung Disease has been well-established now and HRCT chest is far superior to the conventional CXR.^{14,15} HRCT chest was repeated at a one-month interval post-COVID. Individuals with known ILD such as Hypersensitivity Pneumonitis (HP) were excluded from this study to allow a clear deduction of results. Various histological changes were apparent in the HRCT

Chest. The most common finding was a Ground Glass Haze (seen in 77.8% of cases), which is consistent with the findings of previously conducted similar studies.¹⁶

Few other studies revealed similar results with ground glass opacities being the commonest finding.^{17,18} A spectrum of radiological changes was reported, from Air Space Opacification (47.2%) to Septal Thickening (20%) and Fibrotic Bands (26.1%). Traction Bronchiectasis (10%) and Honey Combing (7.8%) were relatively rare and can be considered to be more late/severe changes on the path to Lung Fibrosis. The criteria used for various radiological findings such as Ground Glass Haze and Air Space Opacification was according to Fleischner society glossary of terms for thoracic imaging.¹⁹

Bilateral Lower Lobe involvement was seen most commonly, while the Right Middle Lobe remained relatively spared. There is a lot of room for further key variables to be explored in future studies. There might be a correlation in the lobes being involved and gender, occupation or smoking status of an individual.

We can save the crippling healthcare infrastructure by adequately treating and dealing with all the complications associated with this deadly pandemic. HRCT Chest can be used as a very helpful radiological tool for close follow-up of improvement or deterioration in a post-COVID patient. The goal is to predict, investigate and then intervene timely to

reduce morbidity and mortality. Furthermore, the small number of patients recruited at a single facility limit any definitive conclusions, although they do indicate the necessity for a more thorough follow-up of COVID-19 patients.

Conclusion

- Patchy ground glass haze seen bilaterally in Lower Lung Lobes are the commonest radiological abnormalities in HRCT chest of post-COVID patients.
- Timely identification of post-COVID interstitial lung disease can help in prompt interventions in the form of drugs like corticosteroids to save a patient from complications like lung fibrosis.

References

1. Covid19.who.int. 2022. *WHO Coronavirus (COVID-19) Dashboard*. [online] Available at: <<https://covid19.who.int/>> [Accessed 4 June 2022].
2. Hassan SA, Sheikh FN, Jamal S, Ezeh JK, Akhtar A. Coronavirus (COVID-19): a review of clinical features, diagnosis, and treatment. *Cureus*. 2020 Mar;12(3). doi:10.7759/cureus.7355
3. Herlihy R, Bamberg W, Burakoff A, Alden N, Severson R, Bush E, et al. Rapid Increase in Circulation of the SARS-CoV-2 B. 1.617. 2 (Delta) Variant—Mesa County, Colorado, April–June 2021. *Morbidity and Mortality Weekly Report*. 2021 Aug 13;70(32):1084. DOI: <http://dx.doi.org/10.15585/mmwr.mm7032e2> [external icon](#)
4. Kanne JP. Chest CT Findings in 2019 Novel Coronavirus (2019-nCoV) Infections from Wuhan, China: Key Points for the Radiologist. *Radiology*. 2020 Apr;295(1):16-17 DOI: [10.1148/radiol.2020200241](https://doi.org/10.1148/radiol.2020200241)
5. Zhang ZL, Hou YL, Li DT, Li FZ. Laboratory findings of COVID-19: a systematic review and meta-analysis. *Scand. J. clin. Lab. Invest.* 2020 Oct 1;80(6):441-7. DOI: [10.1080/00365513.2020.1768587](https://doi.org/10.1080/00365513.2020.1768587)
6. Covid.gov.pk. 2022. COVID-19 Health Advisory Platform by Ministry of National Health Services Regulations and Coordination. [online] Available at: <<https://covid.gov.pk/stats/pakistan>> [Accessed 3 June 2022].
7. Beckman MF, Mougeot FB, Mougeot JL. Comorbidities and Susceptibility to COVID-19: A Generalized Gene Set Data Mining Approach. *Journal of clinical medicine*. 2021 Jan;10(8):1666. doi:10.3390/jcm10081666
8. van Gassel RJ, Bels JL, Raafs A, van Bussel BC, van de Poll MC, Simons SO, et al. High prevalence of pulmonary sequelae at 3 months after hospital discharge in mechanically ventilated survivors of COVID-19. *Am. J. Respir. Crit. Care Med*. 2021 Feb 1;203(3):371-4.
9. Liu D, Zhang W, Pan F, Li L, Yang L, Zheng D, et al. The pulmonary sequelae in discharged patients with COVID-19: a short-term observational study. *Respir Res*. 2020 May 24;21(1):125. doi: 10.1186/s12931-020-01385-1.
10. Rai DK, Sharma P, Kumar R. Post covid 19 pulmonary fibrosis. Is it real threat? *Indian J Tuberc*. 2021 Jul;68(3):330-333. doi:10.1016/j.ijtb.2020.11.003
11. Bienvenu LA, Noonan J, Wang X, Peter K. Higher mortality of COVID-19 in males: sex differences in immune response and cardiovascular comorbidities. *Cardiovascular Research*. 2020 Dec 1;116(14):2197-2206. doi:10.1093/cvr/cvaa284
12. Ho FK, Petermann-Rocha F, Gray SR, Jani BD, Katikireddi SV, Niedzwiedz CL, et al. Is older age associated with COVID-19 mortality in the absence of other risk factors? General population cohort study of 470,034 participants. *PLoS One*. 2020 Nov 5;15(11):e0241824. DOI: [10.1371/journal.pone.0241824](https://doi.org/10.1371/journal.pone.0241824)
13. Shi H, Han X, Jiang N, Cao Y, Alwalid O, Gu J, et al. Radiological findings from 81 patients with COVID-19 pneumonia in Wuhan, China: a descriptive study. *The Lancet infect. dis*. 2020 Apr 1;20(4):425-34. DOI: [10.1016/S1473-3099\(20\)30086-4](https://doi.org/10.1016/S1473-3099(20)30086-4)
14. Mahdavi A, Haseli S, Mahdavi A, Bakhshayeshkaram M, Foroumandi M, Nekooghadam SM, et al. The role of repeat chest CT scan in the COVID-19 pandemic. *Academic radiology*. 2020 Jul;27(7):1049. doi:10.1016/j.acra.2020.04.031
15. Pal A, Yadav MK, Pant C, Shrestha BK. High resolution computed tomography and chest radiography findings among interstitial lung disease patients. *J Chitwan Med Coll*. 2019 Dec 27;9(4):24-7. DOI:[10.3126/jcmc.v9i4.26895](https://doi.org/10.3126/jcmc.v9i4.26895)
16. Salehi S, Abedi A, Balakrishnan S, Gholamrezanezhad A. Coronavirus disease 2019 (COVID-19): a systematic review of imaging findings in 919 patients. *Am J Roentgenol* 2020 Jul;215(1):87-93. DOI: [10.2214/AJR.20.23034](https://doi.org/10.2214/AJR.20.23034)
17. Wang Y, Dong C, Hu Y, Li C, Ren Q, Zhang X, et al. Temporal changes of CT findings in 90 patients with COVID-19 pneumonia: a longitudinal study.

- Radiology. 2020 Aug;296(2):E55-64.
DOI: [10.1148/radiol.2020200843](https://doi.org/10.1148/radiol.2020200843)
- 18 Aylan AM, Ahyad RA, Jamjoom LG, Alharthy A, Madani TA. Middle East respiratory syndrome coronavirus (MERS-CoV) infection: chest CT findings. Am J Roentgenol. 2014 Oct;203(4):782-7.
DOI: [10.2214/AJR.14.13021](https://doi.org/10.2214/AJR.14.13021)
19. Hansell DM, Bankier AA, MacMahon H, McLoud TC, Muller NL, Remy J. Fleischner Society: glossary of terms for thoracic imaging. Radiology. 2008 Mar;246(3):697-722
DOI: [10.1148/radiol.2462070712](https://doi.org/10.1148/radiol.2462070712)