

Testicular Germ Cell Tumor with a Rare Combination of Seminomatous and Nonseminomatous Components

Ayesha Ali ¹, Noor Khan Lakhnana ², Mudassira Zahid ³

^{1,3} Assistant Professor, Department of Pathology

² Professor and Head of Dept, Department of Pathology
(Al Nafees Medical College & Hospital, Islamabad)

ABSTRACT

Testicular neoplasms constitute 1% of all tumors in men. With new therapeutic regimens, the cure rate in testicular germ cell tumors is more than 90%. Accurate histologic typing of the neoplasm plays a pivotal role in planning treatment in each case. Most testicular germ cell tumors (GCT) are of mixed type. Various combinations can be present but the occurrence of seminomatous component in mixed germ cell tumor is unusual. We report a case of a 26 years old man who presented with painless enlargement of testis. Histological examination revealed a mixed GCT of seminoma with syncytiotrophoblast cells, immature teratoma and embryonal carcinoma.

Key Words: Germ cell tumor, Embryonal carcinoma, Seminoma, Teratoma.

Address of Correspondence

Dr. Ayesha Ali

Email: ayeshaali1019@gmail.com

Case Report info.

Received: March 19, 2017

Accepted: May 13, 2017

Cite this case report: Ali A, Lakhnana NK, Zahid M. Testicular Germ Cell Tumor with a Rare Combination of Seminomatous and Nonseminomatous Component. *JIMDC*. 2017; 6(2):116-118

Introduction

Testicular cancer is rather a rare neoplasm and it accounts for approximately 1% of all tumors in men.¹ Globally, an increasing trend has been noticed especially in United States and Northern Europe.² More than 90% tumors are classified as Germ cell tumors (GCT). Rather than a single pure histologic form, mixed germ cell tumors that contain more than one germ cell component are much more common and represents 32-60% of all germ cell tumors in the testis.³ Among the germ cell tumors, pure teratoma in the testis is rare (4% of GCTs in testis) compared to pure teratoma in 95% of GCTs found in the ovary.⁴ Pre-pubertal teratomas are usually mature and benign and constitute approximately 30% of testicular germ cell tumors in children. Post-pubertal (adult) testicular teratomas are malignant. Chance of metastasis in malignant testicular teratomas is about 20% as opposed to their ovarian counterparts.⁵ Various combinations of mixed germ cell tumors occur like Teratoma and Embryonal carcinoma (25%), Embryonal carcinoma and seminoma (15%), Teratoma, Embryonal carcinoma and seminoma with or without

syncytiotrophoblast like cells (15%).³ In more than half cases of malignant teratoma in adults, a mixed type tumor with yolk sac or embryonal carcinoma components is present. A combination of seminoma with a non seminomatous germ cell tumor is rare. Mixed germ cell tumors containing seminoma behave like nonseminomas.⁶ Although they are aggressive neoplasms, they are among the most curable cancers in humans. Management of testicular neoplasms depends upon type and stage of the tumor. Early and accurate diagnosis is essential for successful management of testicular tumors as a delay in diagnosis results in a higher stage at the presentation for treatment. In newly diagnosed cases, the cure rate is about 90%. Combination chemotherapy and surgery has markedly decreased the mortality in these lesions.⁷ Here, we present a rare case of a mixed germ cell tumor composed of both seminomatous and non seminomatous components (immature teratoma, embryonal carcinoma and seminoma with syncytiotrophoblast cells)

Case Report

A 26 years old boy presented with painless enlargement of right testis. Ultrasonography showed a complex mass, partly solid and partly cystic. There were multiple enlarged para aortic lymph nodes in the abdomen. Blood sample for serum marker was sent. Beta-HCG and LDH were found to be mildly elevated. The patient underwent right sided orchiectomy and specimen was sent for histopathology. It revealed an unusual combination of a mixed germ cell tumor which was, seminoma with syncytiotrophoblast cells, embryonal carcinoma and immature teratoma (figure 1, 2, 3). The three components were highlighted by using immunohistochemistry (CD117, CD30, and OCT3).

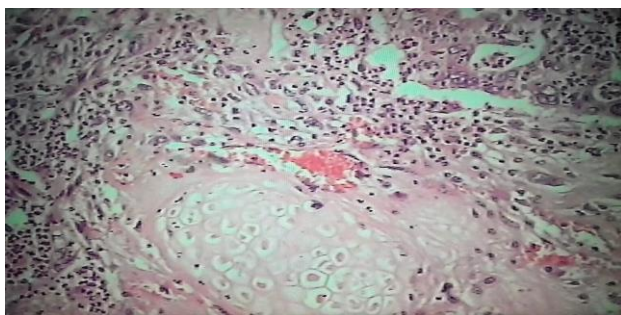


Figure 1. Immature teratoma in mixed GCT
(100x100)

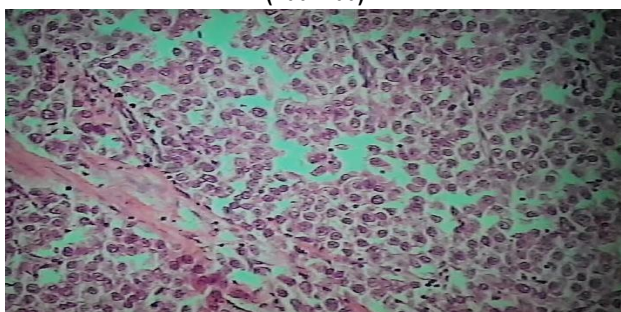


Figure 2. Seminoma in mixed GCT
(100x100)

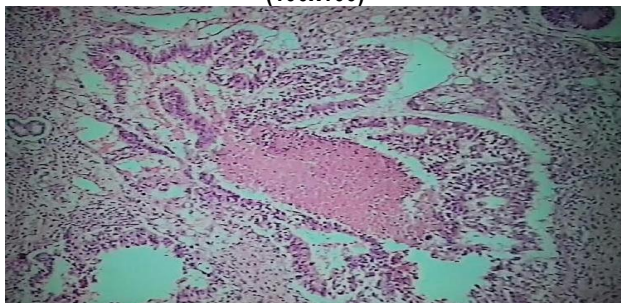


Figure 3. Embryonal carcinoma in mixed GCT
(40x100)

Discussion

Cancer of the testis constitutes 0.5% to 1.5% of all male cancers and approximately forty-nine thousand new cases are diagnosed each year. The risk factors for testicular tumors are not well established but hormonal and genetic factors appear to play a role along with other factors like effects of heat. A solid, firm mass within the testis must be considered a testicular cancer until proven otherwise.^{7, 8} Practically testicular germ cell tumors can be classified as seminomatous and non-seminomatous tumors, with seminoma accounting for 40% and the non-seminomatous tumors accounting for 60% of the cases. This distinction is a primary consideration in the patient management plan and helps the clinician in both prognosis and treatment.⁹ Among the non-seminomatous tumors, the largest group is comprised of embryonal carcinoma, yolk sac tumor, choriocarcinoma and teratoma. Pre-pubertal testicular teratoma can be benign (dermoid cyst) but post pubertal teratomas, no matter how mature they look, are deemed malignant as they frequently metastasize. The presence of somatic type malignancy is also a poor prognostic feature.¹⁰ More than half of the germ cell tumors consist of more than one cell type, which calls for thorough sampling for the correct diagnosis and also correlation with the serum tumor markers (human chorionic gonadotropin [hCG] and α -fetoprotein).¹¹

Mostofi classified more than 6000 testicular tumors and found more than one histological patterns in approximately 60% of the cases. He found that the most frequent combination was embryonal carcinoma, yolk sac tumor and choriocarcinoma.¹² Mosharafa et al statistically analyzed various germ cell tumor combinations and found 10 possible pair combinations with the strongest correlation between teratoma and yolk sac tumor.¹³ According to Carver et al, teratoma in adults frequently presents as a mixed germ cell tumor, with yolk sac or embryonal cell tumor component in 50% of cases.¹⁴ In his study on testicular tumors Mutahir et al found that commonest histologic pattern was mixed (embryonal cell carcinoma+yolk sac tumor+teratoma) germ cell tumor in 45% cases.⁷ Prahdan reported that, most testicular mixed germ cell tumors consist of yolk sac tumors with embryonal carcinoma, choriocarcinoma and

mature teratoma, but combinations of seminoma with immature teratoma are rare.¹⁵ About 5% of seminomas are associated with syncytiotrophoblast like cells which are widely dispersed as compared to those in choriocarcinoma.¹⁶

The etiology of Germ cell tumors is largely unknown. Cytogenetically germ cell tumors exhibit a gain of chromosome 12p as isochromosome (i12p). There are a few exceptions in the GCT family, most of which have an indolent behavior, that do not share this common genetic makeup. This includes spermatocytic seminoma, dermoid cyst, and epidermoid cyst in post-pubertal individuals, as well as pediatric GCT (yolk sac tumor and teratoma).¹⁷

To guide the surgeon in selecting the best treatment plan for individual patients, a pathologist must incorporate the following information in the pathology report of a testicular germ cell tumor: (1) gross features of the tumor such as size, necrosis, or hemorrhage (2) local extension of the tumor, including involvement of the spermatic cord or scrotum, and the status of spermatic cord resection margin (3) histologic tumor classification group i.e. seminoma or non-seminoma (mention if pure or mixed form) (4) for mixed GCT, the names of all histologic components with the approximate percentage of each component (5) vascular or lymphatic invasion and (6) presence of Intratubular germ cell neoplasia (IGCN) in the uninvolved testicular tissue.^{18,19}

Conclusion

Seminoma as part of germ cell tumor is rare. A thorough sampling with high degree of suspicion to look for non seminomatous component in testicular germ cell tumor must always be kept in mind.

References

1. Ferlay J, Steliarova-Foucher E, Lortet-Tieulent J, Rosso S, Coebergh JW, Comber H, Forman D, Bray F. Cancer incidence and mortality patterns in Europe: estimates for 40 countries in 2012. *European journal of cancer*. 2013; 49(6):1374-403.
2. Ghazarian AA, Trabert B, Devesa SS, McGlynn KA. Recent trends in the incidence of testicular germ cell tumors in the United States. *Andrology*. 2015; 3(1):13-8.
3. Stamatiou K, Papadopoulos P, Perlepes G, Galariotis N, Olympitis M, Moschouris H, Vasilakaki T. Mixed germ cell

- tumor of the testicle with raviduomusarcomatous component: a case report. *Cases journal*. 2009; 2(1):9299.
4. Wetherell D, Weerakoon M, Williams D, Beharry BK, Sliwinski A, Ow D, Manya K, Bolton DM, Lawrentschuk N. Mature and immature teratoma: A review of pathological characteristics and treatment options. *Med Surg Urol*. 2014; 3(124):2.
5. Bhatti AB, Ahmed I, Ghauri RK, Saeed Q, Mir K. Clinical profile, treatment and survival outcome of testicular tumors: a Pakistani perspective. *Asian Pac J Cancer Prev*. 2014; 15(1):277-80.
6. Islam R, Boksh Z, Rahman S, Pasha K. A Rare Combination of Mixed Germ Cell Tumour of Testis-A Case Report. *Anwer Khan Modern Medical College Journal*. 2015; 6(1):50-4.
7. Tunio MA, Hashmi A, Naimatullah N, Mohsin R, Maqbool SA, Rafi M. Fifteen Years of Experience in the Management of Non-Seminomatous Testicular Germ Cell Tumors at a Tertiary Care Center in Pakistan. *Pak J Med Sci*. 2011; 27(4):806-811.
8. Mushtaq S, Jamal S, Mamoon N, Akbar N, Khadim T. The pathological spectrum of malignant testicular tumours in northern Pakistan. *JPMA*. 2007; 57(499).
9. Ulbright TM. Germ cell tumors of the gonads: a selective review emphasizing problems in differential diagnosis, newly appreciated, and controversial issues. *Mod Pathol*. 2005; 18(2):61-79.
10. Jemal A, Siegel R, Ward E, Hao Y, Xu J, Thun MJ. Cancer statistics. *CA: a cancer journal for clinicians*. 2009; 59(4):225-49.
11. Sesterhenn IA, Davis Jr CJ. Pathology of germ cell tumors of the testis. *Cancer Control*. 2004; 11(6):374-87.
12. Mostofi FK, Sesterhenn IA. Pathology of germ cell tumors of testes. *Progress in clinical and biological research*. 1985; 203:1-34.
13. Mosharafa AA, Foster RS, Leibovich BC, Ulbright TM, Bihler R, Einhorn LH, Donohue JP. Histology in mixed germ cell tumors. Is there a favorite pairing? *The Journal of urology*. 2004; 171(4):1471-3.
14. Carver BS, Serio AM, Bajorin D, Motzer RJ, Stasi J, Bosl GJ, Vickers AJ, Sheinfeld J. Improved clinical outcome in recent years for men with metastatic nonseminomatous germ cell tumors. *Journal of Clinical Oncology*. 2007; 25(35):5603-8.
15. Pagaro PM, Gore CR, Patil T, Chandanwale S. Mixed germ cell tumors: Report of two cases. *Medical Journal of Dr. DY Patil University*. 2013; 6(3):298-301.
16. Aneja A, Bhattacharyya S, Mydlo J, Inniss S. Testicular seminomatous mixed germ cell tumor with choriocarcinoma and teratoma with secondary somatic malignancy: a case report. *Journal of medical case reports*. 2014 Jan 1; 8(1):1.
17. Sheikine Y, Genega E, Melamed J, Lee P, Reuter VE, Ye H. Molecular genetics of testicular germ cell tumors. *American journal of cancer research*. 2012; 2(2):153-167.
18. Bahrami A, Ro JY, Ayala AG. An overview of testicular germ cell tumors. *Archives of pathology & laboratory medicine*. 2007; 131(8):1267-80.
19. Leman ES, Gonzalgo ML. Prognostic features and markers for testicular cancer management. *Indian journal of urology: IJU: journal of the Urological Society of India*. 2010; 26(1):76.