

# Functional Outcome of Distal Femur Fracture Treated with Retrograde Nailing Technique

Muhammad Azfar Khanzada<sup>1</sup>, Muhammad Tahir Lakho<sup>2</sup>, Zulfiqar Ali Memon<sup>3</sup>, Syed Alam Zeb<sup>4</sup>, Bashir Ahmed<sup>5</sup>, Rajesh Kumar<sup>6</sup>

<sup>1,4</sup>Specialist, Department of Orthopedic Surgery, AlHabib Hospital, Riyadh, Kingdom of Saudi Arabia

<sup>2</sup>Assistant Professor, Department of Orthopedic Surgery, Dr. Ruth K. M. Pfau, Civil Hospital, Karachi

<sup>3</sup>Senior Registrar, Department of Orthopedic Surgery, Liaquat University of Medical and Health Sciences, Jamshoro

<sup>5</sup>Surgeon, Department of Orthopedic Surgery, Jinnah Postgraduate Medical Center, Karachi

<sup>6</sup>Medical Officer, Dr. Ruth K. M. Pfau, Civil Hospital, Karachi

## ABSTRACT

**Background:** Management of distal femur fractures is always challenging for the surgeons. Retrograde interlocking nailing is one of the effective methods with minimal complications for treatment of such fractures. The objective of the study was to evaluate the functional outcome of retrograde interlocking nailing technique in patients with distal femur fractures.

**Methodology:** This interventional study was conducted at the department of orthopedic surgery, Liaquat University Hospital, Hyderabad from March 2017 to December 2019. Patients of either gender, between 30 to 65 years age, who presented with acute fracture of distal femur, as a result of trauma within 12-96 hours, requiring surgical intervention were included. Lysholm Scoring System was used to evaluate the functional outcome of patients treated with retrograde interlocking nailing technique. Data was analyzed using SPSS version 24.

**Results:** Total 102 patients gave consent of participation. The mean age of study participants was  $43.50 \pm 7.26$  with the age range from 40-65 years. Male patients were 76.47% and female 23.53%. In majority (63.73%) of cases, mode of injury was road traffic accidents. Statistically significant difference in functional mobility score between the age groups and gender ( $p < 0.05$ ) was found. Statistically significant ( $p < 0.05$ ) decline in mean Lysholm score was observed in participants who had been bearing full weight for 3 months. Excellent functional outcome was achieved by 49.02% patients while 34.31% patients achieved good functional outcome.

**Conclusion:** Retrograde interlocking nailing for fracture of distal femur is an effective fixation surgical technique with minimal complications and excellent to good functional outcome.

**Key words:** Accidents, Femur Fractures, Fracture Fixation, Functional Performance

### Authors' Contribution:

<sup>1</sup>Conception; Literature research; manuscript design and drafting; <sup>2,3</sup>Critical analysis and manuscript review; <sup>4</sup>Data analysis; <sup>5,6</sup>Manuscript Editing.

### Correspondence:

Zulfiqar Ali Memon  
Email: memon.zulfi9326@gmail.com

### Article info:

Received: February 26, 2021  
Accepted: May 17, 2022

**Cite this article.** Khanzada MA, Lakho MT, Memon ZA, Zeb SA, Ahmed B, Kumar R. Functional Outcome of Distal Femur Fracture Treated with Retrograde Nailing Technique. *J Islamabad Med Dental Coll.* 2022; 11(2):82-88. DOI: <https://doi.org/10.35787/jimdc.v11i2.687>

**Funding Source:** Nil  
**Conflict of Interest:** Nil

## Introduction

Distal femur fractures (DFF) are the fractures that occur upto 15cm from the articular surface of distal femur. These are infrequently occurring fractures

that constitute around 4-6% of all femur fractures.<sup>1</sup> Globally, the DFF usually results from high energy trauma such as motor vehicle accidents, frequently seen in males between their 15 to 50 years of age. While DFF resulting from low energy trauma like simple fall commonly occurs in females more than 50 years of age. Moreover, patients suffering from osteoporosis and/or having previous knee arthroplasties are at higher risk of these fractures.<sup>2,3</sup> Globally, in elderly people, DFF are the second most common cause of mortality after hip fractures.<sup>3</sup> Fractures of distal femur are usually treated by using different surgical techniques like; internal fixation by 95 degree angle blade plate, cancellous screws, dynamic condylar screw and plate, condylar buttress plates, distal femoral locking plate and retrograde intramedullary nail.<sup>3,4</sup>

While conservative methods include traction and plaster immobilization of joint, the ultimate goal of restoration of alignment is to preserve the function of extremity which is a crucial step in the definitive treatment of distal femur fracture.<sup>4</sup>

In addition to this, early knee range of motion (ROM) is the key to achieve acceptable outcomes. Whereas, loss of knee ROM and subsequent stiffness of the knee joint may result in immobilization and often contribute to poor outcome. Understanding the characteristics, principles and challenges in the management of DFF is important in optimizing their outcomes.<sup>5,6</sup>

Closed Intramedullary implants not only respect soft tissue envelope and periosteum but can achieve this goal without increasing the risk of infection and prolonged immobilization. Retrograde interlocking nail is associated with swift recovery, early union and lesser complications.<sup>6</sup> This implant is preferable to plate and screws because it is load sharing, minimum soft tissue dissection and periosteal stripping is done during its application, chances of union are more and patient is mobilized earlier.<sup>(5, 7)</sup> While some very minimal complications like knee pain, nonunion, and arthrofibrosis are also associated with this technique.

The current interventional study was designed to evaluate the functional outcome of retrograde interlocking nailing technique in patients with distal femur fracture presented in Liaquat University Hospital Hyderabad. The findings of the present study can help in formulating the standard guidelines for the effective and efficient surgical technique for DFF.

## Methodology

The interventional study was conducted at the orthopedic surgery unit of Liaquat University Hospital, Jamshoro, Hyderabad from March 2017 to December 2019. All the patients of either gender, between ages 40 to 65 years, who presented with acute fracture of distal femur close extra-articular and intra-articular fractures (diagnosed by radiograph) resulting from the trauma within 12–96 hours, requiring surgical intervention were included. While patients, presenting with gunshot injury, previous knee injury, fracture involving nerve, vascular and/or head injury, poly trauma of other bones of same side, previous interventional femoral surgery of same side, having evidence of infected wound or existence of purulent discharge on examination and with lost follow-up were excluded from the study.

The sample size of **102** was calculated by setting confidence interval at 95%, margin of error at 8% and taking 23% of anticipated proportion knee range pain using Open Epi. Online calculator.<sup>8,9</sup>

Non-random consecutive sampling technique was applied for selection of the participants. Ethical approval was sought from the Ethical Review Board of Liaquat University of Medical and Health Sciences, Jamshoro. An informed consent was taken from the patients after briefing them about the risks and benefits, as well as purpose of the study.

A predesigned written proforma was used to collect the detailed information of all the participants relating to the age, sex and occupation, mode of

injury, past and associated medical illness.<sup>10</sup> After collection of information, all the patients were assessed and treated for any life-threatening conditions. Detailed physical examination was done in all the patients to observe the condition of skin, any swelling or edema, vascular involvement etc. Upon arrival, patients were kept on skeletal pin traction or below knee skin traction application and limb put over Bohler-Braun cradle till the time of operation while in some cases, a skin traction or a long slab was applied. X-ray of the affected limb was taken in anterior-posterior and lateral views at the time of admission. Distal femur fracture was classified according to the Arbeitsgemeinschaft für Osteosynthesefragen (AO) classification system.<sup>11</sup> All surgeries were performed under general or spinal anesthesia on radiolucent traction table. Preoperative prophylactic antibiotic (second generation cephalosporin) was administered to all the patients at the time of induction. All surgeries were performed in a standard and uniform manner. Open reduction and internal fixation were done using standard lateral approach. Patients were kept in supine position, on radiolucent table with knee in slight flexion. The femoral condyle was exposed through a central 5 cm incision starting from lower pole of patella and just medial to the patellar tendon. The inter condylar notch was palpated and under image intensifier (anterior-posterior and lateral fluoroscopy) proper entry point was made and guide wire was passed while maintaining reduction and alignment. A proper length and maximum diameter of nail was inserted closely and locked at both ends. The medullary canal was reamed and the nail of appropriate size was reinserted.

To encourage the early range of motion of knee, physiotherapy was initiated on the first post-operative day. Patients were called for follow up at 2nd, 4th and 6th week initially and then monthly for one year. In each visit, patients were clinically assessed for knee range of motion, measured by goniometer and ability to tolerate weight. X-rays

were done to evaluate the bony union. The functional outcome was assessed on the 36<sup>th</sup> week post-operatively with radiological healing through X ray AP/Lateral view and Lysholm Gillquist Scoring System (LGSS). The Lysholm knee scoring system comprise of eight components to measure: Pain, instability, limp, swelling, locking, squatting, support and stair climbing. For each question response, an arbitrary score has been assigned. The random LGSS has a maximum score of 100. The scores >90 is graded as excellent, while 84-90 considered as good, it is categorized as fair, if score is 65-83 and poor if the score is <65.<sup>12</sup>

Data was entered and analyzed using SPSS ver. 24. The relationship between age of all participants ( $\leq 45$  and over 45 years), gender, the duration of immobilization (up to 6 and  $\geq 6$  weeks), time to start full weight-bearing ( $\leq 3$  months and over 3 months) were also analyzed.<sup>13</sup> Qualitative variables are presented as frequency and percentages while quantitative variables demonstrated as means and standard deviation. Student's t-test was applied for the statistical analysis of qualitative variables. Significance level was kept at p-value < 0.05.

## Results

Total 102 patients participated in the study. The mean age of study participants was  $43.50 \pm 7.26$  with the age range from 30-65 years. Male patients were 78(76.47%) and female 24(23.53%). According to stratified groups, 43(42.15%) patients were aged  $\leq 45$  years and 59(57.84%) patients were aged >45 years. Mean age of patients aged  $\leq 45$  years was  $37.83 \pm 3.07$  years and for patients aged >45 years the mean age was  $53.42 \pm 3.14$  years.

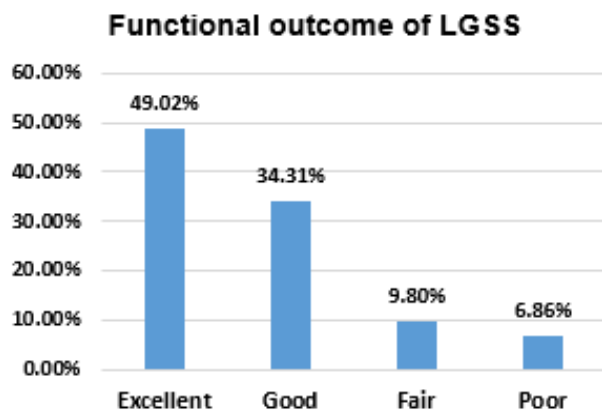
Most of participants had right side of knee involved (61.76%) compared with left side (38.23%). In majority of cases, mode of injury was road traffic accidents (RTA) (63.73%) while second highest number of patients sustained fractures due to fall on ground. (36.27%)

On radiological examination, majority 36(35.30%) of patients had type **A1**, 26(25.50%) **A2**, 21(20.58%), **A3** and 19(18.62%) patients had **C1** type of femur fracture on AO classification. Total 48 (47.07%) patients underwent surgery within three days of admission while 39 (38.23%) patients underwent surgery in 3-7 days after initial stabilization and 15 (14.70%) underwent surgery after 7 days of admission after extensive treatment for controlling infection.

After completion of one year, out of total patients,  $\geq 110^\circ$  flexion was achieved by 75 (73.53%) patients,  $91^\circ$ - $109^\circ$  flexion achieved by 16(15.68%) patients and  $\leq 90^\circ$  of knee flexion was achieved by 11 (10.78%) patients. The knee flexion was assessed for all the patients and the mean flexion at knee on different duration is mentioned in Table I.

Monthly Follow-ups	Mean degree of flexion
First	42.10° ± 5.26°
Third	89.62° ± 10.81°
Sixth	111.87° ± 9.21°
Twelfth	120.50° ± 11.87°

The findings of Functional outcome for all the patients is shown in the figure below. Majority of patients showed excellent functional outcome on LGSS. (Figure 1)

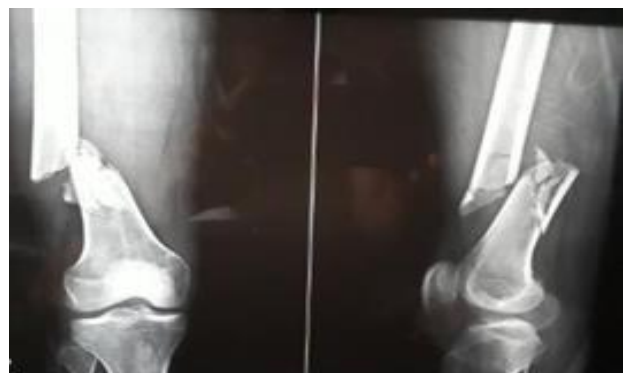

**Figure 1: Functional outcome on Lysholm Gillquist Scoring System (LGSS)**

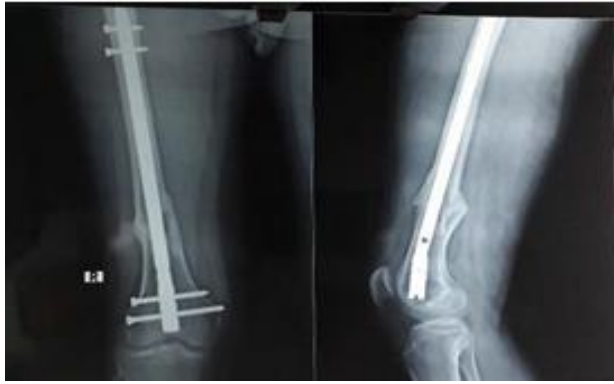Table II below is demonstrating the relationship between the age, gender, immobilization time and weight bearing time with functional scores of the patients. There was a statistically significant difference between the two age groups (< 45 and >45) and gender (P < 0.05), while no statistically significant difference between the affected side of the patients and functional outcomes.

		LYSHOLM KNEE SCORING	
		Mean± SD	P-value
Age	• ≤ 45 years	90.71±7.34	0.0001*
	• > 45 years	80.11±9.78	
Gender	• Male	91.24±6.45	0.0003*
	• Female	85.13±7.08	
Immobilization Time	• < 6 weeks	87.81±10.68	0.054
	• ≥ 6 weeks	81.32±13.22	
Weight-bearing Time	• ≤ 3 months	87.54±13.27	0.010*
	• > 3 months	79.48±13.54	

Radio-graphical presentation of fracture of distal femur at the time of admission and after application of retrograde femoral nail.



**1a-Pre-operative radiographic scan**



**1b- Post-operative retrograde femoral nailing**

## Discussion

The patterns and spectrum of distal femur fractures are so diverse that no single treatment option has proven consistently successful. The management of DFF using surgical techniques with the ultimate goal of restoration of alignment is preservation of the function of extremity, promotion of early motion of knee and restoration of articular surfaces.<sup>5</sup>

Moreover, preservation of soft-tissue envelope by durable fixation techniques allows the functional recovery throughout the bone healing.<sup>7,14</sup> The present study was designed with an objective of the evaluation of functional outcome of DFF using retrograde nailing technique. The male to female ratio in our study is 3:1 while more patients belong to age > 45 years. The demographic profile of the present study participants is almost identical to those reported in previous studies by Shah et al and Prasanna et al.<sup>14, 15</sup>

In this study, the retrograde nailing technique was being used. The advantages of closed intramedullary nailing act as a load sharing device range from providing the favorable intramedullary stability, early mobilization to lesser complications as compared to other treatment options. It is a closed treatment option without interrupting the fracture hematoma and leads to early callus formation.<sup>16</sup>

In order to preserve the soft-tissue envelope and for

achieving the closed indirect fracture reduction, the nail was inserted at a correct insertion point, so that it may leave the soft-tissue envelope intact. Moreover, the intramedullary fixation not only allows to achieve the multi-angle interlocking but also protects blood circulation around the fracture at the utmost extent.

In our study, significantly higher union rate of DFF with minimal complications was achieved. Atef et al. also endorsed these findings in his study and reported the 100% union rate of DFF in their study participants.<sup>12</sup> A study by Dileep et al. reported that retrograde nailing is the reliable technique for DFF with higher rate of union, with very limited complications that don't affect the movement of knee.<sup>17</sup> Two other local studies by Habib et al and Shafiq et al also reported excellent functional outcome, union rate and minimal complications using retrograde nailing technique in DFF in majority of their study participants.<sup>7,9</sup>

Most 60(61.9%) of the participants in our study had right side of knee involved compared with left side 37(38.1%). RTA was the most common mode of injury in this study as more than 60% patients suffered from RTA while 36.27% of patients sustained fractures due to fall on ground. Prasanna et al and Jillala et al also reported similar proportion of mode of injury in their study participants with RTA more predominant mode of injury.<sup>15, 18</sup>

Several rating scales are available and have been used to determine the functional outcomes after surgical treatment of fractures of femur yet none of the scale is validated to be superior to other. The most commonly used rating scales for functional outcome assessment include; Lysholm Gillquist Scoring System (LGSS), Neer's score, Schatzker and Lambert score, and Knee Society Score (KSS) etc. In our study, we used Lysholm Gillquist Scoring System for the assessment of functional outcome of patients with DFF undergoing retrograde intramedullary nailing technique.<sup>19</sup>

In the present study, excellent functional outcome was demonstrated in 49.02%, good in 34.21% and

fair in 9.80% patients with DFF type A1, A2, A3 and C1 according to the Lysholm Knee Scoring System. Poor functional outcome due to non-union and breakage of nail was demonstrated in 6.86% patients in our study. Moreover, Prasanna et al also reported consistent findings as over two-third of their patients had excellent to good functional outcome using same technique and scoring system.<sup>(15)</sup> Shah et al. also reported an excellent to good functional outcome in majority of their study participants after retrograde nailing for DFF using Schatzker and Lambert criteria.<sup>14</sup>

Few complications are observed in patients of the present study, the most common complication was anterior knee pain followed by superficial infection at the site of nail insertion and delayed union. Similar findings have been reported by Prasanna et al. While another study reported more serious complications including pulmonary embolism, knee stiffness and shortening of size of femur.<sup>15</sup>

This study evaluated the functional outcome of intramedullary retrograde nailing technique for DFF, comparative analysis of different surgical techniques may provide more detailed information regarding effectiveness of the surgical techniques.

## Conclusion

Intramedullary retrograde nailing for fracture of distal femur is reliable and effective fixation surgical technique. Excellent to good functional outcome with minimal complications and disruption to the soft tissues, as well as higher union rate and fast recovery is achieved in distal femur fracture patients.

## References

1. Rathi NB, Solanki RA, Patel HA, Tank PJ. Study of retrograde intramedullary nailing in distal one third shaft femur fracture. *Journal of Dental and Medical Sciences*. 2016;15(4):18-23.

2. Elsoe R, Ceccotti AA, Larsen P. Population-based epidemiology and incidence of distal femur fractures. *International orthopaedics*. 2018;42(1):191-6. doi: 10.1007/s00264-017-3665-1.
3. Meluzio M, Oliva M, Minutillo F, Ziranu A, Saccomanno M, Maccauro G. The use of knee mega-prosthesis for the management of distal femoral fractures: A systematic review. *Injury*. 2020;51:S17-S22. doi: 10.1016/j.injury.2019.08.011.
4. Metwaly RG, Zakaria ZM. Single-incision double-plating approach in the management of isolated, closed osteoporotic distal femoral fractures. *Geriatric orthopaedic surgery & rehabilitation*. 2018;9:2151459318799856.
5. Agrawal AK, Bansal A, Rawat S, Kapadiya S, Desai S, Golwala P. Surgical Management of Distal Femur Fracture Using Anatomical Locking Compression Plate. *Int J Cur Res Rev* | Vol. 2021;13(02):176.
6. Albareda-Albareda J, Gabarre-Raso S, Rosell-Pradas J, Puértolas-Broto S, Ibarz-Montaner E, Redondo-Trasobares B, et al. Biomechanical behavior of retrograde intramedullary nails in distal femoral fractures. *Injury*. 2021. 10.1016/j.injury.2021.01.052.
7. Habib MK, Niazi A. Outcome of Retrograde Interlocking Nail in Supracondylar Femur Fracture. *Journal of Pakistan Orthopaedic Association*. 2018;30(01):05-8.
8. Sullivan KM, Dean A, Soe MM. On academics: OpenEpi: a web-based epidemiologic and statistical calculator for public health. *Public health reports*. 2009;124(3):471-4.
9. Shafiq M, Ahmed A, Akram R, Javed S, Aziz A. RETROGRADE FEMUR NAIL:OUTCOME OF RETROGRADE FEMUR NAIL, IS IT IMPLANT OF CHOICE FOR DISTAL SHAFT OF FEMUR FRACTURE? *The Professional Medical Journal*. 2018;25(03):364-70. DOI:https://doi.org/10.29309/TPMJ/2018.25.03.370
10. Wang W, Liu L, Chang X, Jia Z, Zhao J, Xu W. Cross-cultural translation of the Lysholm knee score in Chinese and its validation in patients with anterior cruciate ligament injury. *BMC musculoskeletal disorders*. 2016;17(1):1-8. DOI: 10.1186/s12891-016-1283-5
11. El Mwafy HM, Abd El Gawad MM, El Din AFS, Youssef WM. Surgical treatment of distal femoral fractures using a distal femoral locked plate versus a condylar buttress plate. *Menoufia Medical Journal*. 2015;28(4):948. DOI: 10.4103/1110-2098.173681
12. Atef M, Hamoda AI. Management of distal femoral fractures: A comparative study between open reduction and internal fixation by distal femur locked plate and retrograde nailing. *Al-Azhar International Medical Journal*. 2020;1(4):144-8. DOI: 10.21608/AIMJ.2021.35593.1284

13. Ahmed B, Lakho MT, Khanzada MA, Memon ZA, Karim M, Bhatti A. Functional and radiological outcome of condylar buttress plate in patients with intra-articular distal femoral fracture. *Rawal Medical Journal*. 2021;46(1):98-101.
14. Shah SGM, Ahmed A, Shaikh SA, Ahmed N, Jamali AR. Outcome of Fracture Distal Femur Treated with Retrograde Nailing. *Journal of Pakistan Orthopaedic Association*. 2019;31(4):149-52.
15. Prasanna A, Jeyaraman M, Chaudhari K, Ajay S, Sabarish K. Prospective Study on Functional Outcome of Retrograde Femoral Nailing in Distal Third Femoral Fractures. *J Clin Exp Orthop*. 2019;5. DOI: 10.36648/2471-8416.5.2.65
16. Hoskins W, Sheehy R, Edwards E, Hau R, Bucknill A, Parsons N, et al. Nails or plates for fracture of the distal femur? Data from the Victoria Orthopaedic Trauma Outcomes Registry. *The bone & joint journal*. 2016;98(6):846-50. doi: 10.1302/0301-620X.98B6.36826.
17. Dileep K, Mahesha K. Retrograde intramedullary nailing for fractures of distal femur: A prospective study. *Int J Res Orthop*. 2016;2(4):276-9. DOI: <http://dx.doi.org/10.18203/issn.2455-4510.IntJResOrthop20164003>
18. Jillala SR, Ahmed SW, Shruthi A, Gajul R, Katikitala A, Rakesh K. A Comparative Study of Supracondylar Nail versus Locking Compression Plate in Distal Femur Fractures. *Annals of International Medical and Dental Research*. 2017;3(4):35-41.
19. Samuel AJ, Kanimozhi D. Outcome measures used in patient with knee osteoarthritis: with special importance on functional outcome measures. *International journal of health sciences*. 2019;13(1):52. PMID: PMC6392485  
PMID: 30842718