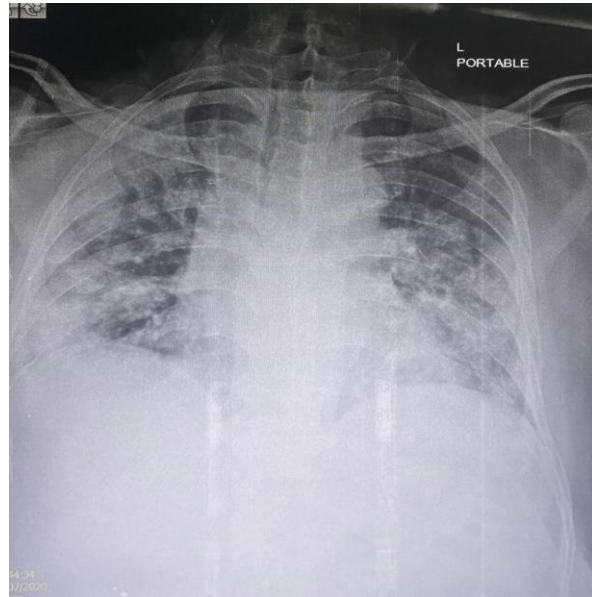
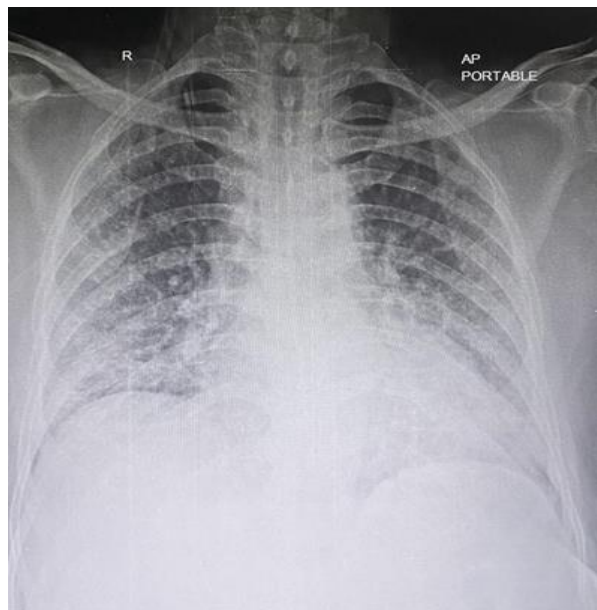
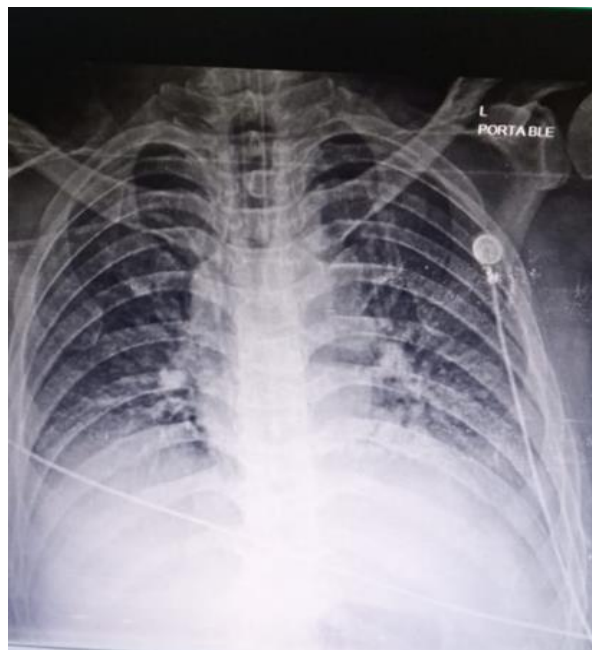
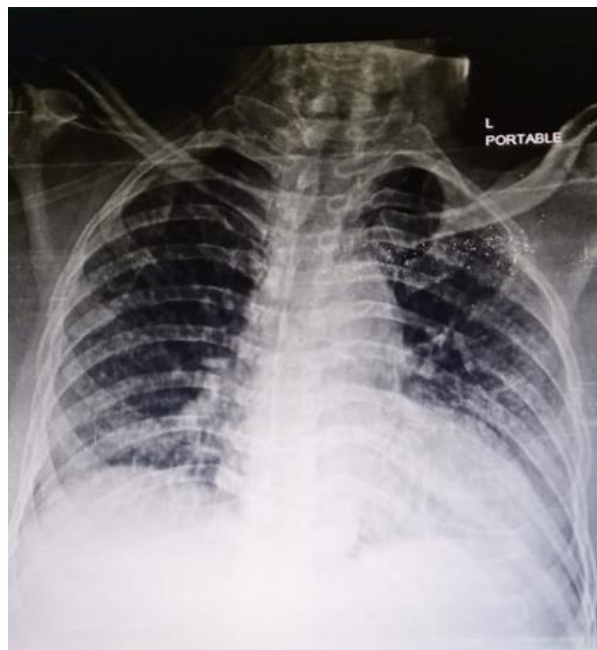
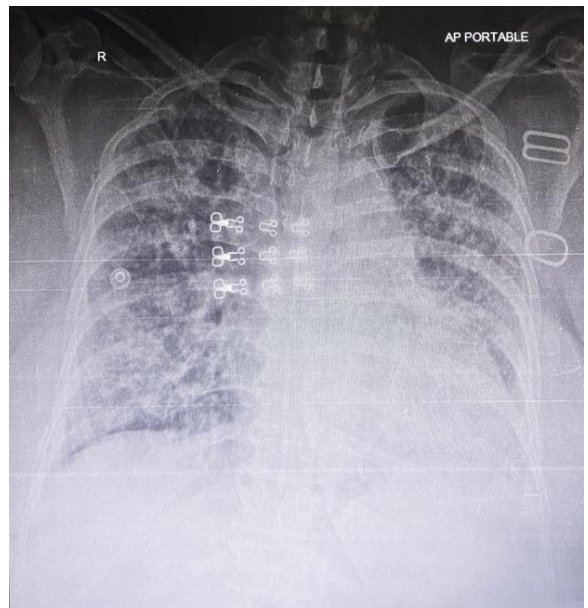
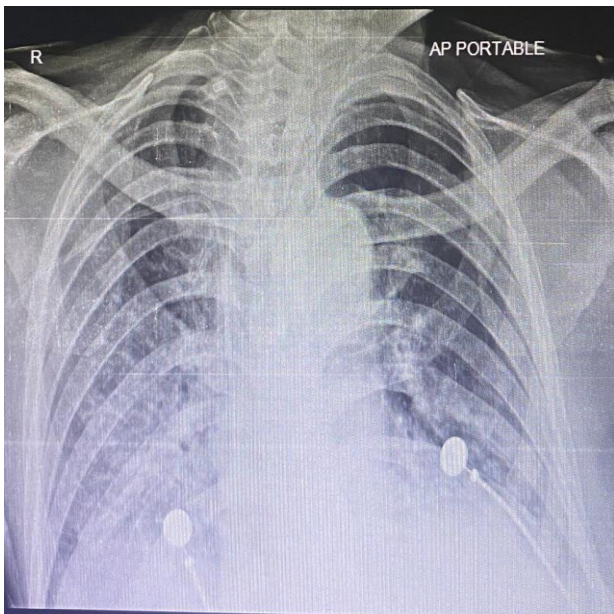
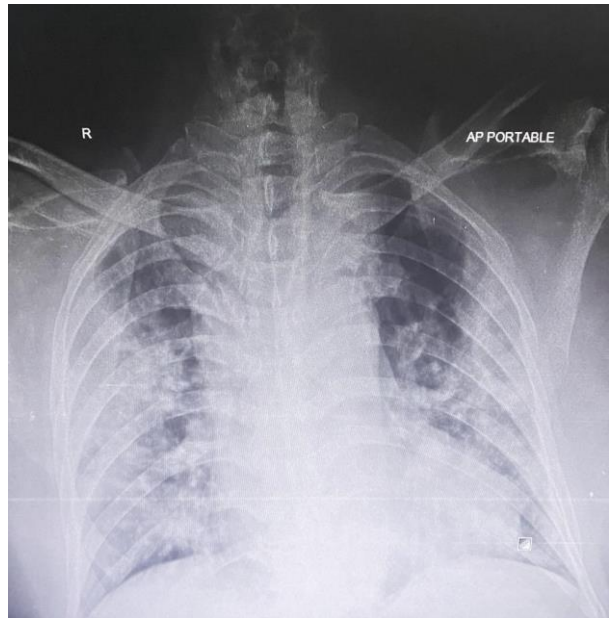
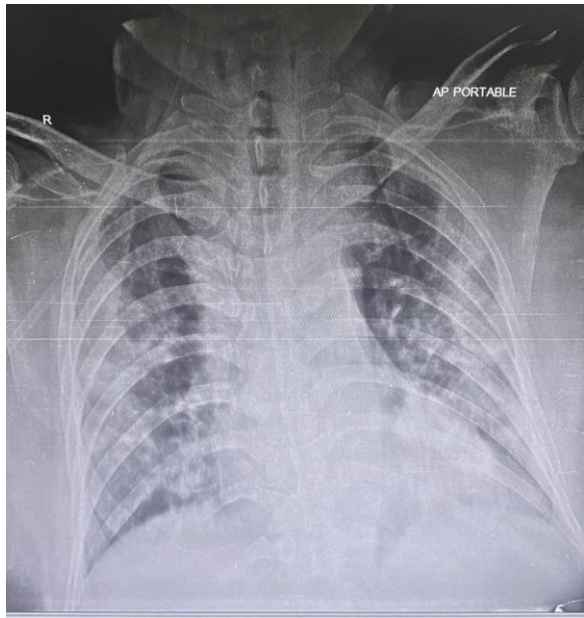


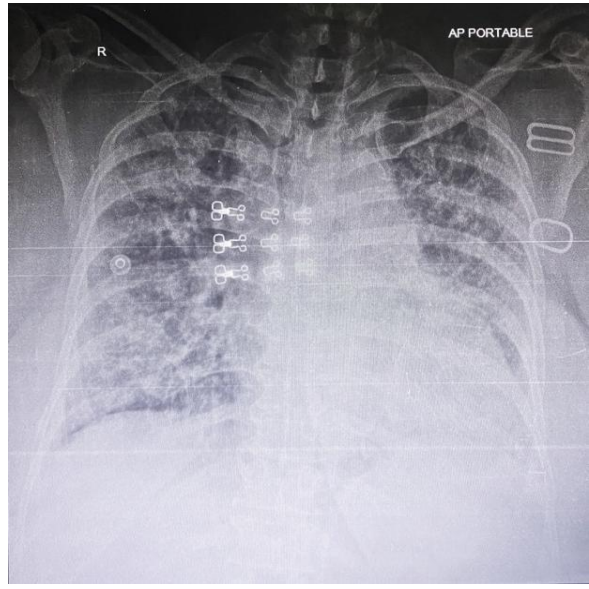
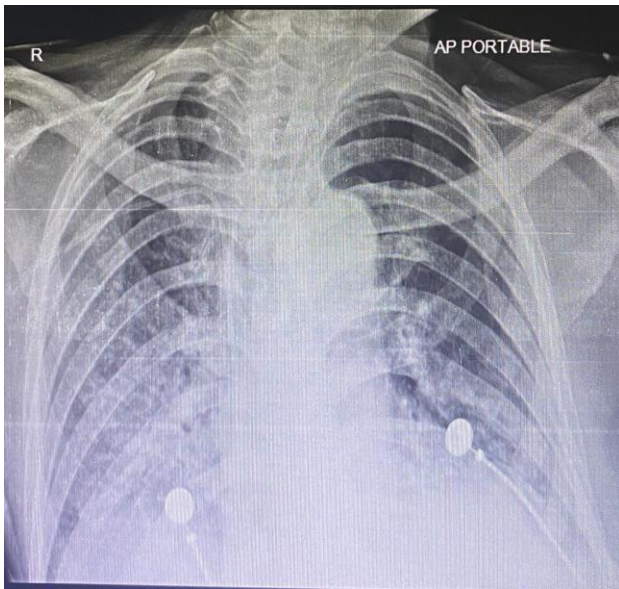
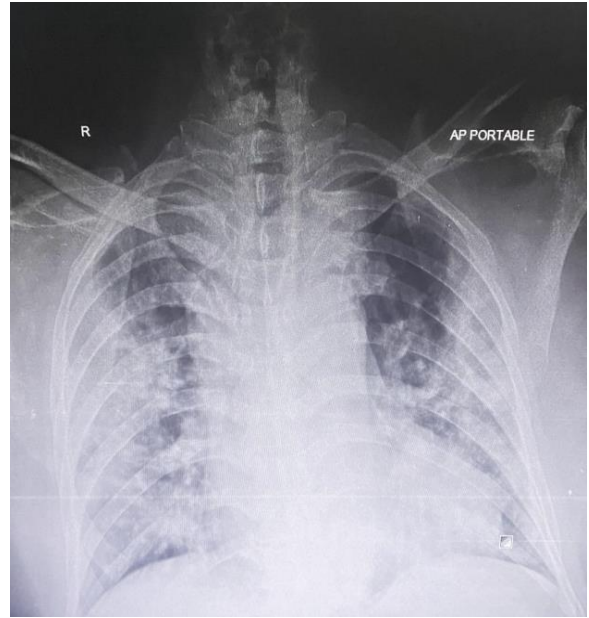
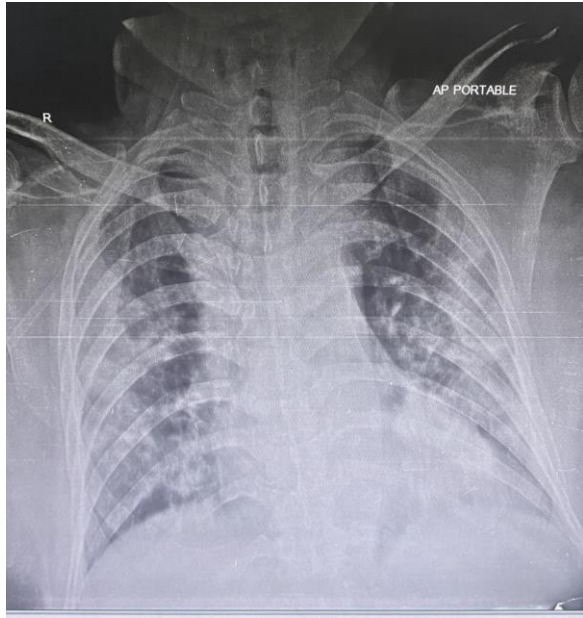
RADIOLOGICAL IMAGES

COVID-19 Pneumonia: Bilateral Peripheral Consolidations with Basal Predominance

Images from different patients with COVID-19 pneumonia showing characteristic X-ray findings of this disease







Contributed by:
Department of Radiology
Dr. Akbar Niazi Teaching Hospital, Islamabad