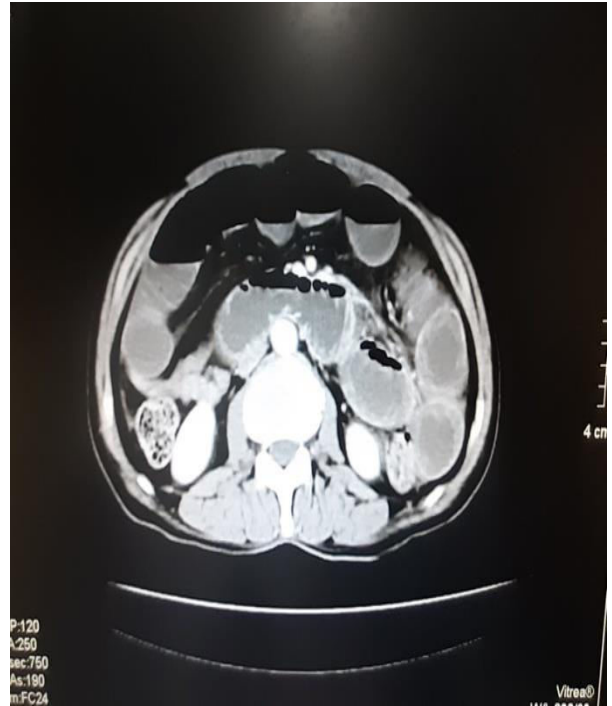
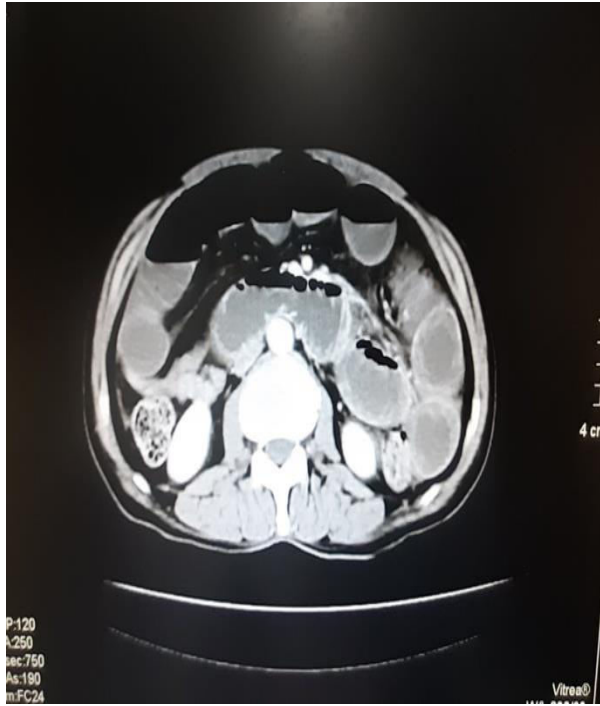
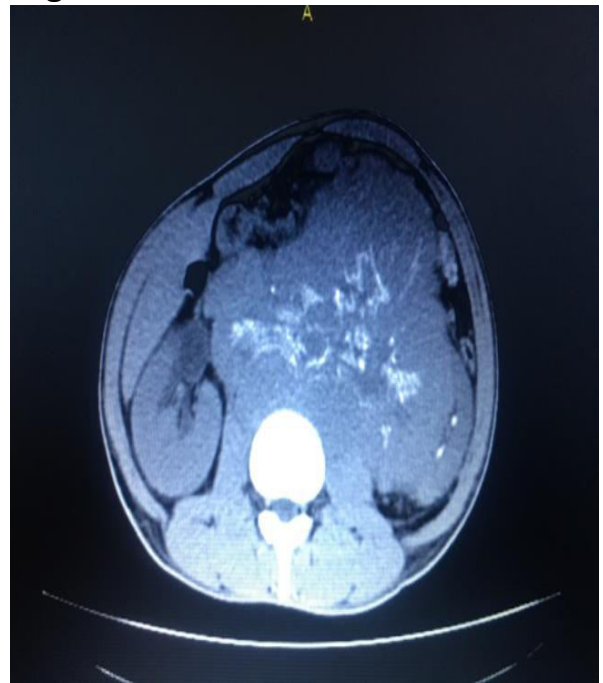
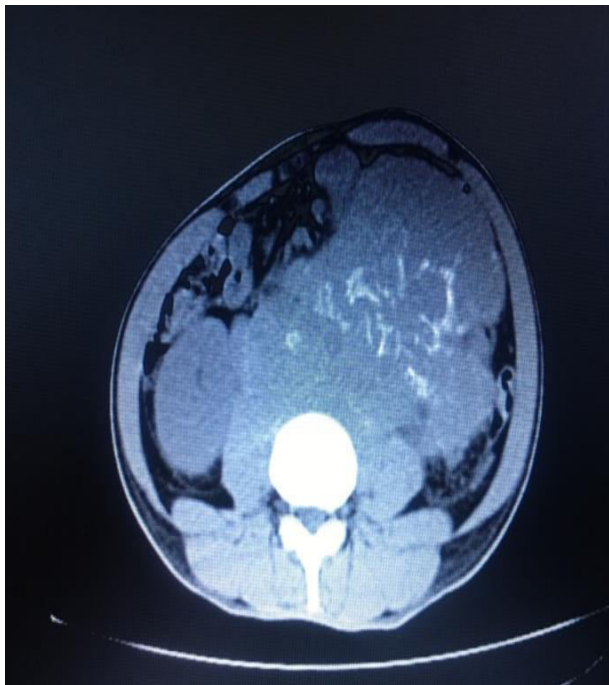


RADIOGRAPHIC IMAGES

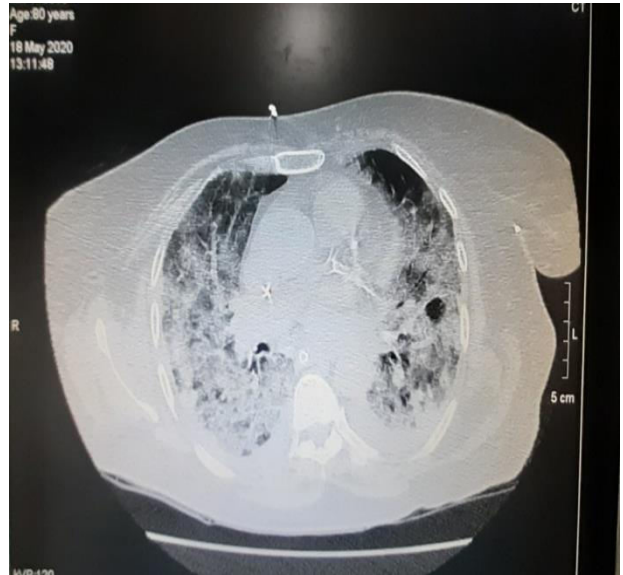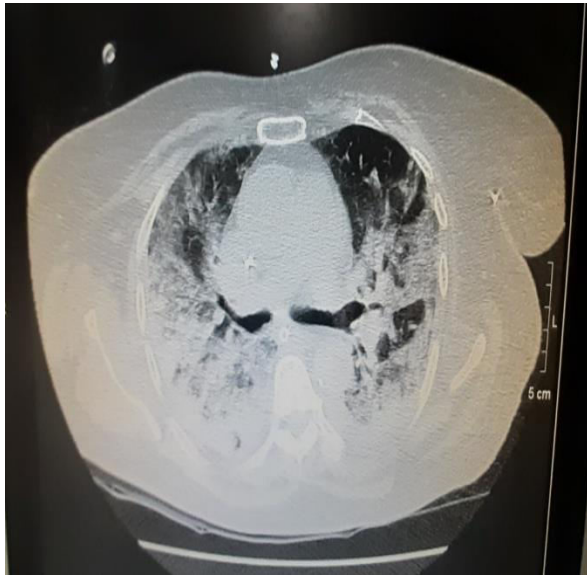Acute Intestinal Obstruction



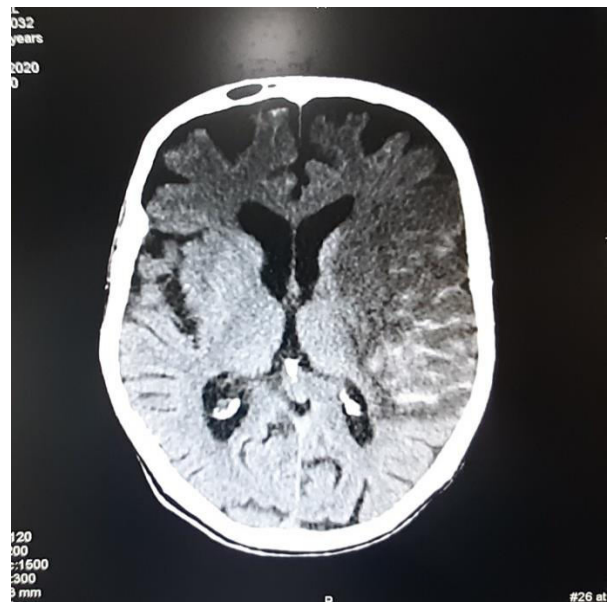
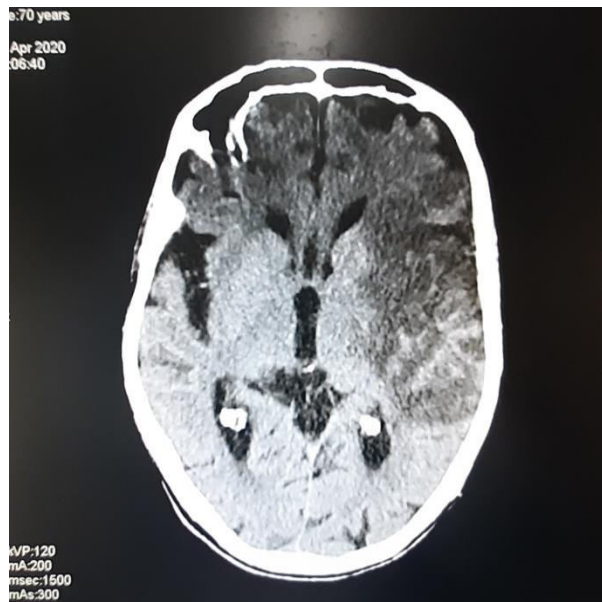
Retroperitoneal Neurogenic Tumor



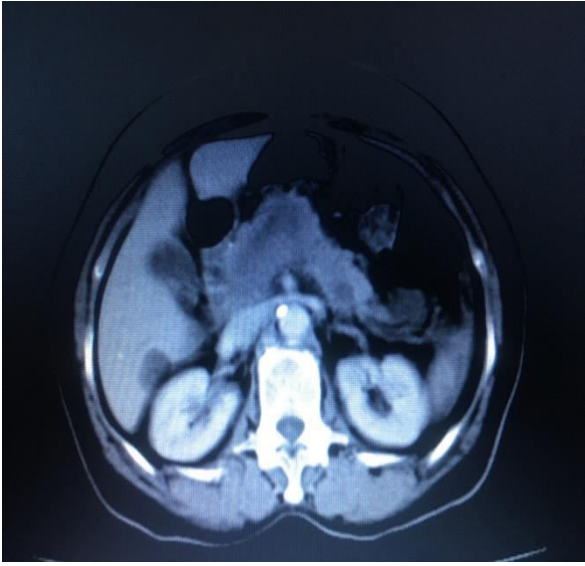
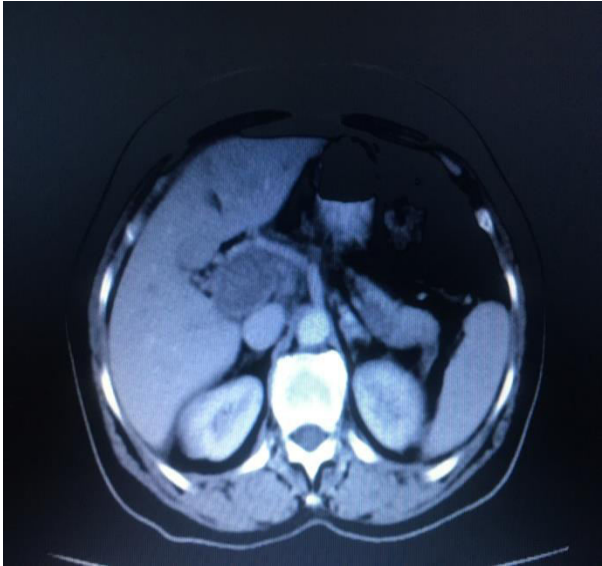
Extensive Bilateral Pneumonic Consolidations Leading to ARDS



Haemorrhagic Transformation of Subacute Infarct



Acute Occlusive Portal Vein Thrombosis Extending into Superior Mesenteric and Splenic Veins



Contributed by:
Professor Manal Niazi
Department of Radiology
Dr. Akbar Niazi Teaching Hospital, Islamabad