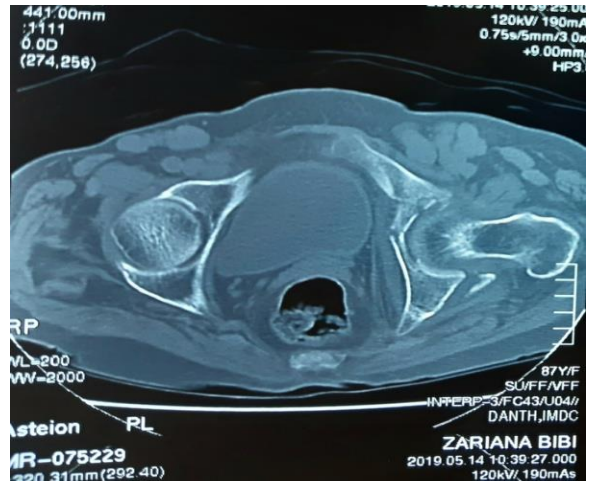
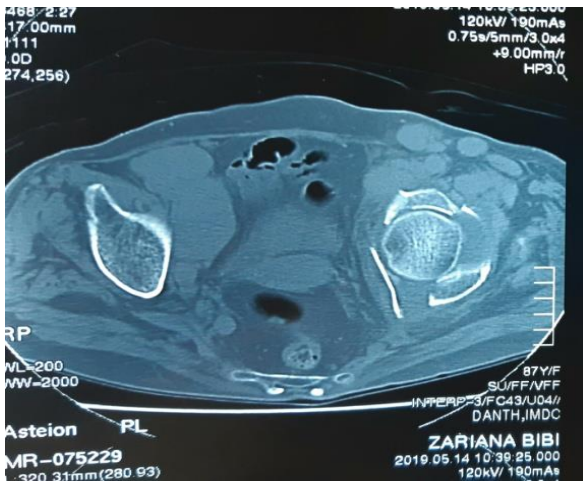
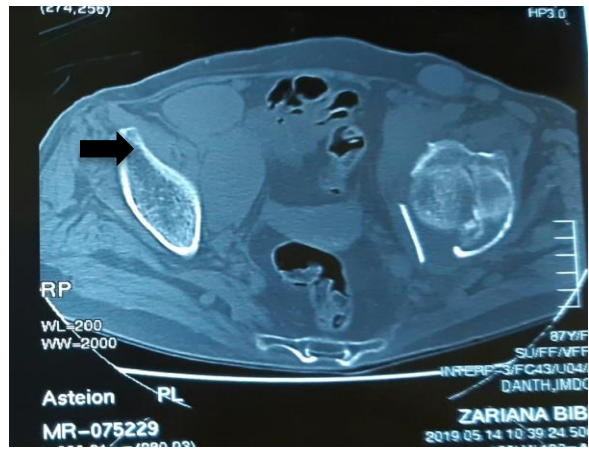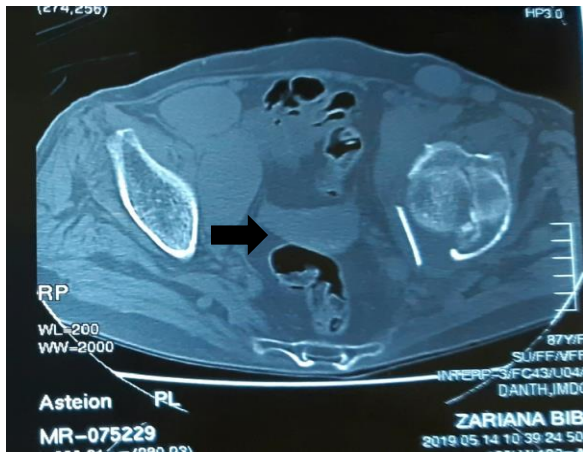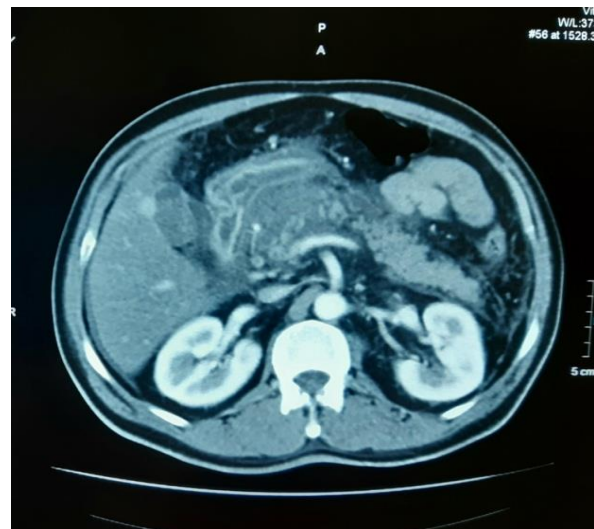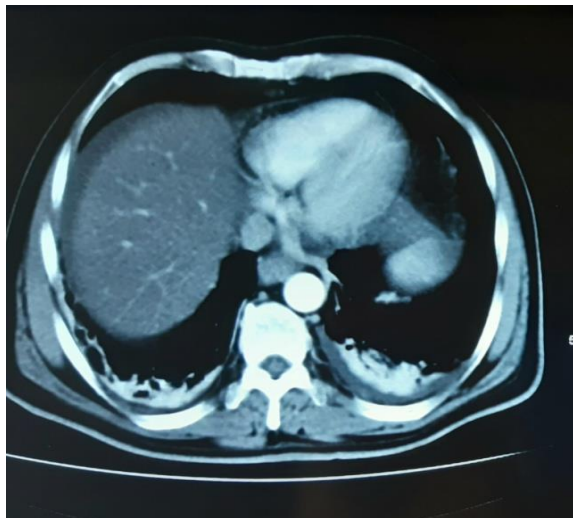
# RADIOLOGICAL IMAGES

## Comminuted Left Acetabular Fracture

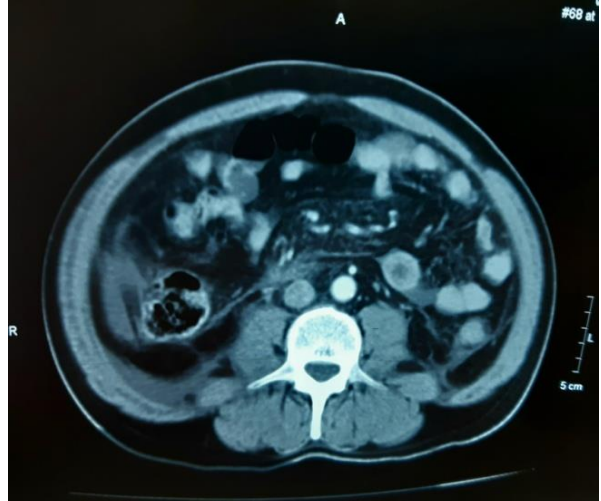
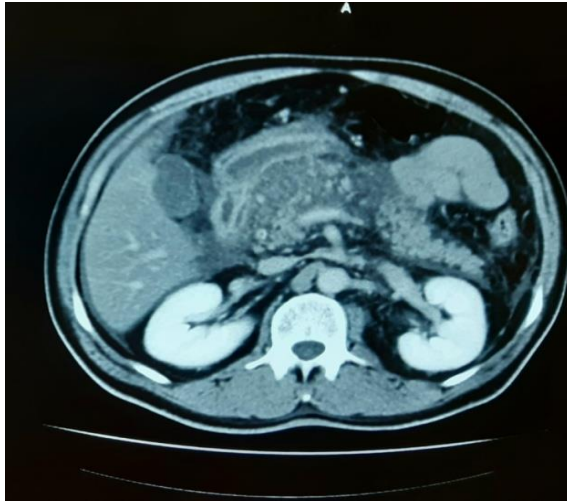
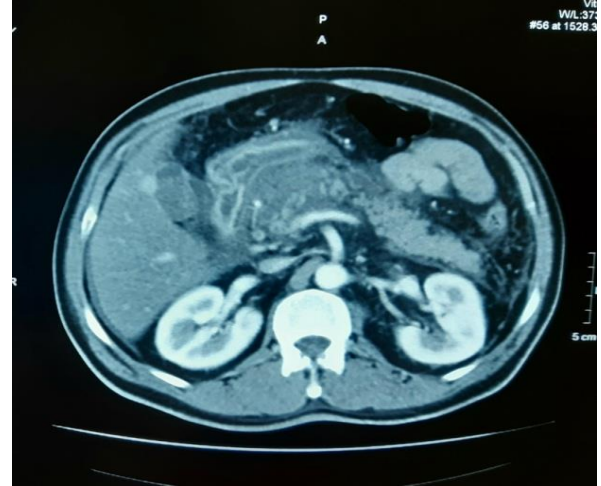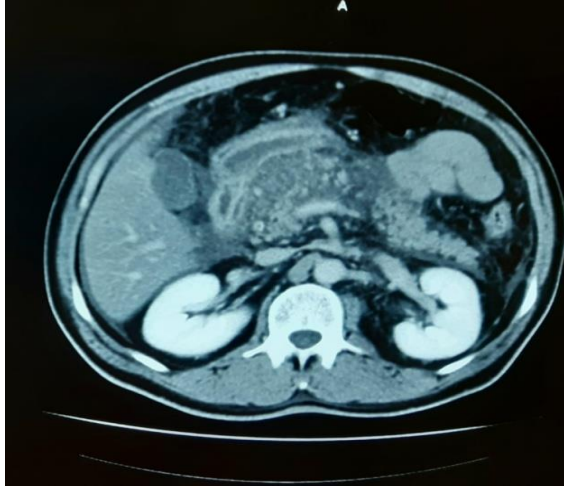Department of Radiology, Islamabad Medical and Dental College



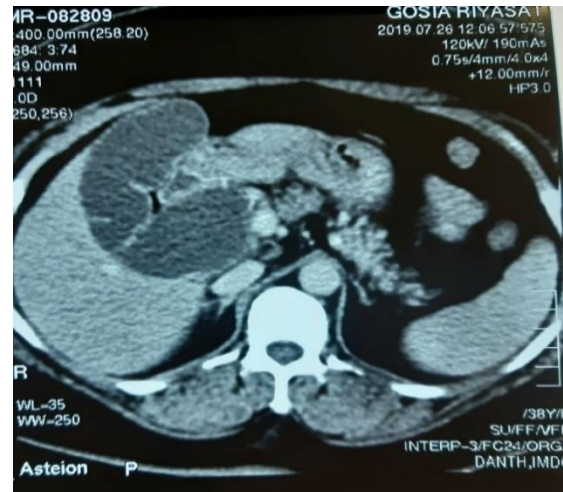
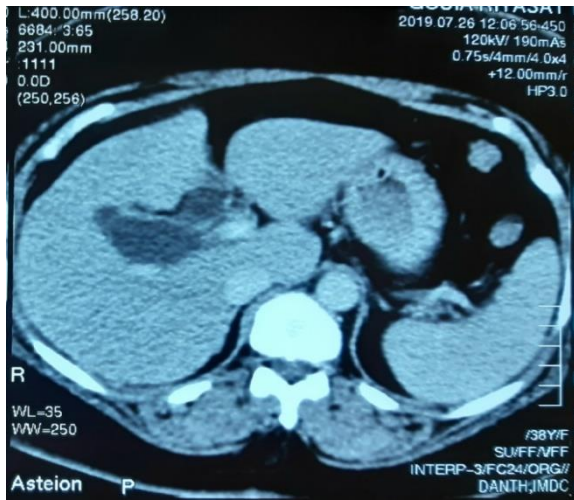
## Acute Pancreatitis



## Acute Pancreatitis

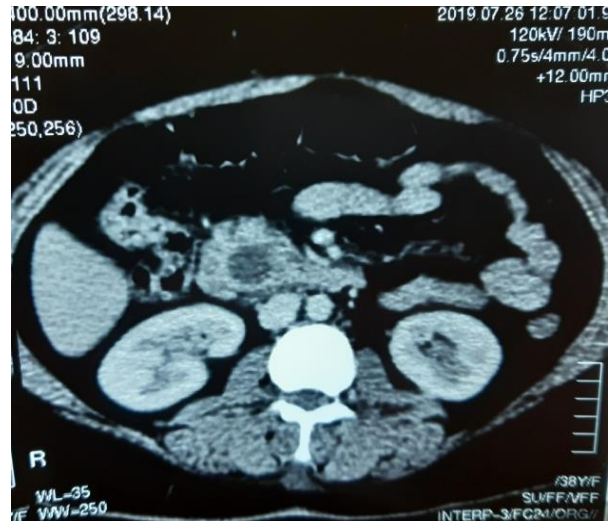
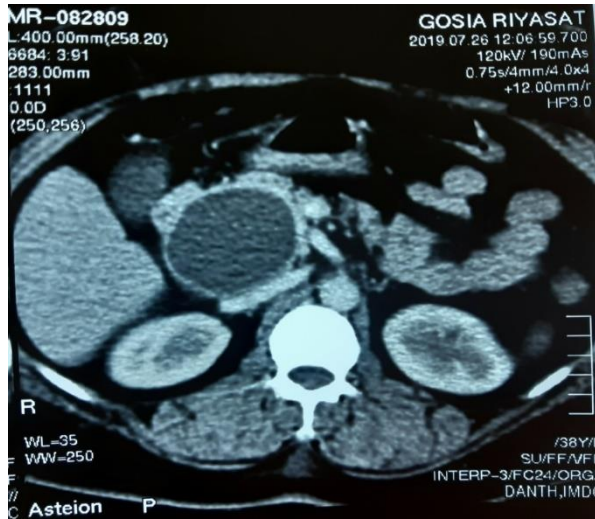


## Type 1 Choledochal Cyst: Fusiform Dilatation of CBD





## Type 1 Choledochal Cyst: Fusiform Dilatation of CBD



## Septic Cavitating Pulmonary Emboli:

Case of I/V drug abuser having infective endocarditis and vegetations on tricuspid valve

