

Osteocalcin favours the expression of synaptonemal complex protein 3 in azoospermic mouse model

Akanji Omotosho Dhulqarnain,^a Nasrin takzaree,^b Gholamreza Hassanzadeh,^b Somayeh Solhjo,^b Heidar Tooli,^b Mahsa Yaaghoobi Nejad,^b Pedram Shafaat,^b and Tayebeh Rastegar^{b*}

^aInternational Campus, Tehran University of Medical Science, Tehran, Iran.

^bAnatomy Department, School of Medicine, Tehran University of Medical Science, Tehran, Iran.

*Correspondence to Tayebeh Rastegar (email: trastegar@tums.ac.ir).

(Submitted: 11 June 2018 – Revised version received: 25 June 2018 – Accepted: 07 July 2018 – Published online: 26 February 2018)

Objective Infertility is the inability to conceive after regular unprotected sex for more than 1 year without the use of contraceptive. Azoospermia is defined as an absence of fertile sperm in seminal fluid. Men with azoospermia will guide the formulation of a therapeutic plan. Uncarboxylated form of the osteocalcin (OCN) modulates fertility. In this study, we investigated the role of osteocalcin on SYCP3 expression in azoospermic mouse model.

Methods Male mice (NMRI) ranging in age from 4 to 6 weeks (25 ± 5 g) were randomly divided into five groups (in all groups $n = 5$), Control, Sham I, Sham II, azoospermic model and azoospermic experimental OCN (3 ng/g/day) treated groups. At the end of the treatment period, (15th week age) the mice were sacrificed, left testes removed, weighted and put in fixative for morphology and IHC technique.

Results Testis weight was reduced in azoospermic and azoospermic OCN treated group compared with Control and Sham groups, but in azoospermic OCN treated group is more than azoospermic mice ($P \leq 0.05$). Daily injections of OCN improved spermatogenesis and SYCP3 expression in azoospermic OCN treated mice but not in azoospermic model.

Conclusion Our results suggests that the osteocalcin overexpressed SYCP3 expression and improved spermatogenesis.

Keywords azoospermia, osteocalcin, SYCP3, spermatogenesis

Introduction

Spermatogenesis is the process of production of male gametes known as spermatozoa that occurs in seminiferous tubules which are located within the testes. It is the process by which an animal produces spermatozoa from spermatogonial stem cells by the way of mitosis and meiosis. Due to a number of different factors, the sperm analysis in an ejaculate may fail to reach the minimum required for fertilization to take place. Thus, it can render such individual infertile.¹

Infertility is the inability to conceive after regular unprotected sex for more than 1 year without the use of contraceptive. It is a reproductive problem that affects approximately 15% of couples in general human population. Male factor of infertility accounts for about 50%² and about 7% of all men are affected by fertility problem.³ Azoospermia is diagnosed when no spermatozoa are detected upon microscopic evaluation of two centrifuged semen samples. Azoospermia is found in approximately 1% of all men and up to 15% of infertile men, depending upon the demographic nature of the infertile platoon.⁴ Azoospermia and oligospermia has been attributed to the effects of procedures like radiotherapy and chemotherapy in high dose such as busulfan⁵ which may leads to a prolong period of infertility in patients.⁶

Sex steroid hormone are important regulation of bone remodeling which help to maintain bone integrity.⁷⁻⁹ Based on physiological and clinical observations, it is hypothesized that bone mass, energy metabolism and reproduction might be coordinately regulated.¹⁰ Subsequent researches revealed that bone is an endocrine organ favoring whole-body glucose homeostasis, energy metabolism, and fertility. These functions of bone are mediated by an osteoblast-specific secreted molecule, osteocalcin (OCN), that when undercarboxylated acts as a hormone favoring β -cell proliferation, insulin secretion, and fertility.¹¹

It has now been discovered that osteocalcin, in addition to its endocrine role as a regulator of energy homeostasis, favors male fertility by promoting synthesis of testosterone, a steroid hormone required for many aspects of testicular function from Leydig cells of the testes. Also, a receptor was identified for osteocalcin that is expressed and transduces its signal in Leydig cells. In view of this, osteocalcin can be said to affect male fertility by regulating the level of testosterone production from the testes.¹²

Synaptonemal complex protein 3 (SYCP3) is an important marker of meiotic germ cell division during the process of spermatogenesis.¹³ Abnormalities in human synaptonemal complex formation are considered to be responsible for a proportion of unexplained azoospermic cases. Therefore, SYCP3 could be a tool for the prediction of human spermatogenesis progression, especially in infertile men.¹⁴

Testosterone hormone secretion in Leydig cell is under the influence of hypothalamus–hypophysis–testis axis. Hypothalamus secretes Gonadotropin releasing hormone which stimulate the pituitary gland for the production of follicle stimulating hormone and leutinizing hormone (LH). This suggests that hypothalamus–testis axis regulates testosterone production in Leydig cell and ultimately affect reproduction. Also, considering the role of osteocalcin in testosterone production which affects reproduction, then we suspect a relationship between osteocalcin and SYCP3 expression in germ cells during spermatogenesis as it may affect reproduction in men. In light of this, osteocalcin, through its own pathway may be an important factor in regulating the expression of SYCP3 during meiotic division of germ cells.¹⁵

Thus, in this study, we have supposed that osteocalcin improve spermatogenesis in azoospermic mice by the expression of SCYCP3.

Materials and Methods

Animal Preparation

Male mice (NMRI) ranging in age from 4 to 6 weeks (25 ± 5 g) were obtained from the Pasteur institute of Iran. Animals were housed in wire cages at $23 \pm 1^\circ\text{C}$ under a 12 h light–dark cycle with 70% humidity and fed a standard diet and water. Animals were maintained and experiments were conducted in accordance with the Principles of Laboratory Animal Care of Tehran University of Medical Sciences, Iran.

All animals were randomly allocated into five groups, Control group ($n = 5$), azoospermic experimental group ($n = 5$) that received a single intraperitoneal injection of busulfan (40 mg/kg body weight) diluted in dimethyl sulfoxide (DMSO, USA) at 5 weeks old,¹⁶ Sham I group ($n = 5$) that received a single intraperitoneal injection of DMSO (busulfan solvent) at 5 weeks old, Sham II group ($n = 5$) that received a single intraperitoneal injection of DMSO at 5 weeks old and after 5 weeks they received phosphate buffer solution (PBS) intraperitoneal injection for 1 month and azoospermic experimental treated group ($n = 5$) that received a single intraperitoneal injection of busulfan (40 mg/kg body weight) diluted in DMSO at 5 weeks old and after 5 weeks they received recombinant osteocalcin (H00000632, Novus, USA) intraperitoneal injection 3 ng/g/day for 1 month.¹²

Drugs Preparation

Busulfan (B2635, Sigma, USA) was first dissolved in DMSO (P8340, Sigma, USA), then an equal volume of sterile water was added to obtain a final busulfan concentration of 20 mg/ml.¹⁷ Osteocalcin was dissolved in PBS (P4417, Sigma, USA).¹⁸

Surgical Procedure

At the end of the treatment period (15th week), the mice were weighed and anesthetized using intraperitoneal ketamine (50 mg/kg) and xylazine (20 mg/kg), and were killed, the peritoneal cavity was opened through a lower transverse abdominal incision. As well as, left testes in all groups were immediately removed, weighed and put in fixative for staining.¹⁷

Preparation of Busulfan-Induced Azoospermic Model

The busulfan-treated infertile mouse model was prepared as described by Brinster with some modification. Mice were received a single dose intraperitoneal injection of busulfan (40 mg/kg) at 4–6 weeks of age. Hematoxylin–Eosin stain of testicular cross section, also Eosin–Nigrosine staining of seminal fluid was performed to evaluate the azoospermic model 5 weeks after busulfan injection.^{16,19}

Confirmation of Busulfan-Induced Azoospermic Model

Hematoxylin and Eosin staining technique

Hematoxylin and Eosin (H&E) stains have been used for at least a century and are still essential for recognizing various tissue types and the morphologic changes. Testes tissues of Control and azoospermic mouse were fixed in Bouin's solution, embedded in paraffin, sectioned at 5 μm and sections were stained with H&E, then the morphological aspect of seminiferous tubules was studied.²⁰

Eosin–Nigrosin staining technique

Eosin–Nigrosin is a staining technique that assesses the vitality of a sperm sample. Briefly 20 μl of semen were gently stirred (30 s at 37°C) in 60 μl of Eosin–Nigrosin stain (5%–Nigrosin and 4%–Eosin-Y at ratio 3:1). Then, smears were prepared and dried at room temperature. The slides were examined by a single observer with phase-contrast microscope (magnification: 1000 \times) after preparation. A total of 200 spermatozoa per slide were scored for dead/live spermatozoa. This method is based on the degree of membrane permeability of dead spermatozoa which heads show pink or red coloration, whereas the low permeability of live gametes excludes Eosin and therefore their head maintains whitish.¹⁹

Immunohistochemistry for SYCP3

Testes tissues were fixed in formaldehyde solution, embedded in paraffin, sectioned at 5 μm and sections were incubated with primary Rabbit polyclonal Anti-SCP3 antibody (ab15093, Abcam, 1/100/overnight) and then secondary Goat Anti-Rabbit HRP conjugated antibody (ab6721, Abcam, 1/100/2 h) was added. Counterstain nucleus staining was done by hematoxylin.

Statistics

The results were expressed as mean \pm SE. The statistical significance between the mean values was determined by one-way analysis of variance (ANOVA), Tukey and Duncan post-test. $P \leq 0.05$ was considered significant.

Results

Osteocalcin Increased Testes Weight of Azoospermic Mice

The obtained results in this study were illustrated in Fig. 1. Testis weight was reduced in azoospermic and Sham II group compared with Control and Sham I groups, but in azoospermic OCN treated group is more than azoospermic mice ($P \leq 0.05$).

Confirmation of Azoospermia in Mice

Five weeks after the injection of mice with busulfan, in histopathological study, most of the endogenous sperm cells were removed while the interstitial tissue and Sertoli cells remained; some seminiferous tubules appeared as Sertoli-cell-only structures compared with Control group (Fig. 2).

The results of Eosin–Nigrosin staining which determine the survival rate of sperm and confirm the azoospermic model as shown by the phase-contrast microscope indicates that the acidophilic content is introduced into the head of the dead sperm and is therefore visible in pink, while the sperm head vivid live colors were observed (Fig. 3).

Osteocalcin Improved Spermatogenesis in Azoospermic but does not Affect Somatic Cells of the Testes

Histological study of seminiferous tubules of Control group was with normal spermatogenesis of thickening germ cells; also in Sham I group that received solvents (DMSO and PBS). In azoospermic and Sham II groups which tubules are relatively evacuated and absence of germ cell line. Osteocalcin-treated

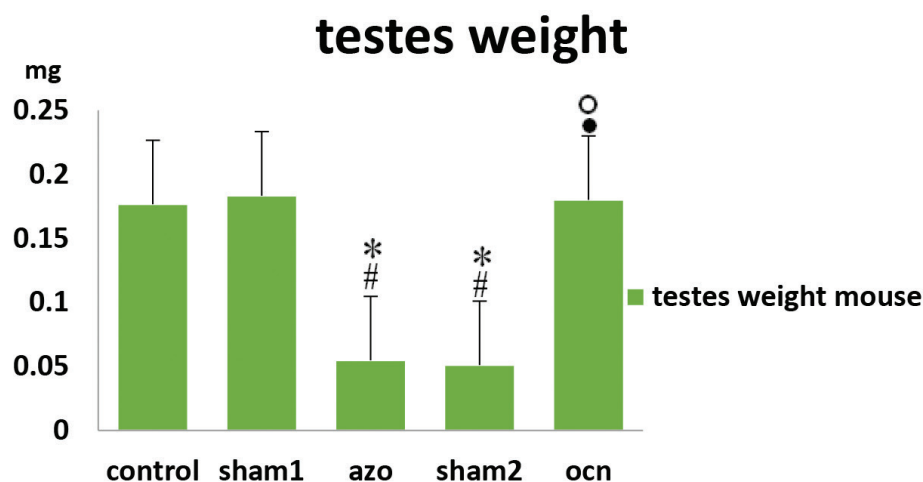


Fig. 1 Testis weight in different groups. Testis weight was reduced in azoospermic and Sham II groups compared with Control and Sham I group, but in azoospermic OCN treated group is more than azoospermic and Sham II mice ($P \leq 0.05$). # Significant with Control group. * Significant with Sham I group. ° Significant with azoospermic group.

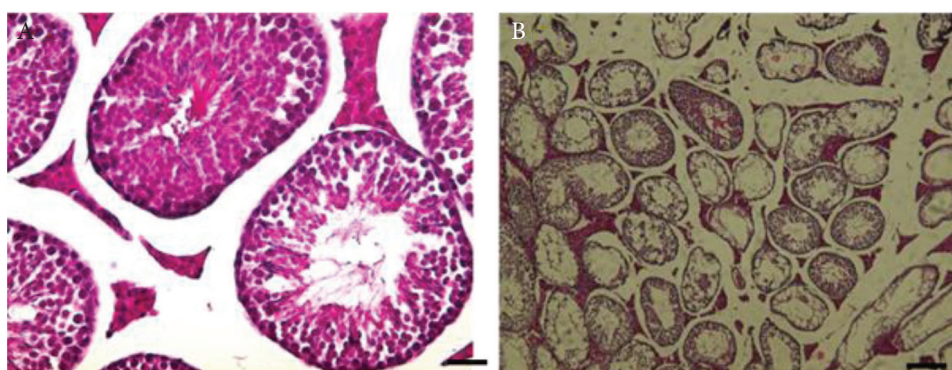


Fig. 2 H&E staining in busulfan induced azoospermic model preparation. (A) Histological morphology of untreated testis, as normal control. (B) Histological morphology of testicular tissue 5 weeks after injection with 40 mg/kg busulfan. Most of the endogenous sperm cells had been removed, while interstitial tissue and Sertoli cells remained. Scale bar: 50 μ m.

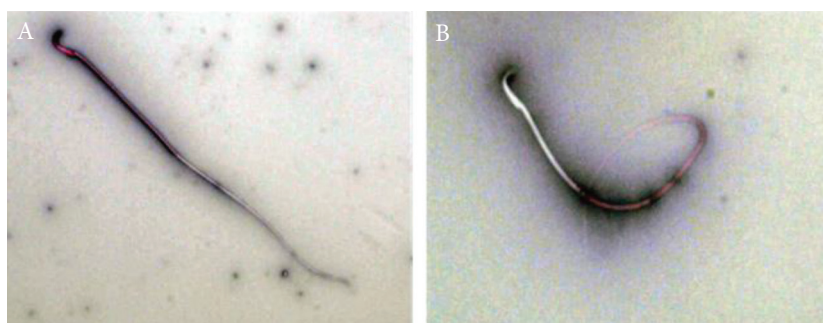


Fig. 3 The Eosin–Nigrosin-stain produces a dark background on which the sperm stand out as lightly colored objects. (A) Dead sperm take up eosin and appear pinkish in color (B) whereas normal live sperm exclude the eosin stain and appear white in color.

group shows a thick germinal layer and the presence of various germ cells indicative of presence and the improvement of spermatogenesis (Fig. 4). Using the one-way ANOVA, SPSS 16 software and Tukey test for statistical analysis of germ cell, the number of spermatonia, spermatocytes, round and elongated spermatids increase in experimental group, no significant change in Control and Sham I and the number significantly decrease in azoospermic and Sham II compared with the Control, Sham I and experimental group ($P < 0.05$). Also, there is no significant difference in the number of germ cells in azoospermic and Sham II group ($P < 0.05$). The diameter of the germinal layer of the seminiferous tubule is increased in experimental group compared with the azoospermic group. There is no significant difference in the diameter of the germinal layer of Control and Sham I. No significant difference in azoospermic and Sham II but there is significant difference in azoospermic and Sham II when compared with Control, Sham I and experimental group. This result indicates that osteocalcin increase the number of germ cells and thereby, increase in the thickness of the germinal layer of seminiferous tubule

($P < 0.05$). We also discovered that in all the groups, there is no significant differences in the diameter of the whole length of seminiferous tubule ($P < 0.05$). However, there is no significant difference in the number of Sertoli, Leydig and Myoid cells all using the Anova test ($P < 0.05$) (Fig. 5).

Osteocalcin Favours the Expression of SYCP3 in Azoospermic Mouse

We performed immunohistochemistry to access the presence of SYCP3 protein in all the groups which is positive for Control, Sham I and experimental group but none in azoospermic and Sham II groups as observed with light microscope. This suggest that busulfan caused the apoptosis of germ cells which result in disruption of process of spermatogenesis and therefore, no SYCP3 protein expression (Figs. 6 and 7).

Discussion

The aim of this research is to determine the role of osteocalcin in spermatogenesis progression in azoospermic mice model

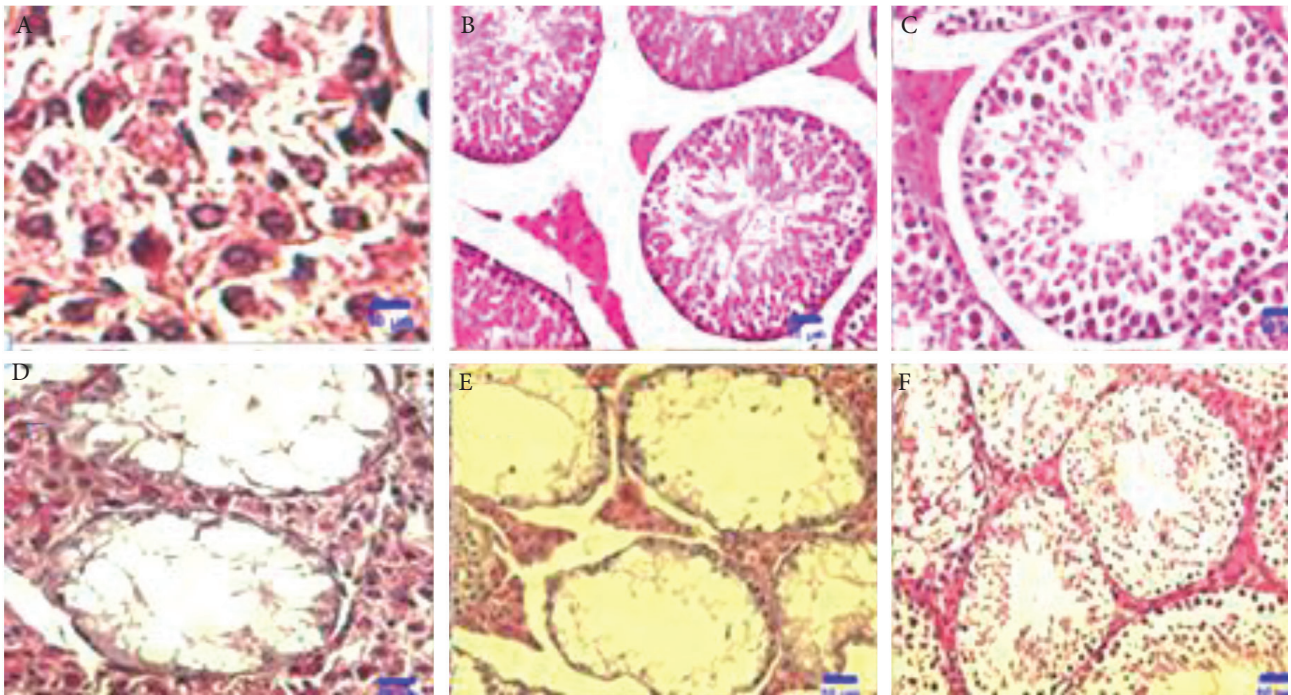


Fig. 4 H&E staining transverse cross section of testis seminiferous tubule. (A) Spermatocyte (S) display on the tubules. (B) Control group with normal spermatogenesis of thickening germ cells. (C) Sham I group that received solvents (DMSO and PBS). (D) Azoospermic group which tubules are relatively evacuated and absence of germ cell line. (E) Sham II group azoospermic mice which received osteocalcin solvent (PBS) for 30 days, Presence of vacuoles and loss of germ cells. (F) Osteocalcin-treated group shows a thick germinal layer and the presence of various germ cells indicative of presence and the improvement of spermatogenesis. Scale bar: 50 μ m.

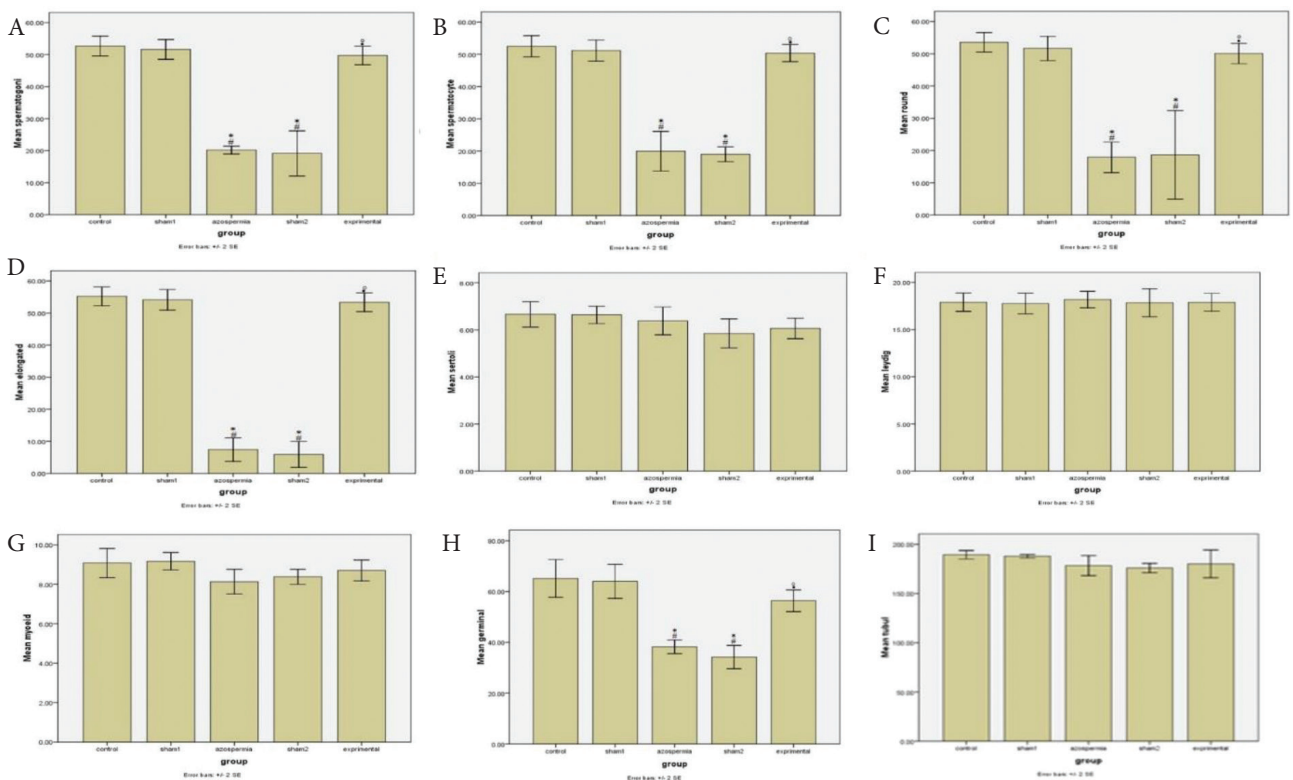


Fig. 5 Data of the variables of the testis seminiferous tubule. (A) Number of spermatogonia cells. (B) Spermatocytes. (C) Round spermatid cells. (D) Elongated spermatid cells. (E) Sertoli cells. (F) Leydig cells. (G) Myoid cells. (H) Germinal layer thickness. (I) Seminiferous tubules diameter ($p < 0.05$). # Significant with Control group. * Significant with Sham I group. • Significant with Azoospermic group. ° Significant with Sham II group. Control: Control group; Sham I: which received solvents (DMSO and PBS). azoospermia: Azoospermic animals that received busulfan 40 mg/kg/i.p. Sham II: Azoospermic mice received PBS for 1 month. Experimental: azoospermic mice that received osteocalcin.

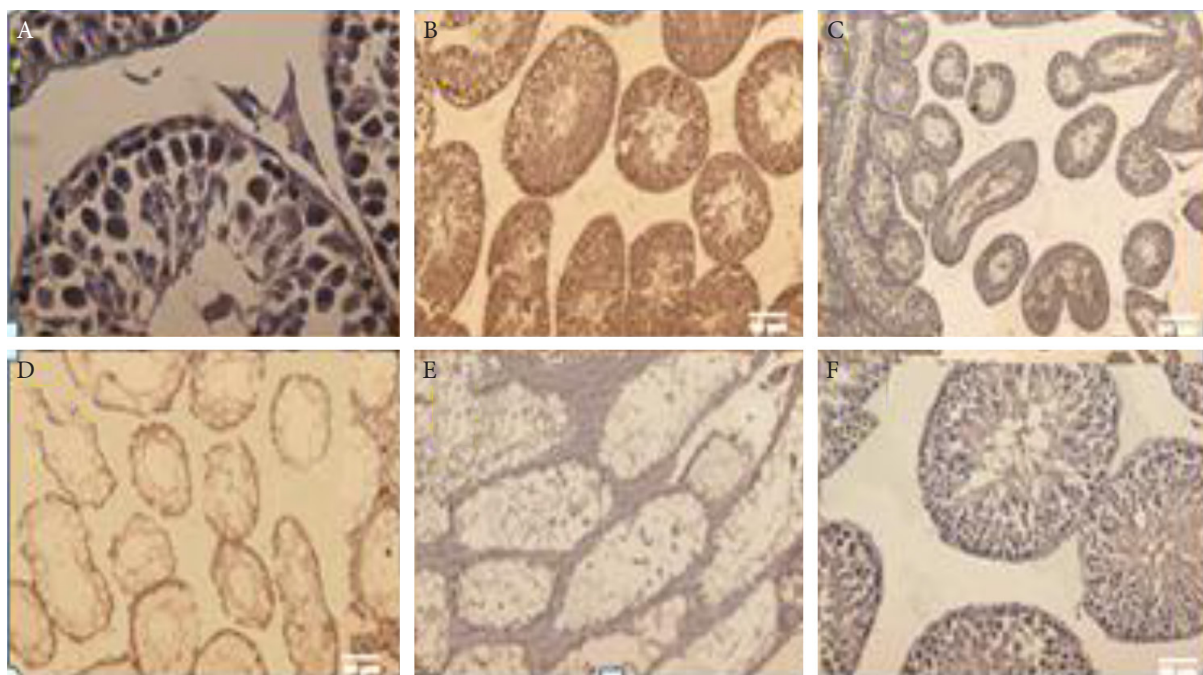


Fig. 6 Immunohistochemistry of cross section testis seminiferous tubule for detection of SYCP3. (A) Showing spermatocyte cells with positive SYCP3 in the testicular germinal layer. (B) Control group with normal spermatogenesis and thickening of the germinal layer. (C) Sham I group that received solvents (DMSO and PBS). (D) Azoospermic group, absence of positive SYCP3 cells. (E) Sham II group azoospermic mice that received osteocalcin solvent (PBS) for 30 days without any SYCP3 positive cells. (F) Osteocalcin-treated group shows thick germinal layer and the presence positive SYCP3 cells. Scale bar: 50 μ m.

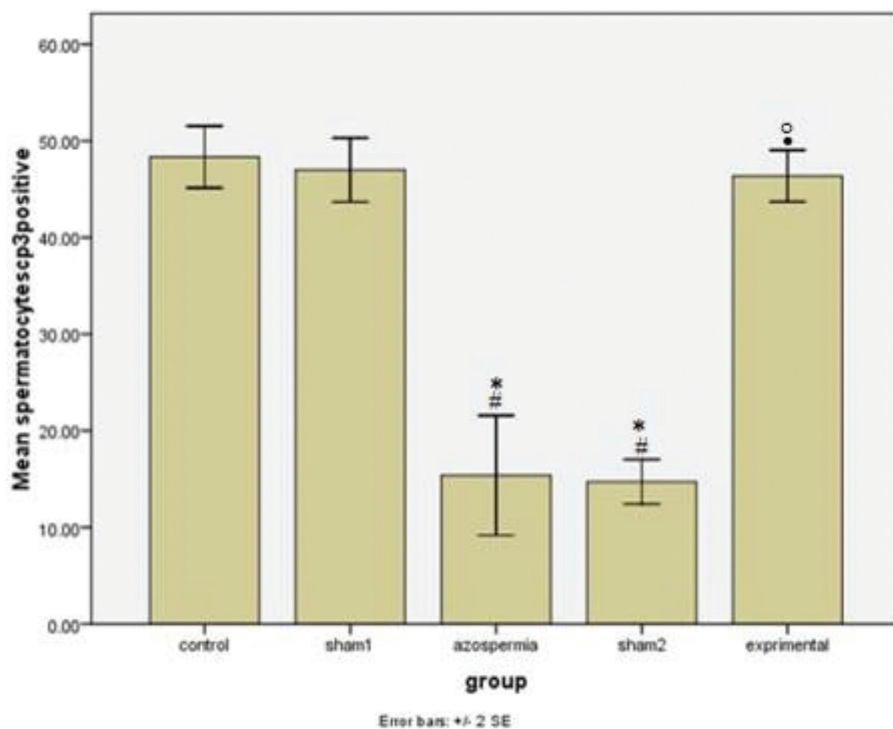


Fig. 7 Mean and standard error (mean \pm SE) of SYCP3 positive spermatocytes cells. Control group kept in normal condition. Sham I which received busulfan solvent (DMSO) and after 5 weeks, animals received osteocalcin solvent (PBS) for 30 days. Azoospermia group contains animals that received single dose of busulfan (40 mg/kg) by intraperitoneal injection. Sham II group animals received 40 mg/kg dose of busulfan in single dose by intraperitoneal injection. Animals in this group received osteocalcin solvent (PBS) for 30 days after 5 weeks. Experimental group (azoospermia-OCN) includes azoospermic mice that received osteocalcin dose of 3 ng/g/day after 5 weeks for 1 month ($p < 0.05$). *Significant with Control group. #Significant with Sham I group. °Significant with azoospermic group. °Significant with Sham II group.

which can be used to provide insight into treatment of infertility. Our results showed the depletion of germinal layer of seminiferous tubules in azoospermic mice which confirm the general belief about busulfan as causative agent for apoptosis in germ cells seminiferous tubules.

Our main concern is to find the expression of SYCP3 which signals the progression of spermatogenesis in azoospermic mice after treatment with osteocalcin.

Recent researches have directly linked osteocalcin to energy metabolism and reproduction in men but not in women. It performs these roles when it is in its undercarboxylated form. The increasing evidence of the role of gonad in bone metabolism provides a suitable ground for these doubts, and raises the possibility that bone, through a feedback mechanism in its endocrine function, could affect reproduction in either gender.²¹

Leydig cells of the testes are responsible for the secretion of testosterone which also determines the development of male reproductive organs, germinal cells and estrogen production. The main regulation of testosterone of the testes is the pituitary hormone, luteinizing hormone (LH).^{13,14} With this, we least expect that there will be another hormone that plays an important role in regulating men fertility, and this hormone, osteocalcin, was made in bone. The fact that osteocalcin^{-/-} male mice are subfertile with a marked decrease in circulating testosterone and low sperm count established the biological relevance of this regulation *in vivo* in the mouse.²²

Having said that, it is widely believed that osteocalcin favors testosterone production which ultimately leads to improved spermatogenesis. In this research, we confirmed the role of osteocalcin in the progression of spermatogenesis through the expression of a meiotic protein marker (SYCP3) in spermatocytes. Consequently, there is significant increase in the thickness of the germinal layer and reduction of the lumen as a result of increase in germ cells which progress the process of spermatogenesis. However, Schwetz et al.²³ showed that osteocalcin is not a strong determinant of serum testosterone and sperm count in men from infertile couples. We also found out that the amount of Leydig cells of the testes is independent of the level of undercarboxylated osteocalcin with insignificant changes in all the groups investigated. We also found out that the number of Sertoli and Myhoid cells in the seminiferous tubules are independent of the circulating level of osteocalcin.

It has been shown that osteocalcin favours testosterone biosynthesis through the pancreas–bone–testes axis by binding to its receptor GPR6ca in Leydig cells of the testes.²² They demonstrated that testes size and weight, epididymides and seminal vesicles weights, sperm count and circulating testosterone levels were all reduced in 12 weeks old Ocn^{-/-} mice²² which support the idea that osteocalcin expression in osteoblast improve fertility in men. However, different researches show that osteocalcin dependent and insulin dependent reproduction have different pathways.

Also, it is believed that SYCP3 is expressed only in germ cells of testes and ovary.¹³ In light of this, we observed the expression of this protein in germ cells. In this research, we observed positive correlation between the expression of SYCP3 and osteocalcin. This protein expression is absent in azoospermic

group. In azoospermic group, there is apoptotic germ cell line which disrupt the progression of spermatogenesis. Recent researches show that SYCP3 protein expression in mice occur at the level of prophase 1 in meiotic division.^{13,24,25} This is in-line with the discovery of Mahmoud et al.²⁶ in human that the expression of SYCP3 begins at the level of primary spermatocytes. The disruption of the SYCP3 gene has been found to obstruct formation of axial elements and to induce cell death of mutant spermatocytes during an extended zygotene stage.²⁴ Truly, we discovered the expression of this protein in spermatocytes which are actively dividing cells in the process of spermatogenesis.

We conclude that the lack of expression of SYCP3 protein during meiotic division causes germ cell apoptosis and consequently, no progression of spermatogenesis which leads to infertility. However, osteocalcin hormone can help restore spermatogenesis by favoring the expression of this protein. To shed more light on the role of osteocalcin hormone in progression of germ cell meiotic division, we encourage more research on interaction between osteocalcin hormone and SYCP3 gene in animal model which could give insight and provide important breakthrough in addressing the genetic causes of infertility in human.

Acknowledgment

The authors are grateful for Tehran University of Medical Sciences. This work was supported by Grant No. 34910 from Tehran University of Medical Sciences.

Compliance with Ethical Standards

This work was supported by Grant No. 34910. All authors received research grants from Tehran University of Medical Sciences. All authors declares that they have no conflict of interest. Animals were maintained and experiments were conducted in accordance with the Principles of Laboratory Animal Care of Tehran University of Medical Sciences, Iran.

Conflict of Interest

None. ■

References

- Clermont Y. The cycle of the seminiferous epithelium in man. *Am J Anat*. 1963;112:35–51.
- Seshagiri PB. Molecular insights into the causes of male infertility. *J Biosci*. 2001;26:429–435.
- Krausz C. Male infertility: pathogenesis and clinical diagnosis. *Best Pract Res Clin Endocrinol Metab*. 2011;25:271–285.
- Hammoud AO, Gibson M, Peterson CM, Meikle AW, Carrell DT. Impact of male obesity on infertility: a critical review of the current literature. *Fertil Steril*. 2008;90:897–904.
- de Rooij DG, van de Kant HJ, Dol R, Wagemaker G, van Buul PP, van Duijn-Goedhart A, et al. Long-term effects of irradiation before adulthood on reproductive function in the male rhesus monkey. *Biol Reprod*. 2002;66:486–494.
- Jackson H, Fox BW, Craig AW. The effect of alkylating agents on male rat fertility. *Br J Pharmacol Chemother*. 1959;14:149–157.
- Khosla S, Melton LJ 3rd, Atkinson EJ, O'Fallon WM. Relationship of serum sex steroid levels to longitudinal changes in bone density in young versus elderly men. *J Clin Endocrinol Metab*. 2001;86:3555–3561.
- Nakamura T, Imai Y, Matsumoto T, Sato S, Takeuchi K, Igarashi K, et al. Estrogen prevents bone loss via estrogen receptor alpha and induction of Fas ligand in osteoclasts. *Cell*. 2007;130:811–823.
- Riggs BL, O'Fallon WM, Muhs J, O'Connor MK, Kumar R, Melton LJ 3rd. Long-term effects of calcium supplementation on serum parathyroid hormone level, bone turnover, and bone loss in elderly women. *J Bone Miner Res*. 1998;13:168–174.
- Ducy P, Amling M, Takeda S, Priemel M, Schilling AF, Beil FT, et al. Leptin inhibits bone formation through a hypothalamic relay: a central control of bone mass. *Cell*. 2000;100:197–207.
- Oury F. A crosstalk between bone and gonads. *Ann NY Acad Sci*. 2012;1260:1–7.
- Pi M, Wu Y, Quarles LD. GPRC6A mediates responses to osteocalcin in β -cells *in vitro* and pancreas *in vivo*. *J Bone Miner Res*. 2011;26:1680–1683.
- Parra MT, Viera A, Gomez R, Page J, Benavente R, Santos JL, et al. Involvement of the cohesin Rad21 and SCP3 in monopolar attachment of sister kinetochores during mouse meiosis I. *J Cell Sci*. 2004;117:1221–1234.
- Judis L, Chan ER, Schwartz S, Seftel A, Hassold T. Meiosis I arrest and azoospermia in an infertile male explained by failure of formation of a component of the synaptonemal complex. *Fertil Steril*. 2004;81:205–209.
- Oury F, Sumara G, Sumara O, Ferron M, Chang H, Smith CE, et al. Endocrine regulation of male fertility by the skeleton. *Cell*. 2011;144:796–809.
- Brinster CJ, Ryu BY, Avarbock MR, Karagenc L, Brinster RL, Orwig KE. Restoration of fertility by germ cell transplantation requires effective recipient preparation 1. *Biol Reprod*. 2003;69:412–420.

17. Ahar NH, Khaki A, Akbari G, Novin MG. The effect of busulfan on body weight, testis weight and mda enzymes in male rats. *Int J Women's Heal Reprod Sci.* 2014;2:316–319.
18. Zhou B, Li H, Liu J, Xu L, Zang W, Wu S, et al. Intermittent injections of osteocalcin reverse autophagic dysfunction and endoplasmic reticulum stress resulting from diet-induced obesity in the vascular tissue via the NFκB-p65-dependent mechanism. *Cell Cycle.* 2013;12: 1901–1913.
19. Björndahl L, Söderlund I, Kvist U. Evaluation of the one-step eosin-nigrosin staining technique for human sperm vitality assessment. *Hum Reprod.* 2003;18:813–816.
20. Bancroft JD, Layton C. *The Hematoxylin and Eosin. Theory & Practice of Histological Techniques.* 7th Ed.; Churchill Livingstone of Elsevier, Philadelphia, 2013, p. 173–214.
21. Schuh-Huerta SM, Pera RAR. Reproductive biology: bone returns the favour. *Nature.* 2011;472:46–47.
22. Oury F, Sumara G, Sumara O, Ferron M, Chang H, Smith CE, et al. Endocrine regulation of male fertility by the skeleton. *Cell.* 2011;144:796–809.
23. Schwetz V, Gumpold R, Graupp M, Hacker N, Schweighofer N, Trummer O, et al. Osteocalcin is not a strong determinant of serum testosterone and sperm count in men from infertile couples. *Andrology.* 2013;1:590–594.
24. Yuan L, Liu JG, Zhao J, Brundell E, Daneholt B, Höög C. The murine SCP3 gene is required for synaptonemal complex assembly, chromosome synapsis, and male fertility. *Mol Cell.* 2000;5:73–83.
25. Liebe B, Alsheimer M, Hoog C, Benavente R, Scherthan H. Telomere attachment, meiotic chromosome condensation, pairing, and bouquet stage duration are modified in spermatocytes lacking axial elements. *Mol Biol Cell.* 2004;15:827–837.
26. Aarabi M, Modarressi MH, Soltanghorae H, Behjati R, Amirjannati N, Akhondi MM. Testicular expression of synaptonemal complex protein 3 (SYCP3) messenger ribonucleic acid in 110 patients with nonobstructive azoospermia. *Fertil Steril.* 2006;86:325–331.

This work is licensed under a Creative Commons Attribution-NonCommercial 3.0 Unported License which allows users to read, copy, distribute and make derivative works for non-commercial purposes from the material, as long as the author of the original work is cited properly.