

The role of 3-dimensional multi-detector computed tomography in the diagnosis of Eagle's syndrome and correlation with severe headache and migraine (Iraqi study)

Shefaa Al-Nuamee, B.D.S., H.D.D., M.Sc. ⁽¹⁾

Waad Haider, M.B.Ch.B., D.GA. ⁽²⁾

Ali Muhssen, M.B.Ch.B., F.I.C.M.S. ⁽³⁾

Abbod Al-Razqi, M.B.Ch.B., F.I.C.M.S. ⁽⁴⁾

Tariq Jassim, M.B.Ch.B., D.R.M.R. ⁽⁵⁾

Mona A. Al-Safi, B.D.S. M.Sc. ⁽⁶⁾

ABSTRACT

Background: The styloid process is a cylindrical bone (protrusion). It situated above the common carotid artery between the external and internal branches immediately proximal to the internal jugular vein and facial nerves. The styloid process varies in length also it may be absent as well as elongated. Classically, an elongated styloid process and calcified of stylohyoid ligament causes Eagle's syndrome. The aim of this study was to examine the styloid process using 3 dimensional multi-detector computed tomography (3D-MDCT) to detect the presence of Eagle's syndrome that causes severe headache and migraine.

Materials and methods: One hundred patients with severe headache and migraine were exposed to 3D- multi-detector CT with special brain CT in Al-Karkh general hospital to examine the styloid process. By elongated the field of the brain CT multi-detector downward and using facial volume, the morphological alterations of styloid process and stylohyoid ligament can be discovered.

Results: Thirty four patients (25 females and 9 males) had a problem in the styloid process. Seven of them were suffered from elongation of styloid process while 27 patients had fractured styloid process unilaterally or bilaterally

Conclusion: Eagle's syndrome is one of the important causes of severe headache and craniofacial pain which is detected by special field of brain 3D CT - multi-detector.

Key word: CT multi-detector, styloid process elongation, fracture. (J Bagh Coll Dentistry 2013; 25(Special Issue 1):72-76).

INTRODUCTION

The styloid process is a slender outgrowth at the base of the temporal bone, immediately posterior to the mastoid apex. It arises from the inferior surface of the temporal bone at the junction of its petrous and tympanic portions ^(1,2). It lies caudally, medially, and anteriorly towards the maxillo-vertebro-pharyngeal recess (which contains carotid arteries, internal jugular vein, facial nerve, glossopharyngeal nerve, vagal nerve, and hypoglossal nerve) ^(1,3). The length of the styloid process was measured on CT scan brain trauma from the skull base to the tip of the styloid process ^(4,6). In terms of the length, 30 mm was considered as normal and processes longer than 30 mm were considered as elongated ^(1,2).

With the stylohyoid ligament and the small horn of the hyoid bone, the styloid process forms the stylohyoid apparatus, which arises embryonically from the Reichert cartilage of the second branchial arch ⁽³⁾. These structures are first formed in cartilage. The cartilage of the styloid process ossifies while the epiphyseal cartilage, which connects the styloid process and the hyoid bone, is usually reabsorbed.

The stylohyoid ligament is formed from the remnants of the epiphyseal cartilage ⁽²⁾. In some individuals, separate epiphyseal bone forms when the epiphyseal cartilage ossifies rather than resorbs ⁽⁵⁾.

Ossified stylohyoid ligament occurs as a result of true ossification, rather than calcification due to stress or degeneration, because there is radiographic evidence of ossified stylohyoid ligaments in children ⁽³⁾. Eagle described it as a syndrome complex mainly in two varieties. The classical variety presents as pain in the throat, referred to as otalgia and foreign body sensation in the throat ^(1,4). A second variety is styloid process compressing the carotid artery presenting as carotodynia, headache and dizziness ^(1,2,4).

(1) Specialist, Department of Maxillofacial Radiology and Surgery, Ministry of Health.

(2) Specialist, Department of General Anesthesia, Ministry of Health.

(3) Specialist, Department of Psychology

(4) Specialist, Department of ENT, Ministry of Health.

(5) Specialist, Department of Orthopedic, Ministry of Health.

(6) Assistant Professor, Head of dental Department, Alyarmok. College University.

CT for head injury scans should be done without gantry angulations at increments of 5 to 10 mm from the base of the skull through the hyoid bone. Extending the CT examination to include this area will not prolong the scan significantly and may add valuable information about the cervical spine and soft tissues of the neck ⁽⁶⁾.

The anatomical importance is that the styloid process lies between the internal and external carotid arteries and just posterior to the pharyngeal wall in the region of the palatine fossa. Three muscles originate from the styloid process, each innervated by a different nerve: 1. the styloglossus, innervated by the hypoglossal nerve; 2. the stylopharyngeal, which is innervated by the glossopharyngeal nerve; and 3. the stylohyoid, innervated by the facial nerve. In addition to the carotid arteries, the styloid process lies closely to five cranial nerves (the facial, glossopharyngeal, vagus, spinal accessory, the hypoglossal and the internal jugular vein ⁽⁷⁾). The symptoms of the termed carotid artery syndrome by Eagle called the styloid process-carotid artery syndrome, which is characterized by dull nagging to sharp pharyngeal pain, headaches and vertigo ⁽⁵⁾.

Elongation styloid process of temporal bone related to ⁽⁸⁾:

1. Increase length
2. Fracture
3. Tension
4. Macromolecule
5. Long chain
6. Synthesis

Causes of styloid process elongation

1. Elongation of macromolecule e.g. in the synthesis of long chains of long fatty acid or in the synthesis of protein source ⁽⁹⁾.
2. Ectopic metastatic calcification in non-osseous soft tissue due to abnormal serum Ca, vitamin D and Phosphate level metabolism very common in patient with:
 - Scleroderma
 - Dermatomyositis
 - Systemic Lupus Erythematosus
 - Parathyroid gland
 - Trauma induced ⁽¹⁰⁾

Several mechanisms for the pain of Eagle's syndrome have been proposed. These include:

1. Compression of the neural elements, the glossopharyngeal nerve, lower branch of the trigeminal nerve, and/or the chorda tympani by the elongated styloid process ⁽¹¹⁾.

2. Fracture of the ossified stylohyoid ligament, followed by proliferation of granulation tissue that causes pressure on surrounding structures and results in pain ⁽¹²⁾.
3. Impingement on the carotid vessels by the styloid process, producing irritation of the sympathetic nerves in the arterial sheath ⁽¹³⁾.
4. Degenerative and inflammatory changes in the tendonous portion of the stylohyoid insertion, a condition called insertion tendinosis.
5. Irritation of the pharyngeal mucosa by direct compression by the styloid process.
6. Stretching and fibrosis involving the fifth, seventh, ninth and tenth cranial nerves in the post-tonsillectomy period ⁽¹⁴⁾.

Complications of the elongation or fracture styloid process of temporal bone included ⁽¹⁵⁾:

1. Deep space neck infection.
2. Injury to main neurovascular structure.
3. Hemorrhage.
4. Temporary alteration of speech and swallowing.
5. Injury of facial nerve.

Clinical diagnosis

It should be possible to feel an elongated styloid process by careful intraoral palpation, placing the index finger in the tonsillar fossa and applying gentle pressure ⁽¹⁶⁾. If pain is reproduced by palpation and either referred to the ear, face, or head, the diagnosis of an elongated styloid process is very likely ^(17,18).

3D- CT is a valuable diagnostic tool in the diagnosis of Eagle's syndrome because of its ability to facilitate accurate measurement of the length of the styloid process and explain the problem in detail to patients, all of which make this technique superior to conventional imaging ⁽¹⁹⁾.

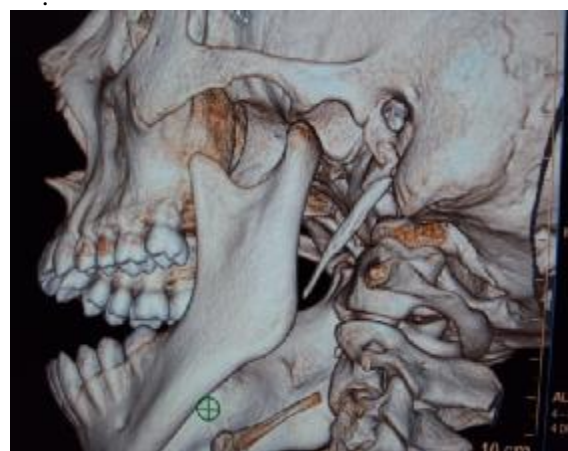
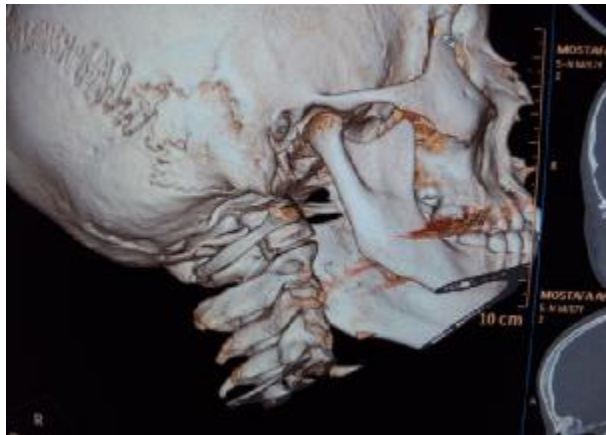
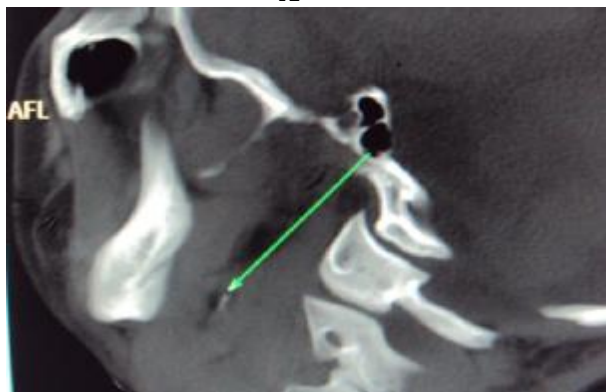Figure 1: Elongation the styloid process of temporal bone



A



B

Figure 2 (A and B): Fractured the styloid process of temporal bone

MATERIALS AND METHOD

One hundred Iraqi patients with symptomatic severe headache and migraine attended Al-Karkh General hospital in 2012. Detailed medical history and clinical examination were performed by specialist.

3D- MDCT is acquired to patient having longer than 30mm styloid process or fractured unilateral or bilateral and analyzed by brain trauma CT with elongation the field downward analysis with volume, coronal, sagittal reconstruction (Figure 3).

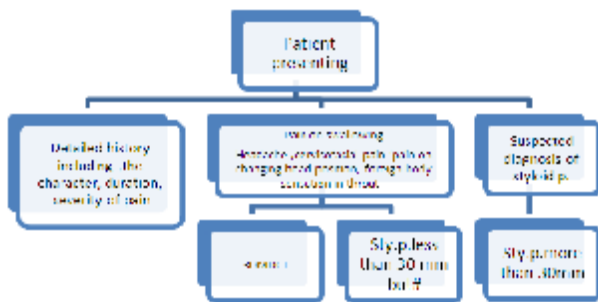

Figure 3: The criteria for selection of the patients

RESULTS

Out of 100 patients examined, 34 patients (25 (74%) females and 9 (26%) males} were diagnosed to have a problem in the styloid process (SP). Seven of them were suffering from elongation of SP while 27 patients had fractured styloid process unilaterally or bilaterally (Stylohyoid ligament ossificant).

Table 1 showed the total age group from 10-60 years. The most age group suffering from Eagle’s syndrome was 31-40 and the less age group was up to 10 years.

Table 2 and Figure 4 revealed the distribution of headache and migraine symptom. The highest percentage was Eagle’s syndrome which formed 34% from total patients suffering from ENT, cervical vertebra and other causes of craniofacial pain which causes headache and migraine. ENT caused only 9% of pain which was the lowest percentage of pain.

Table 1: Total number age groups suffering from styloid process

Age (Years)	Frequency	%
Up to 10ys	3	17.6
11-20	4	11.7
21-30	10	29.4
31-40	12	35.9
41-50	4	11.7
51-60	1	2.9

Table 2: Distribution of the headache and migraine symptoms

Complaints	No. of patient	%
Pain due to ENT problem	9	9%
Pain due to TMJ problem	8	8%
Pain due to cervical vertebra	22	22%
Eagle’s pain	34	34%
Other causes of craniofacial pain	27	27%

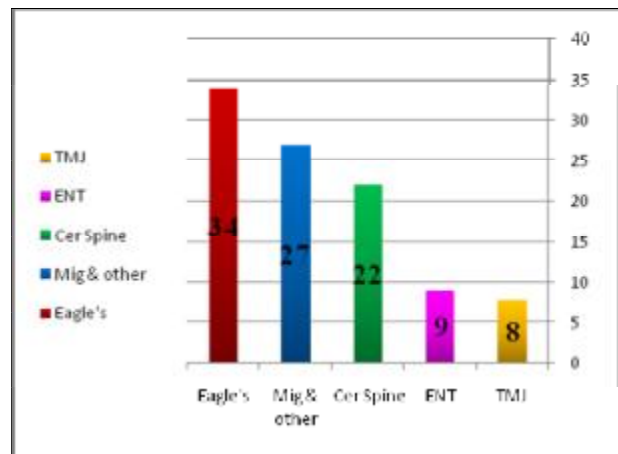


Figure 4: Distribution of the headache and migraine symptoms

DISCUSSION

Eagle's syndrome is an aggregation of symptoms caused by an elongated ossified styloid process and or calcified stylohyoid ligament may be due to fractured of styloid process which can occur unilateral or bilateral. The most common symptom dysphasia, headache, craniofacial or cervical pain⁽²⁰⁾.

The symptomatic elongation of styloid process of temporal bone explained some instances of pharyngeal and ear pains and some headaches and migraine. The main objective in this study was to investigate the real cause of headache which is one of symptoms of Eagle's syndrome in Iraqi people by good medical history and palpation with physical examination for all patients to feel the elongated styloid process with careful intra-oral palpation by placing the index finger in the tonsillar fossa and applying gentle pressure. If pain is reproduced by referred to the ear, face, or head, the diagnosis of an elongated styloid process or ossification of stylohyoid ligament is very likely in this incidence^(17,18).

A styloid process of normal length is usually not palpable. This study found there is elongation either hereditary or due to fracture which may cause ossification of stylohyoid ligament. These cause classical form or vascular one and either unilateral or bilateral. This result agreed with Ceylan *et al.*⁽¹⁵⁾. The syndrome of all patients isolated by brain trauma CT scan multi-detectors with increase the FOV downward then treated by injection of local anesthesia and corticosteroid. 85% of them got remission.

Eagles⁽²²⁾ stated that medical students learned something about the styloid process from the anatomy books and cadaver, but never had opportunity to put this information into clinical application during the latter part of medical school, even current journals, radiologists and maxillofacial radiology seeking for cause of headaches and migraine. Our results agreed with many findings^(3,4,8,13).

The normal SP length is approximately 25-30 mm., this study found that about 7% of examined sample suffering from headache due to elongation of styloid process of temporal bone more than 30 mm. This result agreed with other studies^(23,24).

The result found fracture of styloid process and stylohyoid ligament ossificant causing symptom similar to Eagle's syndrome for patients complain headache and migraine in about 27%; this agreed with Carro and Nunez⁽²⁴⁾.

Guimarães *et al.*⁽²⁵⁾ found that age 41-50 years was the more age of suffering from Eagle's syndrome while the present study found that age 31-40 years, as in table 1, is more for complain of

headache due to Eagle's syndrome and fractured of styloid process of temporal bone.

Headache is one of the symptoms associated with Eagle's syndrome of styloid process in about 34% of the cases as in figure 4. This comes in agreement with Chourdia⁽²⁶⁾. Females more affected than males, 25 females versus 9 males; this result agreed with Karam and Koussa⁽²⁷⁾ and Orhan and Güldikes⁽²⁸⁾.

All of the patients examined by 3D-CT brain trauma by elongation the field of view downward. This is a valuable diagnostic imaging tool in patients with Eagle's syndrome that allows clinicians to evaluate the styloid process in spatial geometry, makes accurate length measurements, and explains the problem in detail to patients. All of which make this technique superior to conventional imaging modalities this agreement with Savranlar *et al.*⁽¹⁹⁾.

In conclusions, headache and migraine are one of the important symptoms in Iraqi people caused by fractured or elongation of the styloid process of temporal bone and 3-D MDCT with brain trauma view and elongated field of view downward is more accurate and superior imaging modality for diagnosis headache.

REFERENCES

1. Eagle W. Elongated styloid process: report of two cases. *Arch Otolaryngol* 1937; 25: 584-7.
2. Baddour HM, McAnear JT, Tilson HB. Eagle's syndrome. Report of a case. *Oral Surg Oral Med Oral Pathol* 1978; 46: 486-94.
3. Mortellaro C, Biancucci P, Picciolo G, Vercellino V. Eagle's syndrome: importance of a corrected diagnosis and adequate surgical treatment. *J Craniofac Surg* 2002; 13: 755-8.
4. Strauss M, Zohar Y, Laurian N. Elongated styloid process syndrome: intraoral versus external approach for styloid surgery. *Laryngoscope* 1985; 95: 976-9.
5. Lengelé BG, Dhem AJ. Length of the styloid process of the temporal bone. *Arch Otolaryngol Head Neck Surg* 1988; 114: 1003-6.
6. McCorkell SJ. Fracture of the styloid process and stylohyoid ligament: an uncommon injury. *J Trauma* 1985; 25: 1010-2.
7. Shankland WE 2nd. Anterior throat pain syndromes: causes for undiagnosed craniofacial pain. *Cranio* 2010; 28: 50-9.
8. Monsour PAJ, Young WG, Barnes PB. Styloid-stylohyoid syndrome: a clinical update. *Aust Dent J* 1985; 30: 341-5.
9. WWW.rightdiagnosis.com, RD medical, Elongation styloid 2012.
10. Gokce C, Sisman Y, Sipahioğlu M. Styloid process elongation or Eagles syndrome: is there any role for ectopic calcification. *Eur J Dent* 2008; 2: 224-8.
11. Guérin AP, London GM, Marchais SJ, Metivier F. Arterial stiffening and vascular calcifications in end-stage renal disease. *Nephrol Dial Transplant* 2000; 15: 1014-21.

12. Stylalgia HR. Clinical experience of 52 cases. *Acta Otolaryngol* 1967; 224:149-155.
13. Balasubramanian S. The ossification of the stylohyoid ligament and its relation to facial pain. *Br Dent J* 1964; 116: 108–111.
14. Balbuena L Jr, Hayes D, Ramirez SG, Johnson R. Eagle's syndrome (elongated styloid process). *South Med J* 1997; 90: 331-4.
15. Ceylan A, Köybaşıoğlu A, Çelenk F, Yılmaz O, Uslu S. Surgical treatment of elongated styloid process: Experience of 61 cases. *Skull base* 2008; 18: 289-95.
16. Montalbetti L, Ferrandi D, Pergami P, Savoldi F. Elongated styloid process and Eagle's syndrome. *Cephalalgia* 1995; 15: 80-93.
17. Mendelsohn AH, Berke GS, Chhetri DK. Heterogeneity in the clinical presentation of Eagle's syndrome. *Otolaryngol Head Neck Surg* 2006; 134: 389-93.
18. Woolery WA. The diagnostic challenge of styloid elongation (Eagle's syndrome). *J Am Osteopath Assoc* 1990; 90: 88-89.
19. Savranlar A, Uzun L, Ugur MB, Ozer T. Three-dimensional CT of Eagle's syndrome. *Diagn Interv Radiol* 2005; 11: 206-9.
20. Kumar SS, Kukkady MA, Deena A, Ayad AAE. Role of three-dimensional computed tomography imaging in Eagles syndrome. *Int J Radiol* 2007; 7(2): DOI: 10.5580/d0b.
21. Eagle W. Elongation styloid process: symptoms and treatment. *Arch Otolaryngol* 1958; 64:172-6.
22. www.medhelp.org/posts/Neurology/eagle-syndrome-symptoms 2007.
23. Yetiser S, Gerek M, Ozkaptan Y. Elongated styloid process: diagnostic problems related to symptomatology. *Cranio* 1997; 15: 236-41.
24. Carro LP, Nunez MP. Fracture of the styloid process of the temporal bone. A case report. *Int Orthop* 1995; 19: 359- 60.
25. Guimarães SMR, Carvalho ACP, Guimarães JP, Gomes MB, Cardoso MDM, Reis HN. Prevalence of morphological alterations of the styloid process in patients with temporomandibular joint disorder. *Radiology Bras* 2006; 39: 407-11.
26. Chourdía V. Elongated styloid process (Eagle's syndrome) & severe headache. *Indian J Otolaryngol Head Neck Surg* 2002; 54: 238-41.
27. Karma G, Koussa S. Eagle's syndrome: the role of CT scan with 3D reconstructions. *J Neuroradiol* 2007; 34: 344-5.
28. Orhan KS, GüldikesY, Ural HI, Cakmak A. Elongated styloid process (Eagle's syndrome): literature review and a case report. *Agri* 2005; 17: 23-5.