

The Value Of 3 Tesla Magnetic Resonance Imaging In Assessment Of Clinically Diagnosed Temporomandibular Joint Disorders

Zeinab Ghadhanfer Hammod B.D.S., H.D.D. (1)

Lamia Al – Nakib B.D.S.,M.Sc. (2)

ABSTRACT

Background: Temporomandibular joint disorder (TMD) is a general term that describe a wide variety of conditions that include myogenic pain, internal derangement, arthritic problem, ankylosis of the joint and growth disorders. The aims of study was to evaluate the value of 3 Tesla magnetic resonance imaging in assessment of articular disc position and configuration in patients with temporomandibular joint disorders and to evaluate the correlations of these MRI findings with the clinical signs and symptoms.

Materials and methods: A total forty six (30 study and 16 control) participants aged between 18 and 49 years, were examined according to Helkimo anamnestic index (questionnaire for anamnesis) and clinical dysfunction index scoring criteria which include clinical examinations of the range of mandibular mobility, impaired TMJ function, muscle pain, TMJ pain and pain during mandibular movement.

Results: There is statistically high significant difference between Helkimo anamnestic and clinical dysfunction indices in the cases group (with temporomandibular joint disorders) and controls group with MRI findings of disc position and disc configuration, that as the severity of indices increased, there were progression of disc displacement and disc deformity score and shows positive association expressed by significant probability (p) value.

Conclusion: There is a significant correlation between Helkimo's anamnestic and clinical dysfunction indices and MRI findings in patients with internal derangement of temporomandibular joint.

Key words: TMJ, Helkimo indices, 3 T MRI. (J Bagh Coll Dentistry 2017; 29(2):55-60)

INTRODUCTION

Temporomandibular joint (TMJ) dysfunction is a common condition that, according to some studies, affects up to 28% of the population (1). The most frequent structural (as opposed to muscular) cause of TMD are Internal derangement, which involves progressive slipping a displacement of component of temporomandibular joint called the articular disc (2). Internal derangement is defined as a mechanical fault of the joint that interferes with smooth joint function. This is attributed to abnormal interaction of the articular disc, condyle and articular eminence. Associated clinical features include articular pain and articular noises (3). The disc displacement is categorized based on the relation of the disc displacement with mandibular condyle. The displacement can be anterior, anterolateral, anteromedial, lateral, medial and posterior (4). Absence of ionizing radiation as well as excellent depiction and visualization of soft tissue, disc position and morphology, bone marrow changes, and joint effusions are among the advantages of MRI (5,6,7).

(1) M.Sc. student, Oral Diagnosis Department, College of Dentistry, University of Baghdad.

(2) Assistant professor, Oral Diagnosis Department, College of Dentistry, University of Baghdad.

The 3T unit delivers images of better quality as regards evaluability of disc position and shape as compared to 1.5 T MR and thus provides added diagnostic assurance that is critical for therapeutic decisions (8).

In this study 3 Tesla MRI machine was used to evaluate temporomandibular joint in patients with internal derangement of TMJ.

MATERIALS AND METHODS

A prospective study was conducted on 46 patients were attended Oral and Maxillofacial Surgery Department in AL- Yarmouk Teaching Hospital that were referred to clinic of Radiology for MRI from over the period of 5 months (September 2014 - February, 2015). The patients were selected and divided into two groups :

1. Case group thirty patients (18-49) years old (22 females and 8 males) were clinically diagnosed as having internal derangements of temporomandibular joint. All patients complain from pain in preauricular area and muscles of mastication, clicking or crepitation of TMJ, a limitation or deviation in mandibular range of motion, they were again grouped according to severity.

- Control group sixteen participants (18-46) years old (10 females and six males) with normal TMJs.

The patients examined according to Helkimo anamnestic index and clinical dysfunction index scoring criteria of temporomandibular disorders which consists of standardized series of diagnostic tests based on clinical signs and symptoms. The clinical examination was done extra and intra orally

A- Extra oral examination.

1. Determination of the mouth opening without pain and the mouth opening with pain (un-assisted mouth opening). This accomplished by measuring the inter-incisal distance plus the overbite when the patient open his mouth as wide as he could. A general guide for minimum normal mouth opening is 45mm including the overbite.

2- Auscultation the TMJ during opening and closing three times at least to detect the joint sound. clicking, crepitation, luxation or deviation of TMJ.

3- Determination of masticatory muscles and TMJ pain during excursive movement of mandible. Determination of the tender points of muscles by palpating muscles bilaterally the Temporalis muscle, Masseter muscle, Medial pterygoid muscle, Lateral pterygoid muscle, Posterior digastric muscle and Sternocleidomastoid muscle.

4- Examination of TMJ pain and tenderness was done by digital palpating of the joint performed from both lateral and posterior aspect, the finger tips were placed over the lateral aspect of both joints simultaneously while the posterior aspect was reached via the external auditory meatus by small finger forced anteriorly. The patient was instructed to do movement of opening, closing, laterotrusion to the right and left and protrusion, then asked if he experienced pain in one movement or more.

B- Intraoral examination

The first was done by checking the occlusion of teeth, if there was any premature contact, overlapping of upper anterior teeth, deep over bite, also occlusal midline was checked.

MRI was carried out with MRI 3.0 Tesla, Achieva Philips Medical System Nederland B.V. with standard head coil, the patient in a supine position. Bite block were used during open mouth position. The data were collected on 256 × 256 matrix giving a pixel size of 0.60 × 0.57 mm. Proton Density (PD) pblique Sagittal (closed and opened mouth). (TR) =528 miliseconds , (TE) =13

ms , (FOV)=150 mm, flip angle =90° , number of slices =22 slice and slice thickness=2.0 mm.

RESULTS

A significant differences in correlation between Helkimo anamnestic index (**Ai**) and MRI findings of TMJ disc displacement types and morphology. It was found that when the result of Helkimo anamnestic highest value 84.2 % at **Ai0** (No symptoms from the masticatory index), while lowest value 5.3% the at **Ai2** (TMJ sounds/tiredness in jaws/stiffness in the morning/stiffness on mandibular movements) .At anterior disc displacement with reduction, the highest value 87.1% at **Ai1** ,while the lowest value 12.9% at **Ai2**. At anterior disc displacement without reduction, the highest value 50.0% at **Ai1**, **Ai2**, while the lowest value 0.0% at **Ai0** (Table 1).

There was a very high significant differences in correlation between Helkimo anamnestic index and MRI findings of TMJ disc morphology ($P < 0.001$), with the normal TMJ disc (biconcave), the highest value 72.7% at **Ai0**, while the lowest value 6.8% at **Ai2**. In abnormal (Elongated /folded /posterior thick band) the highest value 68.8% at **Ai1**, while the lowest value 0.0% at **Ai0** (Table 1).

A significant differences in correlation between Helkimo dysfunction index and MRI findings of TMJ disc displacement types and morphology. It was found that when the result of Helkimo clinical dysfunction index (**Di**) and the normal TMJ disc, the highest value 84.2 % at **Di0** (Clinically asymptomatic), while lowest value 2.6% at **Di2** (Middle dysfunction) and **Di3** (Strong dysfunction). At anterior disc displacement with reduction, the highest value 74.2% at **Di2** , while the lowest value 9.7% at **Di1** (Small dysfunction). At anterior disc displacement without reduction the highest value 72.7% at **Di3**, while the lowest value 4.5% at **Di1** (Figure1).

There was a very high significant differences in correlation between Helkimo clinical dysfunction Index and MRI findings of TMJ disc morphology ($P < 0.001$), with the normal TMJ disc (biconcave), the highest value 72.7% at **Di0**, while the lowest value 4.5% at **Di3**. In abnormal (elongated/ folded/ posterior thick band) the highest value 50.0% at **Di2**, while the lowest value 0.0% at **Di0** (Figure2).

Table 1: Correlation between Helkimo anamnestic index and MRI findings of TMJ disc displacement types and disc morphology.

	Helkimo anamnestic index										Mean rank	P
	Ai0		Ai1		Ai2		Total		Median			
	N	%	N	%	N	%	N	%				
Type of disc displacement												<0.001
Normal	32	84.2	4	10.5	2	5.3	38	100.0	Ai0	23.9		
Anterior disc displacement with reduction	0	0.0	27	87.1	4	12.9	31	100.0	Ai1	57.3		
Anterior disc displacement without reduction	0	0.0	11	50.0	11	50.0	22	100.0	Ai1	68.3		
Abnormal disc morphology												<0.001
Normal (Biconcave)	32	72.7	9	20.5	3	6.8	44	100.0	Ai0	28.6		
Abnormal (Elongated/folded/posterior thick band)	0	0.0	33	68.8	15	31.3	48	100.0	Ai1	62.9		

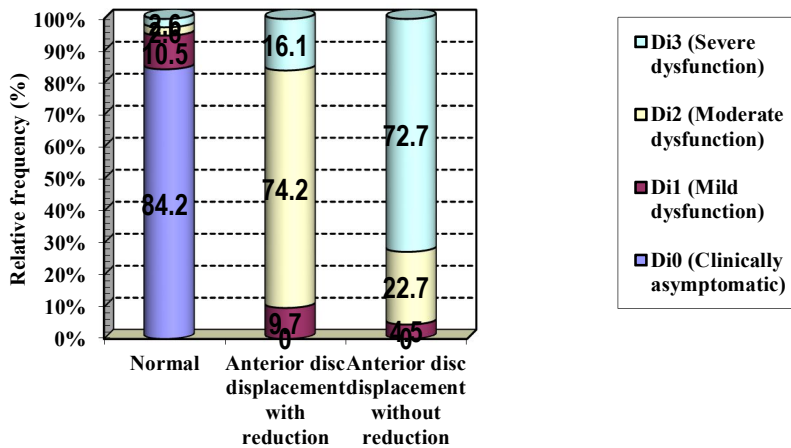


Figure 1: Correlation between Helkimo clinical dysfunction index and MRI findings of type of disc displacement.

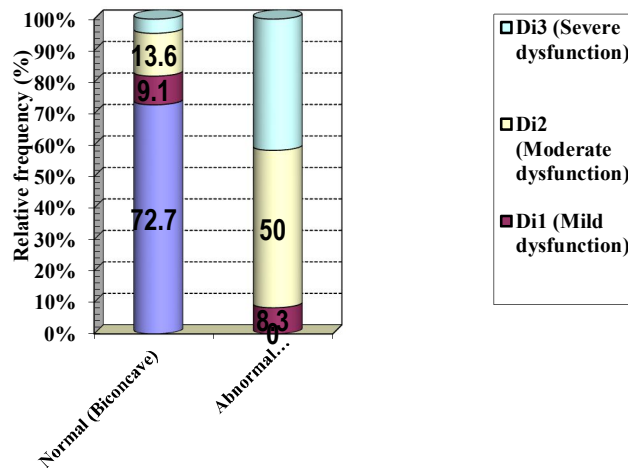


Figure 2: Correlation between Helkimo clinical dysfunction index and MRI findings of disc morphology.

DISCUSSION

In present study the correlation analysis between Helkimo anamnestic index and MRI findings of TMJ disc displacement types and morphology showed positive association expressed by significant difference, these findings were in agreement with that reported by Hasan and Abdelrahman⁽⁹⁾. A very high significant difference in correlation between Helkimo anamnestic index and the normal TMJ disc ($P < 0.001$), these findings were in agreement with that reported by Sano and Westesson⁽¹⁰⁾; Emshoff *et al.*⁽¹¹⁾; Tognini *et al.*⁽¹²⁾. These findings were in disagreement with that reported by Ribeiro *et al.*⁽¹³⁾ because they said 'Disc displacement is relatively common in asymptomatic individuals'. Moreover, arthroscopy and MRI have shown that TMJs with anteriorly disc displacement have the capacity to form remodelled retrodiscal tissue that resembles cartilage (i.e., pseudo-disc formation)⁽¹⁴⁾. Furthermore, the retrodiscal tissues have adaptive capacity and often respond appropriately to the functional loads placed on the tissues⁽¹⁵⁾. These findings were in disagreement with that reported by Muhtarogullari *et al.*⁽¹⁶⁾ because they said 'the clinical diagnosis of no temporomandibular disorder is linked to the high rates of internal derangement detection using MRI'. Maizlin *et al.*⁽¹⁵⁾ assessed that only findings of internal derangement in the TMJ; and did not evaluate other findings of articular pathology that might have explained symptoms in joints that lacked internal derangement. However, this focused assessment was in keeping with the objective to focus on the correlation between clinical findings and disc displacement. A prospective controlled study will be required for more detailed evaluation of the correlation between MRI findings and clinical symptoms⁽¹⁵⁾. Joint noises are not sufficient evidence of dysfunction when there are no other corroborating symptoms, although they may be found in patients with TMJ disc displacement detected using MRI⁽¹⁷⁾. disc displacements in TMJ are considered to be factors which may lead to disc deformities, osseous changes and clinical symptoms of temporomandibular disorders^(18, 19, 20, 21, 22). A statistically significant correlation between an increased signal on T2-weighted images in the posterior disc attachment and the presence of pain⁽¹⁰⁾. A very high significant difference in correlation between Helkimo anamnestic index and MRI findings of TMJ disc morphology ($P < 0.001$), these findings were in agreement with that reported by Emshoff *et al.*⁽¹¹⁾, Kobs *et al.*⁽²³⁾. These findings

were in disagreement with that reported by Arayasantiparb *et al.*⁽²⁴⁾ because they found no significant relationship between the onset of TMJ symptoms and the disc configuration at either closed or open mouth position as well as the transformation of disc shape from closed to open position. This may be due to the lack of complete data on onset of symptoms for this study. Kobs *et al.*⁽²³⁾ agreed with Westesson opinion, that if a patient presents with symptoms that can be correlated to the morphologic abnormality diagnosed on imaging studies, the abnormalities are probably responsible for these symptoms.

In present study the correlation analysis between Helkimo clinical dysfunction index and MRI findings of TMJ disc displacement types and morphology showed positive association expressed by significant difference, these findings were in agreement with that reported by Saeed⁽²⁵⁾, Hasan and Abdelrahman⁽⁹⁾, Imanimoghaddam *et al.*⁽²⁶⁾. These findings were in disagreement with that reported by Aidar *et al.*⁽²⁷⁾ because of they were assessed 'There is a low correlation between MRI disc displacement detections and the extent of TMJ pain and dysfunction'. Anterior disc displacement is a common finding in TMJ internal derangement. The results show a direct relationship between the degree of anterior disc displacement and MRI findings of other TMJ soft tissues and bone abnormalities as well as the severity of clinical manifestations, so early MRI detection and reporting of anterior disc displacement degree and other MRI findings might help clinicians in full assessment and determining the strategy of management of TMJ dysfunction⁽⁹⁾. A very high significant difference in correlation between Helkimo clinical dysfunction index and the normal TMJ disc ($P < 0.001$). The MRI is a modality of choice for diagnosis of TMJ disc displacement as warranted and supplementary method to clinical examination for confirming the presence or absence of TMJ disc displacement⁽²⁸⁾. A very high significant difference in correlation between Helkimo clinical dysfunction index and MRI findings of TMJ disc morphology, these findings were in agreement with that reported by Sato *et al.*⁽²⁹⁾, Saeed⁽²⁵⁾, Hirata *et al.*⁽³⁰⁾, Imanimoghaddam *et al.*⁽²⁶⁾. Hirata *et al.* (2007) stated that "We agree with Sato *et al.*⁽²⁹⁾, who examined the disc position and its configuration changes. They demonstrated that, in cases of disc displacement, mandible head mobility increased with time, although its configuration did not change; consequently, there

would be a more anterior displacement according to its larger deformity. In our study, the more anterior position of the posterior band was associated with greater alteration of disc configuration, when compared with a more superior position of the mandible head. We suggest that the capacity to reduce is more directly related to alterations in disc shape”.

REFERENCES

1. Rawlani Shivlal, Rawlani Shobha, Molwani Mukta, Degwekar Shiris, Bhowle Rahul, Baheti Rakhi. Imaging Modality for Temporomandibular Joint Disorder. JDMIMSU. 2013;VOL.5 No.2.
2. Devaraj Sharmila devi, Pradeep D. Internal Derangement of Temporomandibular Joint. Journal of Dental and Medical Sciences. Mar. 2014; Volume 13, Issue 3 Ver. II.
3. Rudisch A, Innerhofer K, Bertram S, Emshoff R. Magnetic resonance imaging findings of internal derangement and effusion in patients with unilateral temporomandibular joint pain. Oral Surg Oral Med Oral Pathol Oral Radiol Endod. Nov 2001; 92(5):566-71.
4. Tasaki MM, Westesson P-L, Isberg AM, Yan-Fang R, Tallents RH. Classification and prevalence of temporomandibular joint disk displacement in patients and symptom-free volunteers. Am J Orthod Dentofacial Orthop. 1996; 109:249.
5. Piehslinger E, Schimmerl S, Celar A, Crowley C, Imhof H. Comparison of magnetic resonance tomography with computerized axiography in diagnosis of temporomandibular joint disorders. J Oral Maxillofac Surg. 1995; 24:13-19.
6. Sonnabend E, Benz C. Röntgentechnik in der Zahnheilkunde. Urban & Schwarzenberg. München. 1997.
7. Puelacher W. Funktionelle Kiefergelenkschirurgie. In: Schroll K, Watzek G (eds) Zahnärztliche Chirurgie, Band III. Verlag Wilhelm Maudrich, Wien, 1998; pp 167-207.
8. Schmid-Schwab Martina, Drahanowsky Wolfgang, Bristela Margit, Kundi Michael, Piehslinger Eva and Robinson Soraya. Diagnosis of temporomandibular dysfunction syndrome—image quality at 1.5 and 3.0 Tesla magnetic resonance imaging. Eur Radiol. 2009; 19: 1239-1245.
9. Hasan Nahla Mohamed Ali, Abdelrahman Tarek Elsayed Ftohy. MRI evaluation of TMJ internal derangement: Degree of anterior disc displacement correlated with other TMJ soft tissue and osseous abnormalities. The Egyptian Journal of Radiology and Nuclear Medicine. 2014; 45, 735-744.
10. Sano T, Westesson PL. Internal derangement related to osteoarthritis in temporomandibular joint: Increased T2 signal in the retrodiskal tissue in painful joints. Oral Surg Oral Med Oral Pathol Oral Radiol Endod. 1995; 79:511-516.
11. Emshoff R, Brandlmaier I, Gerhard S, et al. Magnetic resonance imaging predictors of temporomandibular joint pain. J Am Dent Assoc. 2003;134:705-714.
12. Tognini F et al. Is clinical assessment valid for the diagnosis of TMJ disc displacement? Minerva Stomatol 2004; 53 (7-8);439-471.
13. Ribeiro RF, Tallents RH, Katzberg RW, Murphy WC, Moss ME, Magalhaes AC et al. The prevalence of disc displacement in symptomatic and asymptomatic volunteers aged 6 to 25 years. J Orofacial Pain: 1997; 11:37.
14. Barkin S, Weinberg S. Internal derangements of the temporomandibular joint: the role of arthroscopic surgery and arthrocentesis. J Can Dent Assoc. 2000; 66(4):199-203.
15. Maizlin Zeev V., Nutiu Nicoleta, Dent Peter B., Vos Patrick M., Fenton David M., Kirby John M., Vora Parag, Gillies Jean H., and Clement Jason J. Displacement of the Temporomandibular Joint Disk: Correlation Between Clinical Findings and MRI Characteristics. J Can Dent Assoc 2010;76:a3.
16. Muhtarogullari M, Ertan AA, Demiralp B, Canay S. Correlation between clinical and magnetic resonance imaging findings in the treatment of anterior disc displacement. J Prosthodont 2013;26:138-142.
17. Manfredini D, Basso D, Salmaso L, Guarda-Nardini L. Temporomandibular joint click sound and magnetic resonance-depicted disk position: which relationship? J Dent 2008;36:256-260.
18. Westesson PL. Structural hard-tissue changes in temporomandibular joints with internal derangement. Oral Surg Oral Med Oral Pathol. 1985; 59 (2), 220-4.
19. Farrar WB, McCarty WL Jr. Inferior joint space arthrography and characteristics of condylar paths in internal derangements of the TMJ. J Prosthet Dent. 1979; 41(5):548-55.
20. Katzberg RW, Westesson P-L, Tallents RH, Drake CM: Orthodontics and temporomandibular joint internal derangement. Am J Orthod Dentofacial Orthop. 1996; 109:515.
21. Yoshida H, Hirohata H, Onizawa K, Niitsu M, Itai Y. Flexure deformation of the temporomandibular joint disk in pseudodynamic magnetic resonance images. Oral Surg Oral Med Oral Pathol Oral Radiol Endod. 2000; 89(1):104-11.
22. Bertram S, Rudisch A, Innerhofer K, Pumpel E, Grubwieser G, Emshoff R. Diagnosing TMJ internal derangement and osteoarthritis with magnetic resonance imaging. J Am Dent Assoc. 2001; 132(6):753-61.
23. Kobs Giedre, Bernhardt Olaf, Kocher Thomas, Meyer Georg. Magnetic Resonance Imaging Findings of the Temporomandibular Joint Internal Derangement in a Non-patient Population. Stomatologija, Baltic Dental and Maxillofacial Journal. 2004; 6:99-102.
24. Arayasantiparb Raweevan, Tsuchimochi Makoto, Mitirattanukul Somsak. Transformation of temporomandibular joint disc configuration in internal derangement patients using magnetic resonance imaging. Oral Science International J. November 2012; Volume 9, Issue 2, Pages 43-48.
25. Saeed Shahrazaad Sami. Correlation between Clinical Features & MRI Findings in Patients with Internal Derangement of Temporomandibular Joint. unpublished

- M.Sc. Thesis, College of Dentistry , University of Baghdad. 2005.
26. Imanimoghaddam Mahrokh, Madani Azam Sadat, Hashemi Elahe Mahmoudi. MRI Findings in Patients with TMJ Click. JDMT, March 2014; Volume 3, Number 1.
27. Aidar uís Antônio de Arruda, Abrahão Márcio Yamashita, Hélio K., Dominguez Gladys Cristina. Morphological Changes of Condyles and Helkimo Clinical Dysfunction Index in Patients Treated with Herbst - Orthodontic Appliance. Braz. Dent. J. July/Aug. 2013; vol.24 no.4 :313-21.
28. Ali Fakhri Abid, Abdul-Raheem Yousif and Al-Rubayee Mehdi Abdul Hadi. Orthodontic Treatment and Temporomandibular Joint Condylar Position Relationship with Disk Displacement (Magnetic Resonance Imaging Study). MDJ. 2008; Vol.:5 No.:2.
29. Sato S, Sakamoto M, Kawamura H, Motegi K. Long-term changes in clinical signs and symptoms and disc position and morphology in patients with nonreducing disc displacement in the temporomandibular joint. J Oral Maxillofac Surg. 1999;57(1):23-9.
30. Hirata Fabio Henrique, Guimarães Antônio Sérgio, Oliveira Jefferson Xavier de, Moreira Carla Ruffeil, Ferreira Evangelo Tadeu Terra and Cavalcanti Marcelo Gusmão Paraiso. Evaluation of TMJ articular eminence morphology and disc patterns in patients with disc displacement in MRI. Braz Oral Res. 2007;21(3):265-7

المستخلص

الخلفية : الاضطراب الصدغي المشترك هو مصطلح عام يصف مجموعة واسعة من الظروف التي تشمل ألم العضلي، الاضطراب الداخلي للمفصل، مشكلة التهاب المفاصل، قسط المفصل و اضطرابات النمو.

اهداف الدراسة كانت تقييم دقة التشخيص باستخدام الرنين المغناطيسي (3 Tesla) في تقييم موقع القرص المفصلي والتكوين في مراسم مختلفة للمفصل الفكي الصدغي في المرضى الذين يعانون من اضطرابات المفصل الصدغي وعلاقتها مع العلامات السريرية والأعراض.

المواد وطريقة العمل : ستة و أربعين مشارك (ثلاثون مريض يعانون من اضطراب المفصل الفكي الصدغي و ستة عشر متطوع سليمي المفصل لغرض المقارنة) تتراوح اعمارهم بين ثمانية عشر وتسعة و اربعون عاما، تم اختيارهم لهذه الدراسة. تم فحص المشاركين سريريا وفقا لمؤشر هلكيمو (الأدكار) (استبيان الأدكار) و مؤشر معيار الخلل الوظيفي السريري والتي تشمل الفحوصات السريرية للمجموعة معدل حركة الفك السفلي، اختلال وظائف المفصل الفكي الصدغي، ألم العضلات، وآلام المفصل الفكي الصدغي والألم أثناء حركة الفك.

النتائج: هناك فرقا إحصائيا كبيرا بين ارتفاع مؤشرات هلكيمو الأدكار والخلل الوظيفي السريري بين مجموعة الذين يعانون من اضطرابات المفصل الصدغي الفكي ومجموعة سليمي المفاصل عندما تقارن مع نتائج التصوير بالرنين المغناطيسي (موقف وتكوين القرص) فكلما شدة المؤشرات زادت، كانت هناك تطور نزوح القرص ودرجة تشوه القرص وتتمثل العلاقة الإيجابية باستخدام عامل التحسس الملموس (P value).

الاستنتاج : توضح هذه الدراسة أن هناك ارتباط كبير بين مؤشرات هلكيمو الأدكار والخلل الوظيفي السريري و نتائج تصوير الرنين المغناطيسي (3 Tesla) للمرضى الذين يعانون من الاضطراب الداخلي للمفصل الصدغي.

