

# Immunohistochemical expression of Fas/Fasligand and c-Myc in oral lichen planus

*Abdul-Razzaq A.M. Wahhab, B.D.S*<sup>(1)</sup>  
*Riyadh O. Alkaisi, B.D.S., M.Sc., Ph.D.*<sup>(2)</sup>

## ABSTARCT

**Background:** Oral Lichen Planus is a chronic inflammatory mucosal disease, presenting in various clinical forms .Both antigen-specific and non-specific mechanisms involved in the pathogenesis of OLP. Apoptosis or programmed-cell death is a physiological process essential for the normal development and maintenance of homeostasis in many organisms. Fas is a cell-surface glycoprotein, 40-kDa, that belongs to the nerve growth factor / tumor necrosis factor (TNF) receptor family. Fas is expressed in several tissues including blood, where its expression is upregulated on activated T and B lymphocytes and natural killer cells. Fas ligand is a type II transmembrane protein that belongs to the tumor necrosis factor family. The proto-oncogene c-Myc is a transcription factor with roles in cellular proliferation, differentiation, apoptosis and cell cycle progression. Mutation in the c-Myc gene and protein over-expression has been associated with a variety of hematopoietic tumors, leukemias and lymphomas. Apoptosis is the mechanism that would be dysregulated in this disease. This study was conducted to evaluate the expression of Fas, FasL and c-Myc in oral lichen planus and to correlate the expression of either markers with each other.

**Materials and Methods:** This study was performed on thirty formalin- fixed paraffin-embedded tissue blocks of oral lichen planus pro and retrospectively. An immunohistochemical staining was done by using monoclonal antibodies for Fas, FasL and c-Myc.

**Results:** Expressions of Fas, FasL and c-Myc were highly detected in keratinocytes and inflammatory cells of OLP cases compared to negative expression in normal oral mucosa. Significant correlation has been found between expression of Fas, FasL and c-Myc in epithelial cells with that of inflammatory cells in oral lichen planus studied cases. Significant correlation has been found among expressions of Fas, FasL and c-Myc in epithelial cells of oral lichen planus cases. Significant positive correlation found between expressions of Fas, FasL and c-Myc in keratinocytes and inflammatory cells of oral lichen planus .

**Conclusion:** Increased expression level of Fas, FasL and c-Myc in both keratinocytes and lymphocytes of OLP cases in comparison to normal mucosa with highly significant correlation among the markers expression indicate their important role in malignant transformation of oral lichen planus.

**Key words:** Oral lichen planus tissue blocks,Fas,FasL and c-Myc tumor markers. (J Bagh Coll Dentistry 2013; 25(1):56-62).

## INTRODUCTION

Oral lichen planus is a relatively common chronic inflammatory disease of oral mucosa with a prevalence rate of 0.5% and 2.2% of the population. Clinically, OLP may assume a variety of morphological changes. The most prevalent type is the reticular form characterized with interlacing white lines that are usually bilaterally distributed on the buccal mucosa and sometimes on the tongue. Other types of OLP are papular, plaque-like, atrophic, erosive and bullous forms. OLP typically affects middle-aged or elderly women, although it can be detected also in younger men, but rarely in children<sup>(1)</sup>.

Associations of OLP with simultaneous presence of lichen lesions in the skin and genital mucosa have been recorded<sup>(1)</sup>.

However the etiology of OLP is still unknown. The previous studies support the view that cell-mediated mechanisms are involved in the initiation and the progression of the disease. Also, localized autoimmunity has been suggested as playing a role in the pathogenesis of OLP.

(1) M.Sc. Student, Department of Oral Diagnosis. College of Dentistry, University of Baghdad.

(2)Professor, Department of Oral Diagnosis, College of Dentistry, University of Baghdad.

Therefore, lacking a known causative factor means there is no specific treatment for OLP<sup>(2)</sup>.

The histopathological of OLP is characterized by a band-like lymphocytic infiltrate in juxtaepithelial lamina propria. In addition, there is hyperkeratinization, acanthosis, liquefaction degeneration of the basal cells, colloid bodies, saw-tooth appearance of rete pegs and distribution of the epithelial basement membrane (BM). Despite these well- characterized histological features of OLP, inter- and intra-observer reproducibility to diagnose OLP is modest<sup>(3)</sup>.

Despite the WHO definition of OLP as a precancerous condition, the premalignant potential of OLP is still debatable. Malignant transformation has been estimated to occur in 0.5 – 2.9% of the OLP patients. Currently, there are no prognostic markers to identify which chronic OLP lesions are at a higher risk for progression. Thus, every OLP patient should be monitored carefully to detect early cancer development<sup>(4)</sup>.

To understand the etiopathogenesis of OLP, it is important to identify the key molecules in this disease. In the present series of studies, molecular markers for cell proliferation, apoptosis, adhesion and inflammatory cell infiltrates have been

studied to characterize the molecular phenotypes of OLP more closely and to estimate their progression toward malignancy<sup>(3)</sup>.

Fas is a member of tumour necrosis factor (TNF) receptor family that is constitutively expressed by a wide range of normal tissues including the breast<sup>(5)</sup>.

Following cross-linking of Fas by its natural ligand, a death signal is generated that catalyses cleavage of the caspase cascade of cysteine proteases, leading to apoptosis<sup>(6)</sup>.

FasL belong to the TNF family of membrane and secreted proteins<sup>(7)</sup>.

FasL expression was first thought to be restricted to the immune system, including activated T and B-lymphocytes and NK cells<sup>(8)</sup>, but has now also been described in sites of immune privilege, such as the eye, testis, uterus and placenta<sup>(9)</sup>.

c-Myc is a transcription factor with roles in cellular proliferation, transformation and implicated in the induction of programmed cell death (apoptosis) with aberrant expression of this gene has been linked to the development and progression of OLP, mutations in the gene and protein over-expression have been associated with a variety of hematopoietic tumors, leukemias and lymphomas.

The c-Myc gene is transcribed to three major transcripts that start from different initiating sites, yielding three major proteins named c-Myc1, c-Myc2 and c-MycS<sup>(10)</sup>.

c-Myc2 is an approximately 62-kDa protein that is the major form of the three c-Myc proteins and the one referred to as c-Myc in most studies.

## MATERIALS AND METHODS

### The samples

This study was performed on thirty formalin-fixed paraffin-embedded tissue blocks histologically diagnosed as OLP. Eighteen cases of them were prospectively collected during the year 2010 to 2011 from the histopathological laboratory in surgical specialties Hospital (SSH) and archives of Oral Pathology laboratory of College of Dentistry, Baghdad University. Twelve cases were retrospectively collected randomly from years 2004 till 2009 from the archives of Oral Pathology laboratory of College of Dentistry, Baghdad University during eight months period of collection for all cases. The diagnosis of each case was confirmed by examining the H&E section by two pathologists.

The clinicopathological information regarding age, gender, lesion sites, clinical presentation, lesion size in addition to any other information were obtained from the case sheets presented with the specimens.

### Control samples

#### A. Normal tissue control:

Five samples of normal oral mucosa were obtained from patients needed surgical removal of impacted teeth, then fixed in 10% formalin and finally processed as the test sample.

#### B. Positive tissue control:

A positive tissue control is a specimen shown by previous works and according to the manufacture data sheets to stain specifically the target antigen after exposure to primary antibody. The positive tissues control in this study were:

\*Colon tissue sections used as positive control for Fas, FasL and c-Myc.

#### C. Negative tissue control:

These were prepared by adding PBS to the slides instead of the primary antibodies to any section of the test groups.

### Tissue preparation and staining

A. Samples: All tissue specimens, samples and controls, were fixed in 10% neutral formalin and processed in a routine paraffin blocks.

B. Sectioning: Each formalin-fixed paraffin-embedded tissue block had serial sections were prepared as follows:

1. 4µm thickness sections were mounted on clean glass slides for routine Haematoxylin and Eosin staining (H&E), from each block of the studied sample and the control group for histopathological re-examination.

2. Other 3 sections of 4µm thickness were mounted on positively charged microscopic slides (ESCO, SuperFrost plus/USA) to obtain a greater tissue adherence for immunohistochemistry.

Equipments and materials used under this category were:

- Disposable knives (Sigma/Germany).
- Microtome (Leitz/Germany).
- Ordinary glass slides (Sail brand/China).
- Positively charged microscope slides (ESCO, superFrost plus/USA).
- Water bath (Mettler/Germany).
- Cover slips.

### Immunohistochemistry Materials and Equipments:

#### Monoclonal antibodies:

The detailed information and specification of the monoclonal antibodies employed in the study were shown in ( Appendix I & II & III ).

#### Detection system

USBiological anti Mouse HRP/DAB immunohistochemical detection kit (Catalog No. ab64259) was used. This kit is compatible with mouse IgG primary antibodies. A biotinylated, cross absorbed, and affinity purified secondary anti-mouse IgG is used to detect primary antibody

–antigen complexes adhered to glass slides. (Appendix III).

Reagents within the kit include:

1. Normal serum
2. Biotin
3. Solution A&B.
4. DAB chromogen (0.5 ml)
5. DAB substrate (15 ml)

Materials and reagents used but not supplied with the kit:

Xelene GCC (UK)

- Absolute ethanol Scharlan (European Union).
- Distilled water
- Mounting medium DPX.(Qualikems)
- Mayer's Hemotoxylin.

Instruments & equipments:

- ✓ Positively charged microscopic slides (ESCO, superFrost plus/USA)
- ✓ Micropipette 0.200 µl and tips (Gilson/France).
- ✓ Micropipette 1000 µl and tips (Salmed/Germany).
- ✓ Eppendorf tubes (100-500 µl).
- ✓ Cover slips (Marienfeld/Germany).
- ✓ \*Thermometer and timer.
- ✓ \*Washing bottles.
- ✓ \*Graduated cylinders.
- ✓ \*Glass staining Jars.
- ✓ Slides holders.
- ✓ \*Sensitive balance.
- ✓ Absorbent Wipes.
- ✓ \*Gloves.
- ✓ Hot air oven (Mettler/Germany).
- ✓ Incubator (Mettler/Germany).
- ✓ Filter paper.
- ✓ Litmus paper.
- ✓ Centrifuge (Heidolph/Germany).
- ✓ Electric light microscope.

**Preparation of reagents:**

Dilution of primary antibodies:

Dilution of antibodies was done by using sterile PBS in a concentration according to each data sheet of monoclonal antibodies. Each antibody was tested with several runs as a technical control staining in order to reach the optimum positive run. Fas/FasL and C-myc were diluted into 1/40 concentration for monoclonal antibodies.

**Dilution of DAB solution:**

DAB was prepared by mixing 1ml of (DAB Buffer) with 20µl of (DAB chromogen) in a tube, and then kept in a dark place until used.

**Principles of the Test**

The labeled streptavidin-biotin (LSAB) method utilizes a biotinylated secondary antibody that links primary antibodies to streptavidin-peroxidase conjugate, and by adding the

chromogen substrate, a colorimetric reaction will form at the antigen binding site.

In this method a single primary antibody subsequently is associated with multiple peroxidase molecules, and because of the large enzyme-to antibody ratio, a considerable increase in sensitivity is achieved compared to direct peroxidase-conjugate methods.

DAB (3'-diaminobenzidine tetrahydrochloride) substrate offers the greatest sensitivity in the horse-radish peroxidase enzyme system as a colorimetric chromogen; a brown precipitate will form at the antigen-binding site. (Burmester et al., 2003).

**Immunohistochemical staining procedure (Manufacturer's data sheet) for detection of Fas, FasL and c-Myc:**

The procedure of the IHC assay adapted by this study was carried out in accordance with the manufacturer instructions (US biological).

1. Slide backing: the slides were placed in a vertical position in the hot air oven at 60°C. overnight.

2. Deparaffinization and rehydration: the slides were sequentially immersed in the following solutions:

- Twice in Xylene for 15 minutes each.
- Twice in absolute ethanol for 5 minutes each.
- 95% ethanol for 5 minutes.
- 70% ethanol for 5 minutes.
- Distilled water for 5 minutes.
- Hydrogen peroxide for 30 minutes.
- Distilled water for 5 minutes.
- PBS for 5 minutes.

3. Enough drops of normal serum were added to slides and incubated in humid chamber at 37°C for 30 minutes, Then soaked 2 times one in distilled water and the other one in PBS (5 minutes for each) finally drained and blotted gently.

4. Diluted primary antibody was applied to each slide, incubated in humid chamber at 37°C overnight. Early in the next day the slides were washed in distilled water (5 minutes), then in PBS (5 minutes), finally drained and blotted gently as before.

5. Each drop of biotin was added and incubated humid chamber at 37°C. For 30 minutes, then washed in distilled water and PBS (5 minutes for each) finally drained and blotted gently.

6. At the same time prepare solution A & B were prepared and incubated in humid chamber at 37°C for 30 minutes.

7. Each drop of Solution A&B were added and incubated humid chamber at 37°C For 30 minutes, then washed in distilled water and PBS (5 minutes for each) finally drained and blotted gently.

8. Diluted DAB was applied on tissue (this process was done in dark room) and incubated in humid chamber for 10 minutes at 37°C. Then slides washed carefully in tap water for 5 minutes.

9. The slides were bathed in Hematoxylin counterstain for 1-2 minutes then they were rinsed with tap water for 10 minutes.

10. Dehydration: the slides were dehydrated by immersing them in ethanol and xylene containing jars as follows:

- 70% ethanol for 1 minute.
- 95% ethanol for 1 minute.
- Twice in absolute ethanol for 1 minute each.
- Twice in Xylene for 1 minute.

11. One to two drops of DPX mounting medium were applied to the xylene wet sections and covered with cover slips and left to dry overnight.

#### Evaluation of Immunohistochemistry results:

Positive reading was indicated when cells display a brown cytoplasmic pigmentation staining for Fas, membranous pigmentation staining for FasL and nuclear and cytoplasmic pigmentation staining for c-Myc while negative reading was indicated for absence of immunostaining.

#### Immunohistochemical scoring of Fas/FasL and c-Myc:

The scoring was done under light microscope under 20x objective and because the staining intensity was not uniform among different lesion, we scored the antibodies with the rate of positive cell. In each tissue section five representative fields (area show preserved histopathological appearance of OLP with an average of 1000 cell per case & 200 cells per field).

The Fas, FasL immunoreactivity of positive cells was scored as follows:

- 0: as negative or nonreactive.
- 1: 1%-25% of positive cells.
- 2: 26%-50% of positive cells.
- 3: 51%-75% of positive cells.
- 4: > 75% of positive cells (Murray B, 2000).

The c-Myc immunoreactivity of positive cells was scored as follows:

- 0: as negative or nonreactive.
- 1: 1%-10% of positive cells.
- 2: 11%-50% of positive cells.
- 3: 51%-80% of positive cells.
- 4: >80% of positive cells (M.K.Schmidt, 2007).

#### Statistical Analysis:

Descriptive statistics: Numerical values were used in this study for describing the variables which includes: No. mean, SD for age, Fas, FasL and c-Myc. Categorical variable which includes: sites, grade, gender and clinical presentation were described using no. and percentage.

1. Data concerning the studied characteristics of OLP were described by their mean and frequency of occurrence.

2. Mean were described by their relative standard deviation to indicate variability.

3. Frequency tables were constructed to display the count of occurrence of each characteristic in OLP.

4. Spearman correlation was used to express relative relation between any two ordinal variables. The sign of this correlation indicates the direction of the relationship whether positive or negative between these two variables.

Statistical analysis using SPSS (statistical package for social sciences) V17 (2008) was used and the P-value less than 0.05 was considered significant.

## RESULTS

### Clinico pathological Finding

#### Age and sex distribution in OLP:

In this study the mean age for 30 cases included was (47) years. The age ranged from 19 to 75 years. Cases in the age group of more than 40 years comprise about 63.33% of the samples (19 cases), while 36.66% of the (11) cases were in the age group less than 40 years (Table 1).

**Table 1: Age distribution of the OLP cases.**

Age	No.	%
<40	19	63.33
40>	11	36.66
<b>Total 30 (100%)</b>		

Regarding the sex distribution of the studied samples results showed that 60% (18) cases were males and 32% (12) cases were females. The male to female ratio was 1.5:1. (Table 2).

**Table 2: Sex distribution of the OLP cases.**

Sex	No.	%
Male	18	60
Female	12	40
<b>Total 30 (100%)</b>		

#### Lesion site distribution:

Regarding the lesion site involved by OLP, the most affected site in this study was the buccal mucosa which comprised 76.66% (23 cases), followed by tongue and cheek which comprised 6.66% (2 cases) for each, followed by lips and vermilions and lower residual ridge 3.33% (1 case) for each (Table 3).

**Table 3: Lesion site distribution of the OLP cases**

Lesion site	NO.	%
Buccal mucosa	23	76.66
Tongue	2	6.66
Check	2	6.66
Lower residual ridge	1	3.33
Vermilions	1	3.33
Lips	1	3.33
<b>Total</b>	<b>30 (100%)</b>	

Clinical presentation:

The majority of cases were appeared in the white lesion 76.66% (23 cases), followed by red lesion 20% (6 cases), and yellow brown 3.33% (1 case). (Table 4).

**Table 4: Clinical presentation of OLP cases**

Clinical presentation	No.	%
White lesion	23	76.66
Red lesion	6	20
Yellow brown lesion	1	3.33
<b>Total</b>	<b>30</b>	<b>100%</b>

**Immunohistochemical Evaluation**

**Evaluation of Fas Immunohistochemistry both(Epithelial & Inflammatory):**

The immunohistochemical staining of Fas in keartinocytes was positive in 29 (96.66%) of examined OLP cases, of which 5 cases (16.66%) showed low positive expression, 11 cases (36.66%) showed moderate positive expression, 6 cases (20%) showed high positive expression and 7 cases (23.33%) showed very high positive expression .

Immunostaining of Fas was detected as brown (granular) in the cytoplasm especially of keratinocyte cells. (Figure 1,2).

Fas epithelial expressions for 30 OLP cases were summarized in (Table 5).

**Table 5: Fas expression in Epithelial cells of OLP cases**

Fas expression	NO.	%
Negative	1	3.33
Low positive	5	16.66
Moderate positive	11	36.66
High positive	6	20
Very high positive	7	23.33
<b>Total</b>	<b>30 (100%)</b>	

Concerning the Fas expression in lymphocytes, results of present study revealed positive in 20 (66.66%) examined OLP while 10 cases (33.33%) showed negative expression for Fas. Of positive cases, 6 cases (20%) showed low expression, 7 cases (23.33%) showed moderate expression and


7 cases (23.33%) showed high expression. (Figure 1, 2 and Table 6).

**Table 6: Fas expression in Inflammatory cells of OLP cases**

Fas expression	NO.	%
Negative	10	33.33
Low positive	6	20
Moderate positive	7	23.33
High positive	7	23.33
Very high positive	0	0
<b>Total</b>	<b>30 (100%)</b>	



**Figure 1 :Positive immunostaining of Fas in OLP (20x)**



**Figure 2:Positive immunostaining of Fas in OLP (40x)**

**Evaluation of FasI Immunohistochemistry both (Epithelial & Inflammatory):**

The immunohistochemical staining of FasI epithelial cells of OLP was positive in 29 (96.66%) examined OLP, 4 cases (13.33%) show low positive expression, 3 cases (10%) show moderate positive expression, and 8 cases (26.66%) show high positive expression and 14cases (46.66%) show very high positive expression.

Immunostaining of FasI epithelial was detected as brown (granular) staining in the cytoplasm of keratinocyte cells.Fig (3,4).

FasI epithelial expressions for 30 OLP cases were summarized in (Table 7).

**Table 7: FasI expression in epithelial cells of OLP cases**

FasI expression	NO.	%
Negative	1	3.33
Low positive	4	13.33
Moderate positive	3	10
High positive	8	26.66
Very high positive	14	46.66
<b>Total</b>	<b>30 (100%)</b>	

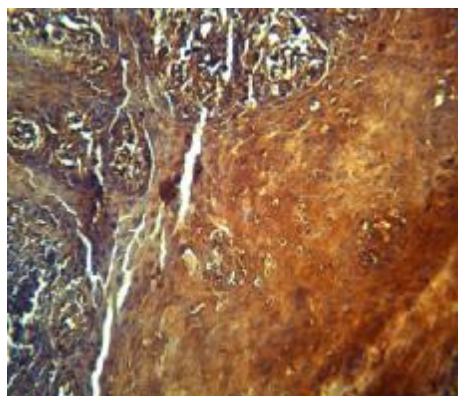
Concerning the immunohistochemical staining of FasI in lymphocytes of OLP cases, results showed positive expression in 29 examined OLP

Immunostaining of fasI was detected as brown (granular) staining in the cytoplasm of inflammatory cells. (Figure 3,4). FasI inflammatory expression for 30 OLP cases was summarized in Table 9.

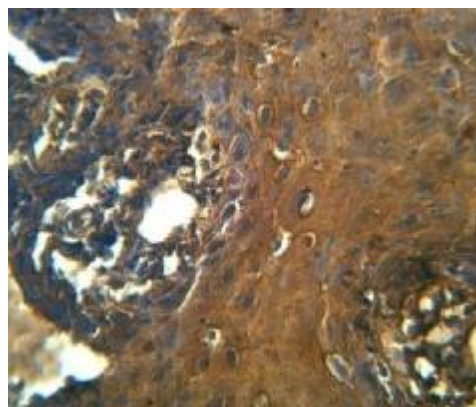
Of 29 (96.66%) positive cases, 5 cases (16.66%) show low positive expression, 8 cases (26.66%) show moderate positive expression, while 16 cases (53.33%) show high positive expression with 1 case (3.33%) showed negative expression.

**Table 8: FasI expression in inflammatory cells of OLP cases**

FasI expression	No.	%
Negative	1	3.33
Low positive	5	16.66
Moderate positive	8	26.66
High positive	16	53.33
Very high positive	0	0
<b>Total</b>	<b>30 (100%)</b>	



**Figure 3: positive immunostaining of FasI in OLP (20x)**



**Figure 4: positive immunostaining of FasI in OLP (40x)**

**Evaluation of c-Myc Immunohistochemistry in(Epithelial & Inflammatory) of OLP:**

The immunohistochemical staining of c-Myc in epithelial cells of OLP was positive in 29 (96.66%) examined cases. Of which 2 case (6.66%) show low expression, while 6 cases (20%) show moderate expression, 8 cases (26.66%) show high expression and 13 cases (43.33%) show very high expression. (Table 9).

Immunostaining of c-Myc was detected as brown (granular) staining in the cytoplasm and nucleus of keratinocyte cells. Fig (5,6).

**Table 9: c-Myc expression in epithelial cells of OLP cases**

C-Myc expression	NO.	%
Negative	1	3.33
Low	2	6.66
Moderat	6	20
High	8	26.66
Very high	13	43.33
<b>Total</b>	<b>30</b>	<b>100%</b>

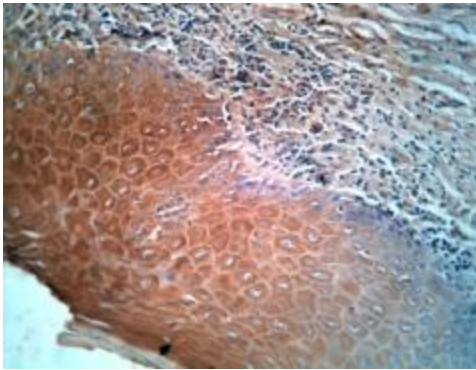
Concerning the immunohistochemical expression of c-Myc in inflammatory cells of OLP was positive in 29 (96.66%) examined cases of which 2 case (6.66%) show low expression, 7 cases (23.33%) show moderate expression, while 7 cases (23.33%) show high expression and 13 cases (43.33%) show very high expression.

**Table 10: c-Myc expression in inflammatory cells of OLP cases**

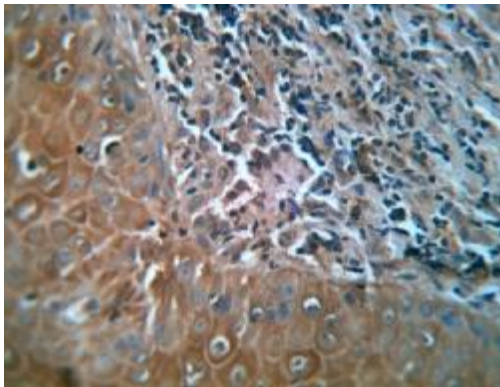
c-Myc expression	NO.	%
Negative	1	3.33
Low	2	6.66
Moderate	7	23.33
High	7	23.33
Very high	13	43.33
<b>Total</b>	<b>30</b>	<b>100%</b>



Immunostaining of c-Myc was detected as brown (granular) staining in the cytoplasm and nucleus of inflammatory cells. (Table 10 and Figure 5,6).



**Figure 5: Positive immunostaining of c-Myc in OLP (20x)**



**Figure 6: Positive immunostaining of c-Myc in OLP (40x)**

## REFERENCES

1. Brad NW, Carl DDM, Jeery ME. Oral Maxillofacial Pathology 3<sup>rd</sup> ed. Saunders; 2009.
2. Elazebith VL, Brieva J, Schachter M, West LE. Successful treatment of erosive lichen planus with topical Tacro- limus. Arch Dermatol 2001; 137: 142-5.
3. Rikkia M. Molecular markers in oral lichen planus. From the Department of Oral Pathology and Radiology, Institute of Dentistry and Department of Pathology, Institute of Microbiology and Pathology, Faculty of Medicine, University of Turku, 2009.
4. Sugeran PB, Savage NW, Walsh LJ, Zhao ZZ, Zhou XJ, Khan A, Seymour GJ, Bigby M. The pathogenesis of oral lichen planus. Crit Rev Oral Biol Med 2002; 134:350-65.
5. Leithauser F, Dhein J, Mechtersheimer G, et al. Constitutive and induced expression of APO-1, a new member of the nerve growth factor/tumor necrosis factor receptor superfamily, in normal and neoplastic cells. Lab Invest 1993; 69: 415-27.
6. Peter ME, Kischkel FC, Hellbrandt S, et al. CD95 (APO-1/Fas)-associated signalling proteins. Cell Death Differ 1996; 3: 161-70.
7. Nagata S. Apoptosis by death factor. Cell 1997; 88: 355-65.
8. Griffith TS, Bruner T, Fletcher SM, Green DR, Ferguson TA. Fas ligand-induced apoptosis as a mechanism of immune privilege. Science 1995; 270: 1189-92.
9. Hunt JS, Vassmer D, Ferguson TA, Miller L. Fas ligand is positioned in mouse uterus and placenta to prevent trafficking of activated leukocytes between mother and the conceptus. J Immunol 1997; 158: 4122-8.
10. Henriksson M, Luscher B. Proteins of the Myc network: essential regulators of cell growth and differentiation. Advances in Cancer Research 1996; 68: 109-82.