

# Indonesian Journal of Tropical and Infectious Disease

Vol. 8 No. 3 September–December 2020

## Case Report

### Disseminated Tuberculosis Mimicking Lung Cancer with Multiple Bone Metastasis: A Case Report

Laksmi Wulandari<sup>1</sup>, Putri Mega Juwita<sup>2</sup>

<sup>1</sup> Thoracic Oncology Division, Department of Pulmonology and Respiratory Medicine, Faculty of Medicine, Universitas Airlangga-Dr. Soetomo General Hospital, Surabaya 60285, Indonesia

<sup>2</sup> Department of Pulmonology and Respiratory Medicine Faculty of Medicine, Universitas Airlangga-Dr. Soetomo General Hospital, Surabaya 60285, Indonesia

Received: 19<sup>th</sup> February 2020; Revised: 3<sup>rd</sup> September 2020; Accepted: 9<sup>th</sup> September 2020

#### ABSTRACT

Tuberculosis (TB) is a contagious infectious disease caused by *Mycobacterium tuberculosis* (Mtb) of which attacking various organs particularly the lungs. Tuberculosis can occur together with malignancy or manifest as malignancy. Lung tuberculosis may appear in a variety of clinical and radiological manifestations caused by other diseases including tumors. These tumors are called pseudo-tumors. TB pseudo-tumor is a rare manifestation that can occur in immunocompetent patients in both primary and post-primary TB. The clinical presentation of TB pseudo-tumor is nonspecific and the clinical suspicion must be increased to diagnose related diseases. Radiological features can also be challenging to be distinguished from actual tumors. The classic manifestations of pulmonary TB are generally easy to diagnose due to the distinctive clinical and radiological characteristics nonetheless some pulmonary TB symptoms are also often found in patients with lung cancer. Infection patients resemble malignancies most were asymptomatic (> 27%) and the remaining 27% showed symptoms that varied with the average symptoms experienced about 1 month earlier. Clinical presentations that require a lot of misdiagnosis result in delayed treatment and unnecessary procedures. Establishing a diagnosis in cases of tuberculosis that causes malignancy is very important since the management and outcomes of the infection and malignancy process are quite different. Consequently we report a 24-year-old man with tuberculosis possible lung cancer with multiple bone metastase. Extrapulmonary tuberculosis which attacks bones and joints constitutes 10% to 20% of all TB cases. The location of bone and joint TB generally develops in the lumbar or thoracic vertebrae.

**Keywords:** tuberculosis, pseudo-tumour, lung cancer, bone metastasis, extrapulmonary tuberculosis.

#### ABSTRAK

Tuberkulosis (TB) merupakan penyakit infeksi menular yang disebabkan oleh *Mycobacterium tuberculosis* (Mtb) dan dapat menyerang berbagai organ terutama paru. Tuberkulosis dapat terjadi bersamaan dengan keganasan ataupun bermanifestasi menyerupai keganasan. Tuberkulosis paru dapat muncul dalam berbagai manifestasi klinis dan radiologis yang menyerupai penyakit lain termasuk tumor. Lesi berbentuk massa dan menyerupai tumor ini disebut sebagai pseudotumor. Pseudotumor TB merupakan manifestasi langka yang dapat terjadi pada pasien imunokompeten baik pada TB primer maupun post primer. Presentasi klinis dari pseudotumor TB tidak spesifik dan kecurigaan klinis harus ditingkatkan untuk mendiagnosis adanya infeksi tersebut. Gambaran radiologis juga sulit dibedakan dengan tumor sebenarnya. Manifestasi klasik TB paru secara umum mudah didiagnosis karena menunjukkan karakteristik klinis dan radiologis yang khas namun beberapa gejala TB paru juga sering ditemukan pada penderita kanker paru. Pasien infeksi menyerupai keganasan sebagian besar asimtomatis (>27%) dan 27% sisanya menunjukkan gejala yang bervariasi dengan rata-rata gejala yang dialami muncul sekitar 1 bulan sebelumnya. Presentasi klinis yang bervariasi mengakibatkan misdiagnosis yang berakibat pada keterlambatan pengobatan dan prosedur diagnostik yang tidak perlu. Penegakan diagnosis pada kasus tuberkulosis yang menyerupai keganasan merupakan hal yang sangat penting karena manajemen dan luaran dari proses infeksi dan keganasan sangat berbeda. Berikut kami laporkan

\* Corresponding Author:  
laksmi.wulandari@fk.unair.ac.id

*seorang laki-laki berusia 24 tahun dengan tuberculosis yang menyerupai kanker paru dengan metastasis tulang multipel. Tuberculosis ekstraparu yang menyerang tulang dan sendi merupakan 10% hingga 20% dari semua kasus TB. Lokasi TB tulang dan sendi umumnya berkembang pada vertebra regio lumbal atau toraks.*

**Kata kunci:** tuberculosis, pseudotumor, kanker paru, metastasis tulang, tuberculosis ekstraparu.

**How to Cite:** Disseminated Tuberculosis Mimicking Lung Cancer with Multiple Bone Metastasis: A Case Report. Wulandari, L. Juwita, PM. Indonesian Journal of Tropical and Infectious Disease, 8(3), 174–182..v7i6.13454.

## INTRODUCTION

Tuberculosis (TB) is a contagious infectious disease caused by *Mycobacterium tuberculosis* (Mtb), which attacking various organs affected by the lungs.<sup>1</sup> This disease causes 1 in 10 patients in the world and is a cause of disease for patients with Human Immunodeficiency Virus / Acquired Immune Deficiency Syndrome (HIV/AIDS).<sup>2</sup> The highest TB morbidity and mortality are suspended within middle and low revenue countries due to poverty, malnutrition, and low endurance.<sup>3</sup> Indonesia with a population of 264 million people is of the opinion that the number of funds with the highest TB in the world. The World Health Organization (WHO) reports as many as 842,000 people suffering from TB in Indonesia and 116,000 who have died caused by TB.<sup>2</sup>

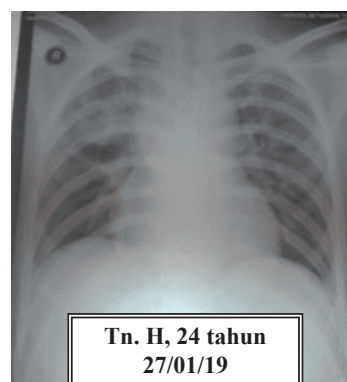
Lung tuberculosis may appear in a variety of clinical and radiological manifestations caused by other diseases including tumors.<sup>4</sup> These tumors are called pseudo-tumors. TB pseudo-tumor is a rare manifestation that can occur in immunocompetent patients in both primary and post-primary TB. Lesions removed from the parenchyma were higher than those in enlarged lymph nodes.<sup>5</sup> The clinical presentation of TB pseudo-tumor is nonspecific and the clinical suspicion must be increased to diagnose related diseases. Radiological features can also be challenging to be distinguished from actual tumors. This may cause late in diagnosis and carried out morbidity among patients.

## CASE REPORT

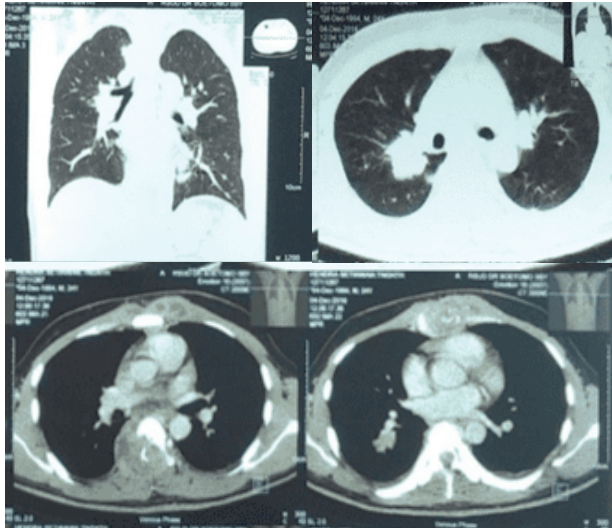
The patient's general condition is quite frail, with blood pressure of 80/50mmHg, tachycardia,

febrile, and pain scale of Wong Baker is 4, anemic conjunctiva and has a mass with  $\text{Ø} \pm 4\text{cm}$  in the parietal region of the region. Reddish wound on the sternum region measuring 2x5cm in size. Lung examination revealed decreased fremitus palpation and faint percussion in 1/3 of the right hemi thorax accompanied by decreased breath sounds. There are 8x9cm pressure sores in the sacrum region, 2x3cm and 3x4cm sizes in the calcaneus regions dextra and sinistra with slough and necrotic tissue. There is inferior paraplegic, hypesthesia as high as the ThX segment, as well as urinary retention.

Laboratory results showed leukocytosis (WBC 19,130), granulocytosis (91.8% neutrophils), increased LDH (253), and CEA 2.93ng/ml (cut off 5ng/ml). The chest radiograph shows an inhomogeneous opacity at 1/3 of the extra hemi thorax (Figure 1). A thoracolumbar MRI (Fig. 7A) shows destruction of the lamina, spinous process, VC pedicle 6.7 accompanied by soft tissue mass bulging and surrounding necrotic areas. Soft tissue mass bulging was also seen in anterior Vth 1-3, destruction of the VTh12 corpus with



**Figure 1.** Result of CT scan thorax during in-patient

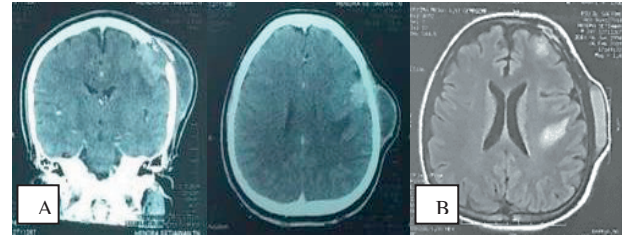


**Figure 2.** Right lung central mass findings that show contrast enhancement on CT scan thorax result

anterior to left lateral paravertebral soft tissue, and destruction of the corpus sternum and spiculated mass of  $\pm 4.9 \times 3.5$  cm in the middle of the right lung. These findings direct the suspicion of a right lung central mass and the process of metastasis.

The CT scan thorax result with contrast supports the image of malignancy by finding (Figure 2) solid lesions (36 HU), indistinct borders, spiculated edges, size  $\pm 3.5 \times 2.6 \times 2.8$  cm in the center of the right lung with contrast enhancement (77 HU), visible Abutting lesions of the superior and inferior branches of the right bronchus.

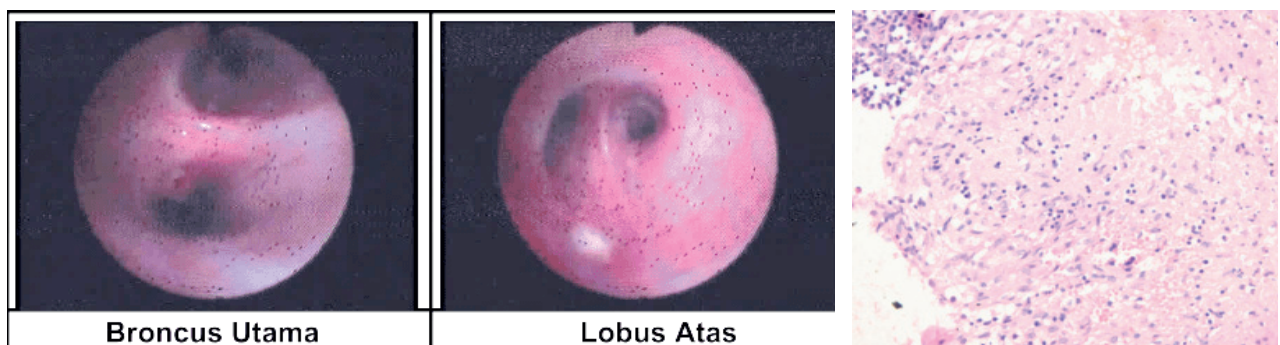
Result of MSCT head showed slight hyperdense (47HU) lesions in the left parietal subdural region with a thickness of  $\pm 1.6$ cm,  $4.7 \times 4.4$ cm wide with a contrast enhancement rim (72HU)



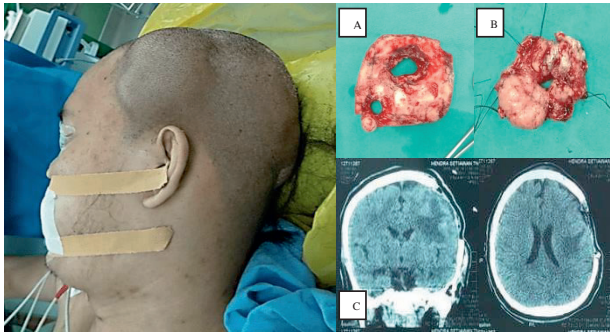
**Figure 3.** A) Result of head MSCT, B) Head MRI, both showing solid lesions in the left parietal subdural region with rim contrast enhancement

which decomposed the left parietal calvarias and formed soft tissue bulging into the extra cranial. Head contrast MRI shows solid, extra axial, firm boundary, irregular margins in the left parietal lobe convex of  $4.4 \times 5.1 \times 6.4$ cm with contrast enhancement rim and perifocal edema around it. MR spectroscopy showed an increase in intralesional Ch/Cr ratio, increased lipid-lactate perillation. Perfusion MR showed an increase in rCBV that did not return to baseline. This feature can be a metastatic process (when compared with previous CT head scans of enlarged lesions and perifocal edema extending), retention cysts in the left frontal sinus (Figure 3).

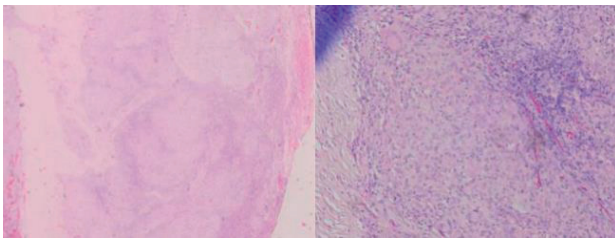
Furthermore, the patient underwent fiber optic bronchoscopy (FOB) as a diagnostic step. The FOB results showed intraluminal mass in the intermediate trunk wall and infiltrative mass in the superior lobe bronchial lumen with BAL cytology results in the right and sinistra, brushing, aspiration biopsy, and forceps biopsy showed no signs of malignancy. Then followed by CT-guiding FNAB examination on the right lung



**Figure 4.** FOB of Mr. H (right) appears intralumen mass of the right superior lobe bronchus; CT-guiding FNAB results (left) show granulomatous inflammation



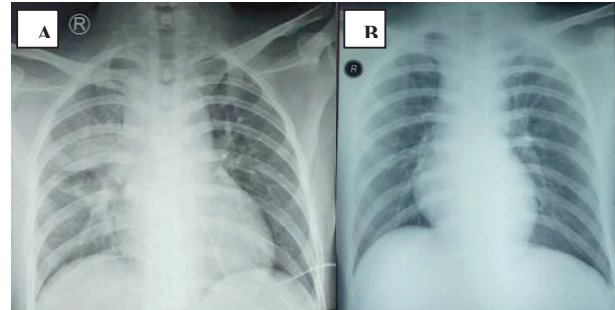
**Figure 5.** Clinical conditions of the left parietal region of the tumor on the patient's head. A) Post resection calvaria tissue, B) Resected tumor tissue, C) CT scan of the head post-operative evaluation



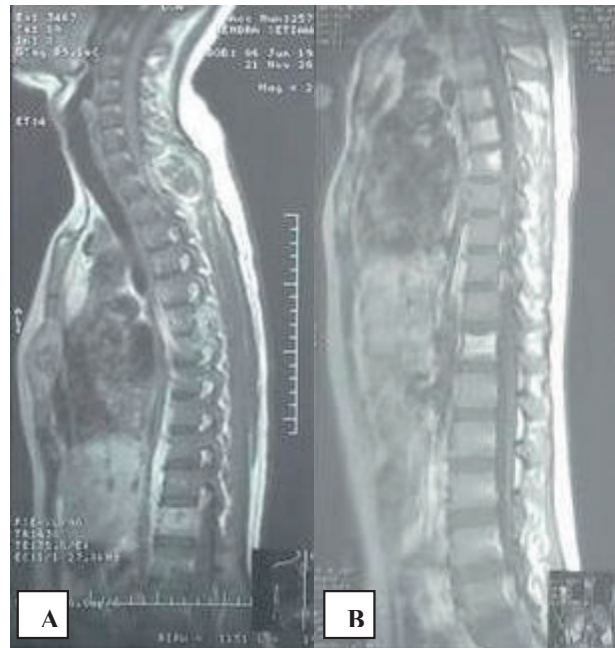**Figure 6.** Histopathological examination of the head tumor showed granulomatous inflammation

obtained granulomatous inflammation according to tuberculosis (Figure 4). Patients were given Anti Tuberculosis (OAT) drugs exjuvantibus category I and then underwent open biopsy of the sternum lesion. Exploration of the operative field revealed a superficial abscess and the drainage of the abscess was carried out with the results of watercolor and culture of the pus sternum without the presence of acid fast bacili (AFB) germs and aerobic germ growth. Pus cytology was not found malignant cells in the same specimen.

Surgical excision of head tumors in patients is performed as a diagnostic and therapeutic step because the results of previous examinations are not conclusive. Exploration of the field of surgery in the left parietal region obtained sub cutis capsules filled with liquid likely cheese porridge under duramater, continue with tumor resection, duraplasty and drainage. Bone is not returned for the purpose of decompression. After the patient's surgery a CT scan of the head is evaluated (Figure 5).



**Figure 7.** Result of thorax images. A) Before diagnosed with TB, B) 5 months after TB treatment.



**Figure 8.** Thoracolumbar MRI: A) Before TB diagnosis, B) 5 months after TB treatment

Tumor resection tissue was examined by rapid molecular tests, AFB smear, culture and Mtb sensitivity test, and histopathology. Molecular rapid test results of pus os parietal obtained low detected Mtb, rifampicin resistant not detected; AFB smear scanty positive; culture and sensitivity test of Mtb negative. Histopathological examination results of calvarias and duramater bone tissue surgery showed granulomatous inflammation and AFB bacteria according to tuberculosis (Figure 6).

Patients also underwent 3 methods of HIV testing with a negative result and a T helper lymphocyte count (absolute CD4) with a result

of 503 cells/ $\mu$ L (normal range 410-1590 cells/ $\mu$ L). The patient was formerly diagnosed with TB and given a Category I OAT plus streptomycin for 2 months then continued with a 10-month follow-up phase.

Evaluation of treatment showed clinical improvements such as weight gain, loss of cough as well as chest and back pain. The postoperative wound dried up and there was sensory and motor repair of the inferior limb. Chest radiographs in the fifth month of treatment showed a picture of inhomogeneous opacity disappearing (Figure 7). Results of thoracolumbar MRI appear soft cervical region soft tissue bulging disappears even though there is still a picture of corpus VTh5, 6, 7 destruction, right-sided transverse process, thoracic cord compression level VTh5-7 accompanied by cord edema and skip lesion in VTh12, compared to previous MRI improvement (Figure 8).

## DISCUSSION

Tuberculosis (TB) is a contagious infectious disease caused by Mtb and can attack various organs especially the lungs.<sup>1</sup> As many as  $\frac{1}{3}$  of the world's population is infected with Mtb, however only 5% to 10% of the population are at risk of developing into TB within 1 or 2 years after infection (primary TB) or after (post-primary TB).<sup>6</sup> TB diagnosis is determined based on objections, history taking, clinical examination, laboratory, and other support. Bacteriological laboratory examination (direct microscopic sputum examination, rapid molecular examination, and culture), radiological examination (x-ray, CT scan, and MRI), histopathological examination, drug sensitivity test, and serological tests also play an important role in the diagnosis of TB.<sup>7</sup>

Tuberculosis manifestations are vary which can sometimes be a challenge for medical doctors to identify this disease.<sup>8</sup> The classic manifestations of pulmonary TB are generally easy to diagnose due to the distinctive clinical and radiological characteristics nonetheless some pulmonary TB symptoms are also often found in patients with lung cancer.<sup>9</sup> Infection patients resemble

malignancies most were asymptomatic ( $> 27\%$ ) and the remaining 27% showed symptoms that varied with the average symptoms experienced about 1 month earlier.<sup>4</sup>

The most common symptoms are coughing, chest pain, and fever. Other symptoms that are less common include weight loss, dyspnea, fatigue, malaise, hemoptysis, and night sweats.<sup>9,10</sup> In this case, the patient presents in a seizure condition, history taking does not show any typical clinical symptoms of pulmonary TB. Initial complaints were severe chest pain when coughing and weakness of both limbs to paralysis so they could not be distinguished from malignancy.

Some patients with pseudo tumor are also accompanied by comorbidities such as old age, diabetes mellitus, alcoholics, and chronic obstructive pulmonary disease, or patients with immunocompromised conditions such as in people with HIV / AIDS or those who undergo such organ transplants.<sup>9,11</sup> These immunocompromised conditions are not found in patient. The incidence of idiopathic lymphocytopenia (low CD4 + T cell levels) is also not found in patients although some studies have shown that low levels can be associated with severe TB infection that is spread.<sup>11</sup>

Data on extrapulmonary TB cases is limited, although the prevalence of extrapulmonary TB cases is reported as 4% to 48% in various countries.<sup>12</sup> Extrapulmonary TB symptoms were according to the location of the organ being attacked. Nonspecific symptoms such as anorexia, fatigue, myalgia, headaches, and neck stiffness, disturbance of consciousness, and behavior changes for about 2-8 weeks can occur in meningitis TB.<sup>7</sup> Patients in the emergency room with complaints of seizures that can also occur in patients with tumor metastases to the brain. The process of metastasis causes disruption of the blood-brain barrier that leads to cerebral edema and increased intracranial pressure.<sup>10</sup>

Tumor markers are one of the diagnostic modalities that are widely used to get rid of cancer from other benign diseases. High levels of tumor markers indicate the presence of cancer. Carcinoembryonic antigen (CEA), cancer antigen (CA) 125, CYFRA 21-1, and SCCAg are tumor

markers that can be used in the diagnosis of non-small cell carcinoma lung cancer (NSCLC), while pro-gastrin-releasing peptide and neuron-specific enolase (NSE) is commonly used in the diagnosis of small cell carcinoma lung cancer (SCLC). However, there are reports that abnormal tumor marker results can also occur in benign diseases including pulmonary TB.<sup>9</sup> The results of CEA in patients are within normal limits so it does not support the direction of malignancy, especially NSCLC.

Radiological features of the chest X-ray of most TB patients resembling malignancy are similar to cancer even though about 20% of cases still allow an infection to be described. The most common radiological features encountered are solitary round nodules (46%), cavities, and lobulated masses. The location of the lesion varies and there is no specific dominant location.<sup>9</sup> Chest X-ray of the patient shows inhomogeneous opacity with irregular edges. This picture does not show the typical characteristics of pulmonary TB so it leads to misdiagnosis.

Malignancy images on CT scans show a variety of morphologies including speculated, lobulated edges, blood vessel convergence signs, pleural indentation, ground-glass opacity, and thick-walled and irregular cavities. In contrast, nodules with smooth edges, bronchus signs, and round shapes are considered benign lesions. However, research shows that pulmonary TB can show one or more features of malignancy. Asymptomatic pulmonary TB patients have a higher frequency of spiculated margins rather than lung cancer.<sup>9</sup> As a result, there is an overlap between pulmonary TB and lung cancer on chest CT images as in the case. The thoracic CT scan of the patient shows solid lesions with indistinct borders, spiculated edges, and contrast enhancement. The lesion also appears to titrate the right bronchus.

Extrapulmonary TB which attacks bones and joints constitutes 10% to 20% of all TB cases.<sup>13</sup> Bone and joint tuberculosis results from hematogenous or primary focal lymphogeneous spread or reactive infection focus. Concurrent active pulmonary TB occurs in only 30% of cases of bone and joint TB.<sup>14,15</sup> The location of bone and joint TB generally develops in the lumbar or

thoracic vertebrae.<sup>14</sup> In this case, in addition to finding a pulmonary pseudotumor, large bone TB is also found in several organs such as the cervical vertebrae, sternum, and calvarias. Diagnosis is difficult because the initial manifestations that are not typical and in advanced conditions can resemble malignancy.<sup>16</sup>

Contrasting thoracolumbar MRI examination in this case shows multiple bone destruction in the vertebrae and sternum and abscess formation in the posterior cervical vertebrae which is rarely found in cases of spondylitis TB. CT scan on spondylitis TB can be found disco-vertebral lesions and paravertebral abscesses and the spread of disease to the soft tissue that is more clearly seen on MRI.<sup>17</sup> Spine MRI for spondylitis TB is preferred because it can detect early marrow and paraspinal soft tissue changes.<sup>18</sup> Typical radiological findings include vertebral end plates thinning, loss of disc height, bone destruction, new bone formation and soft tissue abscesses often involving multiple vertebral involvements, fusion and collapse.<sup>17</sup>

Destruction of the sternum by the formation of abscesses found in patients can be caused by four mechanisms namely thickening of the pleura that causes the spread of TB germs in lymphogen, localized empyema of tuberculosis pleurisy, and spread of TB germs from the thoracic cavity due to medical measures, and hematogenous infiltration due to milier TB. However, the results of AFB smear pus regional sternum in patients gave negative results. Mtb culture two months later also gave negative results. Nonaka et al. reported that the rate of positive AFB in sternal abscess was 35% and the positive culture rate was 60%.<sup>19</sup>

Calvaria involvement within this case is also infrequent. Calvarial TB generally occurs at the age of 11 to 20 years with a ratio of men and women 2:1.<sup>20</sup> Radiological features found in calvarial TB in the form of lesions with clearly defined sclerotic type and lytic type which diffuse into the cranium. Calvarial TB often appears as painful scalp swelling, subgaleal abscess (Pott's puffy tumor), sinus discharging, and extradural granulation tissue. The involvement of isolated skull bones is very rare.<sup>21</sup> As many

as 42% of cases with a history of trauma or previous surgery, 52% with painless swelling accompanied by discharging sinus, and seizures in a small proportion of patients. The presence of granulation tissue in the extradural space can cause focal neurological deficits.<sup>20</sup>

Seizures that occur in patients initially allegedly due to the process of metastasis in the brain due to the effect of mass pressure that results in increased intracranial and meninges involvement. However, postoperative calvaria tissue examination showed rapid molecular test results Mtb detected low, rifampicin resistant not detected; AFB positive scanty smear, and histopathological examination found granulomatous inflammation and smear germ according to tuberculosis. This is the basis for the diagnosis of TB in patients.

Provision of ATD is the main therapy in this case. Some experts recommend giving ATD 9-12 months if there are multiple with vertebral lesions, cervical levels, and neurological deficits that cannot yet be evaluated.<sup>21,22</sup> Patients with calvarial TB are advised to administer ATD 18-24 months and the therapeutic response must be monitored by physical examination, laboratory and radiological.<sup>23</sup> In this case, the patient was given regiment ATD first category plus streptomycin for 2 months of intensive phase and continued with 10 months of advanced phase after seeing the results of evaluation of therapy. This is ended by considering multiple lesions and involvement of the central nervous system. The results of the treatment evaluation showed clinical improvement with weight gain, increased right and left inferior limb muscle strength, sensory improvement, and loss of lesions on chest X-ray and vertebral abscess on thoracolumbar MRI with contrast.

Some studies show better results if ATD is combined with surgery because of the large area of a bone that can be the focus of TB infection. Surgery for calvarial TB is aimed at establishing the diagnosis, removing thick extradural granulation tissue and necrotic bone, and eliminating the effects of mass urgency.<sup>23</sup> Surgery is only performed on large extradural abscesses which result in focal neurological deficits or scalp swelling with sinus formation

and fulminant secondary infection. In some cases, complete excision and extirpation of the sinus tract are recommended.<sup>24</sup> Surgery has also been developed to prevent paralysis due to spondylitis TB. Posterior spinal arthrodesis is currently used to control mechanical instability, prevent kyphosis progression, and correct vertebral deformity in pan vertebra surgery. Ancient conservative therapy with immobilization using corsets and sleeping on hard beds in spondylitis TB is beginning to be abandoned from the time when it gives unsatisfactory results.<sup>25</sup>

## CONCLUSION

TB diagnosis is determined based on objections, history taking, clinical examination, laboratory, and other support. Bacteriological laboratory examination (direct microscopic sputum examination, rapid molecular examination, and culture), radiological examination (X-ray, CT scan, and MRI), histopathological examination, drug sensitivity test, and serological tests also play an important role in the diagnosis of TB.

Tumor markers are one of the diagnostic modalities that are widely used to get rid of cancer from other benign diseases. The results of CEA in patients are within normal limits so it does not support the direction of malignancy, especially NSCLC.

The Chest X-ray of the patient shows inhomogeneous opacity with irregular edges. This picture does not show the typical characteristics of pulmonary TB so it leads to misdiagnosis. Malignancy images on CT scans show a variety of morphologies including speculated, lobulated edges, blood vessel convergence signs, pleural indentation, ground-glass opacity, and thick-walled and irregular cavities. Asymptomatic pulmonary TB patients have a higher frequency of spiculated margins rather than lung cancer. As a result, there is an overlap between pulmonary TB and lung cancer on chest CT images as in the case.

In this case, in addition to finding a pulmonary pseudo tumor, large bone TB is also found in several organs such as the cervical vertebrae,

sternum, and calvarias. Contrasting thoracolumbar MRI examination in this case shows multiple bone destruction in the vertebrae and sternum and abscess formation in the posterior cervical vertebrae which is rarely found in cases of spondylitis TB. The results of AFB smear pus regional sternum in patients gave negative results.

Postoperative calvarial tissue examination showed rapid molecular test results Mtb detected low, rifampicin-resistant not detected; AFB positive scanty smear, and a histopathological examination found granulomatous inflammation and smear germ according to tuberculosis. This is the basis for the diagnosis of tuberculosis in patients.

In this case, the patient was given regiment ATD first category plus streptomycin for 2 months of intensive phase and continued with 10 months of advanced phase after seeing the results of evaluation of therapy. The results of the treatment evaluation showed clinical improvement with weight gain, increased right and left inferior limb muscle strength, sensory improvement, and loss of lesions on chest X-ray and vertebral abscess on thoracolumbar MRI with contrast.

## CONFLICT OF INTEREST

There is no conflict of interest of this study.

## REFERENCES

1. PUSDATIN. Info Datin Kemenkes RI - Tuberculosis: Temukan Obati sampai Sembuh [Internet]. 2015;7. Available from: [http://www.depkes.go.id/download.php?file=download/pusdatin/infodatin/infodatin\\_tb.pdf](http://www.depkes.go.id/download.php?file=download/pusdatin/infodatin/infodatin_tb.pdf)
2. World Health Organization. Global Tuberculosis Report. 2018.
3. World Health Organization. Nutritional Care and Support. 2013;
4. Lang S, Sun J, Wang X, et al. Asymptomatic pulmonary tuberculosis mimicking lung cancer on imaging: A retrospective study. *Exp Ther Med* 2017;14(3):2180–2188.
5. Androulaki A, Papatthomas TG, Liapis G, et al. Inflammatory pseudotumor associated with *Mycobacterium tuberculosis* infection. *Int J Infect Dis* 2008;12(6):607–610.
6. Crevel, Reinout; Ottenhoff, Tom H.M.; van der Meer JWM. Innate Immunity to *Mycobacterium tuberculosis*. *Society* 2005;15(2):294–309.
7. Direktorat Jenderal Pengendalian Penyakit dan Penyehatan Lingkungan KKRI. Pedoman Nasional Pengendalian Tuberkulosis. 2011;
8. Cantres-fonseca OJ, Rodriguez-cintrón W, Olmo-arroyo F Del, Baez-corujo S. Extra Pulmonary Tuberculosis : An Overview. In: Chauhan NS, editor. Role of Microbes in Human Health and Diseases. 2019. p. 1–16.
9. I. Rolston, Saul Rodriguez, N. D K V. Pulmonary infections mimicking cancer: a retrospective, three-year review. *Support Care Cancer* 1997;5(2):90–93.
10. Gállego Pérez-Larraya J, Hildebrand J. Brain metastases. *Handb Clin Neurol* 2014;121:1143–1157.
11. Go SW, Lee HY, Lim CH, et al. Atypical disseminated skeletal tuberculosis mimicking metastasis on PET-CT and MRI. *Intern Med* 2012;51(20):2961–2965.
12. Kementerian Kesehatan Republik Indonesia. Peraturan Menteri Kesehatan Republik Indonesia Nomor 67. Penanggulangan Tuberkulosis. *Dinas Kesehat* 2017;163.
13. Hong L, Wu JG, Ding JG, et al. Multifocal skeletal tuberculosis: Experience in diagnosis and treatment. *Med Mal Infect* 2010;40(1):6–11.
14. Pang Y, An J, Shu W, et al. Epidemiology of extrapulmonary tuberculosis among inpatients, China, 2008–2017. *Emerg Infect Dis* 2019;25(3):457–464.
15. Solovic I, Jonsson J, Korzeniewska-Kosela M, et al. Challenges in diagnosing extrapulmonary tuberculosis in the European Union, 2011. *Eurosurveillance* 2013;18(12):1–9.
16. Moore SL, Rafii M. Imaging of musculoskeletal and spinal tuberculosis. *Radiol Clin North Am* 2001;39(2):329–342.
17. Raut AA, Naphade PS, Ramakantan R. Imaging spectrum of extrathoracic tuberculosis. *Radiol Clin North Am* 2016; 54(3): 475–501.
18. Sakuraba M, Sagara Y, Komatsu H. Surgical treatment of tuberculous abscess in the chest wall. *Ann Thorac Surg* 2005;79(3):964–967.
19. Reedy, Ravikanth; Sunil, Mathew; Selvam RP. Calvarial Tuberculosis Presenting as Multiple Osteolytic Soft Tissue Lesions. *CHRISMED J Heal Res* 2014;1(2):2–4.
20. Raut AA, Nagar AM, Muzumdar D, et al. Imaging Features of Calvarial Tuberculosis: A Study of 42 Cases. *Am J Neuroradiol* 2004;25(3):409–414.
21. Garg RK, Somvanshi DS. Spinal tuberculosis: A review. *J Spinal Cord Med* 2011;34(5):440–454.
22. Cormican L, Hammal R, Messenger J, Milburn HJ. Current difficulties in the diagnosis and management of



- spinal tuberculosis. *Postgrad Med J* 2006;82(963):46–51.
23. Holeppagol KB, Nayak BN, Goyal RKK, Kumar AK, Sahoo PK, Biswal D. Neglected Recurrent Scalp Sinus: Calvarial Tuberculosis with Intracranial and Extracranial Extension. *World Neurosurg* [Internet] 2017;98:879.e5-879.e7. Available from: <http://dx.doi.org/10.1016/j.wneu.2016.11.065>
  24. Radiologist C, Hospital GT. Calvarial tuberculosis features in 3 cases. *West Engl Med J* 2013;112(1):2–4.
  25. Agrawal V, Patgaonkar PR, Nagariya SP. Tuberculosis of spine. *J Craniovertebr Junction Spine* 2010;1(2):74–85.