

A Rare Case of Unilateral Retinitis Pigmentosa: Challenges in Making a Diagnosis

Elyas Aditya¹, Syntia Nusanti¹, Muhammad Sidik¹, Ari Djatikusumo¹

¹ Department of Ophthalmology, Faculty of Medicine Universitas Indonesia, Cipto Mangunkusumo National Central General Hospital, Jakarta, Indonesia

ABSTRACT

Introduction: Retinitis pigmentosa (RP) is a hereditary disorder that diffusely involve photoreceptor and retinal pigment epithelial (RPE). It is characterized by progressive visual field loss and abnormal ERG. Unilateral RP is a rare condition that is usually sporadic. Clinical presentation and ancillary test results are similar to bilateral RP, with only one eye affected. In making the diagnosis of unilateral RP, clinicians must be able to rule out secondary causes, document a normal ERG in the unaffected eye, and follow-up the patient for at least 5 years to rule out bilateral but highly asymmetric disease. The aim of this case report is how to diagnose a rare case unilateral RP from clinical examination and ancillary tests.

Methods: We report a case of a 33-year-old female with slowly progressive restriction of visual field of the left eye in the last one year before admission. Ophthalmological examination of the left eye revealed bone spicules spreading to peripheral fundus. Visual field examination revealed severely constricted visual field of the left eye. The multifocal electroretinogram (mfERG) examination showed severely depressed ERG function with reduced foveal responses. The fellow eye was within normal limit.

Results: Patient was diagnosed with unilateral RP and must be followed-up for at least five years to rule out bilateral yet asymmetric disease. Making diagnosis of unilateral RP become one of the challenging case. Clinicians must be able to rule out the secondary causes that also have unilateral pigmentary retinal degeneration.

Conclusion: With a good clinical examination and some simple ancillary tests, we could correctly diagnose unilateral RP. However, in this case we still need five years follow up to rule out bilateral RP but highly asymmetric disease.

Key words: Unilateral Retinitis Pigmentosa, Unilateral pigmentary retinal degeneration, Multifocal Electroretinogram

Cite This Article: NUSANTI, Syntia et al. A Rare Case of Unilateral Retinitis Pigmentosa. International Journal of Retina, [S.l.], v. 2, n. 1, feb. 2019. ISSN 2614-8536. Available at: <<https://www.ijretina.com/index.php/ijretina/article/view/52>>

INTRODUCTION

Retinitis pigmentosa (RP) is a hereditary disorder that diffusely involve photoreceptor and retinal pigment epithelial (RPE), and is characterized by progressive visual field loss and abnormal ERG.¹ In early 1855, familial retinal degeneration with intraneural retinal pigmentation was first described by Donders.² Nowadays, it is well known that the majority of RP cases have a genetic basis and cause photoreceptor cell death through apoptosis.^{2,3} The prevalence of primary photoreceptor degeneration is 1: 3000 to 1: 5000. 4 Prevalence of recessive retinitis pigmentosa is approximately 1:100.⁵

Patient with RP usually complains about "night blindness", and tunnel vision (visual

field loss).² In ocular examination there are several key features of RP such as "Bone-spicule" intraneural retinal pigment, thinning and atrophy of the RPE in the mid- and far-peripheral retinal, relative preservation of the RPE in the macula, glitotic "waxy pallor" of the optic nerve head, and attenuation of the retinal arterioles.²

Unilateral RP is a rare condition that is usually sporadic. Clinical presentation and ancillary test findings are similar to bilateral RP, but only affect one eye. However, the vast majority of unilateral pigmentary retinal degenerations are likely to have an acquired origin like a history of vascular occlusion, history of trauma, uveitis, and infection.

*Correspondence to:

Syntia Nusanti,
Department of Ophthalmology,
Universitas Indonesia,
syntia_nusanti@hotmail.com

In making the diagnosis of unilateral RP, clinicians must be able to rule out such secondary causes, document a normal ERG in the unaffected eye, and run a routine follow-up of the patient for at least 5 years to rule out bilateral but highly asymmetric disease. This case report will discuss about the challenges in making diagnose of unilateral retinitis pigmentosa.

METHODS

A 33-years-old female came to the ophthalmologist with progressive restricted visual field of the left eye in the last one year before admission. There was no complaint of diminished visual acuity in the night. Patient went to an eye center and performed some ancillary test such as optical coherence tomography of the optic nerve, fundus fluorescein Angiography (FFA), orbital ct scan, and laboratory test. The patient was referred to Aini Hospital,

and the multifocal electroretinogram (meERG) examination was performed subsequently.

There was no history of hearing disorder, neuromuscular disorder, gastrointestinal disorder, renal disorder, dermatologic disorder, mental disorder, diabetic, and hypertension. There was no history of using retinal toxic drug (chloroquine, phenothiazine, etc), trauma, and eye redness. There was no history of similar complains in her family.

Ophthalmological examination revealed the uncorrected visual acuity was 6/12 on the both eyes, and 6/6 with correction (spheris -1.00) on the right eye and 6/6 F1 with correction (spheris -1.00) on the left eye. The intra ocular pressure was 10.0 mmHg on the right eye, and 9.7 mmHg on the left eye. There was no limitation of the ocular movement. Palpebral, conjunctiva bulbi, cornea, and anterior chamber of both eyes were within normal limits.

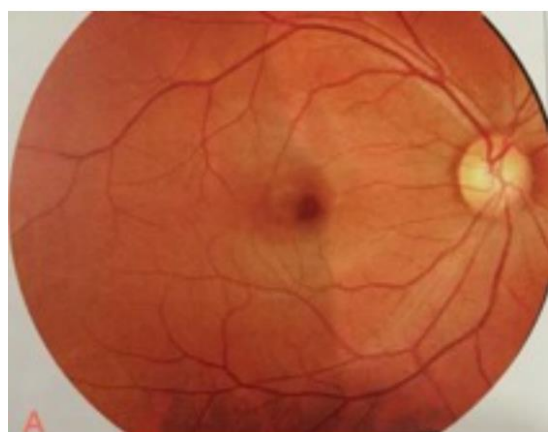


Figure 1A

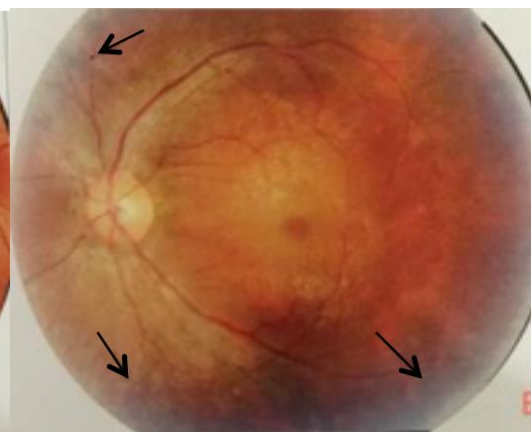


Figure 1B

The funduscopic examination of the right eye was normal (figure 1A). Meanwhile, fundus examination of the left eye showed cup-to-disc ratio was 0.3-0.4 and there were narrowing retinal vessels, depigmented RPE on macular region, and bone spicules spreading to peripheral fundus

(pointed by arrow). (figure 1B). The Ishihara test was within normal limits.

Fundus Fluorescein Angiography (FFA) examination revealed the right eye was within normal, but the left eye showed hyper fluorescein areas surround the optic nerve and peripheral fundus (pointed by arrow). (figure 2).

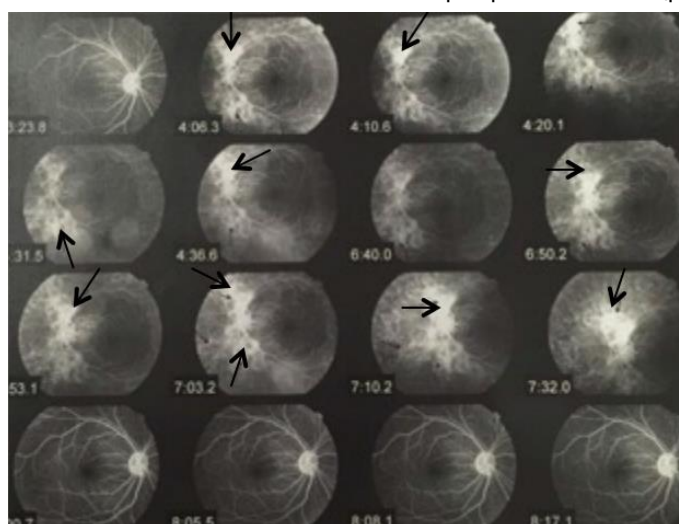


Figure 2. Fundus Fluorescein Angiography (FFA) examination

Visual field testing with Humphrey field analyzer showed there was no visual field defect of the right eye (figure 3A). On the other hand, there was severely depressed visual field on the left eye (figure 3B).

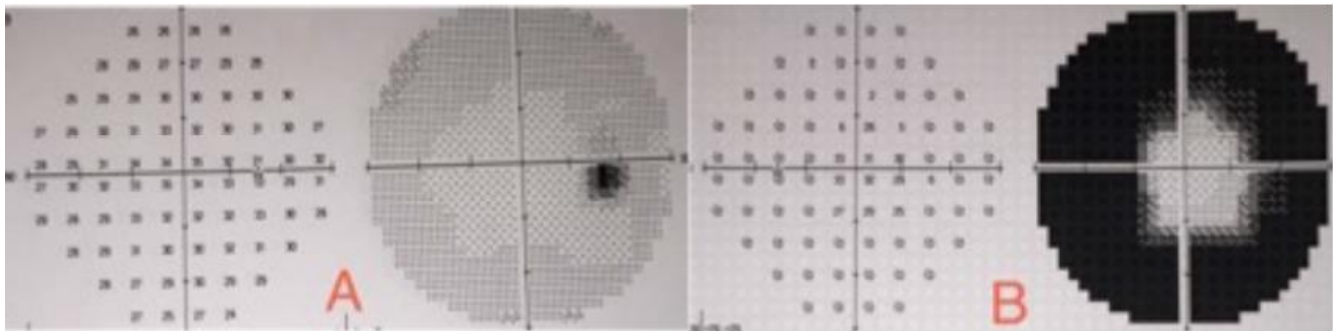


Figure 3A. Visual Field Testing of the Right eye. Figure 3B. Visual Field Testing of the Left eye

Optical coherence tomography (OCT) examination of optic nerve head showed both optic nerve head were within normal limit. Cup-to-disc ratio and mean retinal nerve fiber layer (RNFL) thickness of both optic nerve head were within normal limit. (figure 4A and 4B).

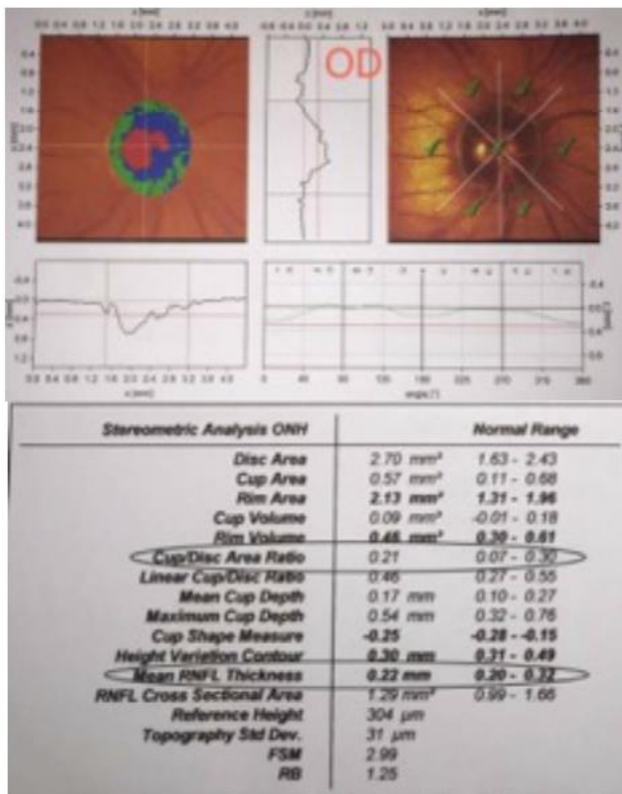


Figure 4A. OCT examination of optic nerve head of the Right eye

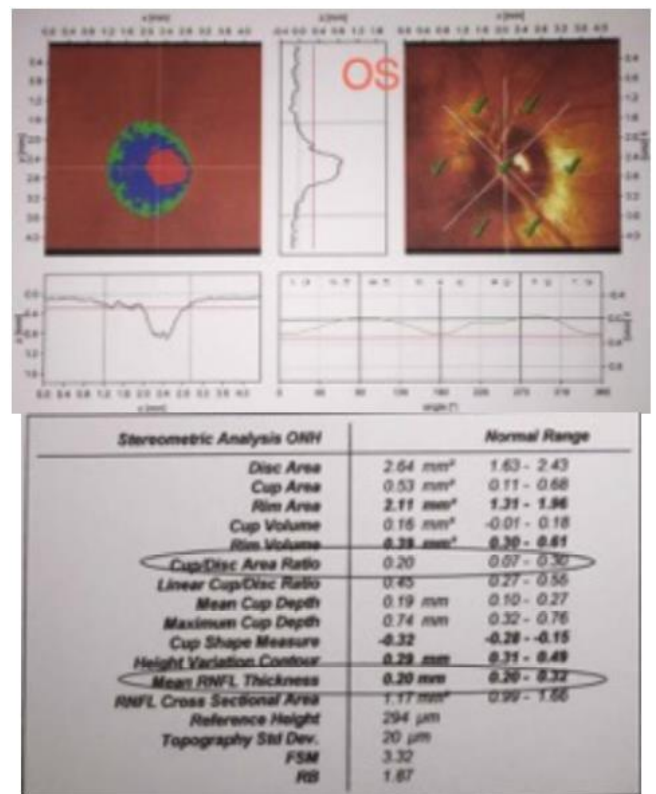


Figure 4B. OCT examination of optic nerve head of the Left eye

Laboratory examination revealed non-reactive anti-Toxoplasma IgM, antiRubella IgM, anti-CMV IgM, anti-HSV I IgG, anti-HSV I IgM, anti-HSV II IgG, anti-HSV II IgM and non-reactive anti-HIV tittered, but reactive anti-Toxoplasma IgG, antiRubella IgG, and anti-CMV IgG tittered. Another laboratory examinations such as ureum levels, creatinine, and HbA1c levels were within normal limit. Orbital and brain coherence tomography scan (CT

scan) showed there were no abnormality of orbital structures nor intracranial space occupying lesion (SOL). Multifocal electroretinogram (meERG) examination showed the ERG function of the right eye was within normal limit. On the other hand, the ERG function of the left eye was extremely depressed with reduction of foveal responses. (figure 5A and 5B).

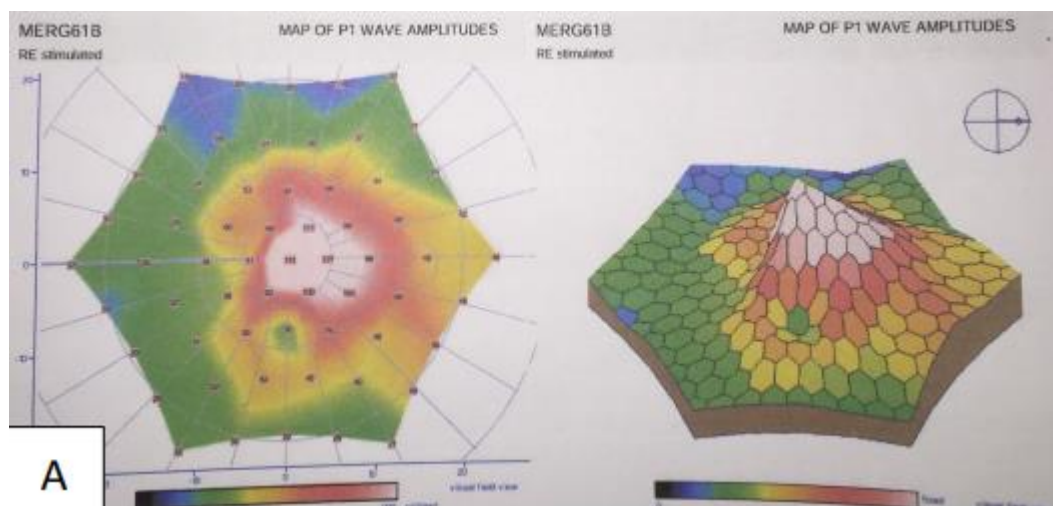


Figure 5A. meERG examination of the right eye.

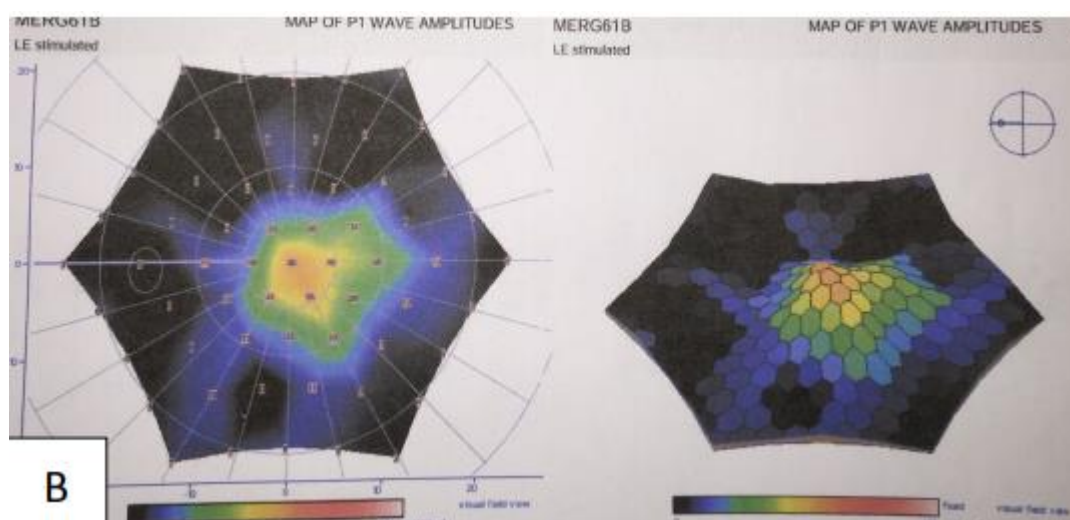


Figure 5B. meERG examination of the left eye.

RESULT

Patient was diagnosed as unilateral RP and must be followed up for at least five years to rule out bilateral but highly asymmetric disease.

DISCUSSION

In making diagnose of unilateral retinitis pigmentosa become one of the challenging case. Clinicians must rule out the secondary causes that also have unilateral pigmentary retinal degeneration such as a previous vascular occlusion, trauma, uveitis, infection, or retained metallic intraocular foreign body.¹ The term retinitis pigmentosa (RP) refers to disorders that affect the photoreceptors and retinal pigment epithelium (RPE) diffusely across the entire fundus but begin with initial geographic involvement in either the periphery or the macula.² It is now understood that the majority of cases have a genetic basis and involve photoreceptor cell death through apoptosis.² RP could be seen in isolation (typical RP) or in association with systemic disease (syndromic RP).

The prevalence of typical RP is approximately 1:5000 worldwide. Prevalence of RP is approximately 1:7000 in Switzerland, 1:4016 in China, and 1:4500 in Israel. The prevalence of syndromic RP is less well documented. In example, the prevalence of Usher syndrome (RP with congenital deafness) is estimated to be 1:6000.⁶ Patient with typical retinitis pigmentosa has some typical symptoms such as nyctalopia, visual field loss, central vision loss, color vision defects, and photopsia.⁶ Patients with typical RP usually complains night vision difficulties in the first or second decade of life. People with RP have narrow visual field in the dark and may get easily disoriented on dim light.⁶ The second hallmark feature of RP is an insidious, progressive loss of peripheral visual field. For many types of RP, visual field deficits are usually found first, and are most severe in the superior visual field. (figure 6) This reflects the early involvement of the inferior retina in RP.

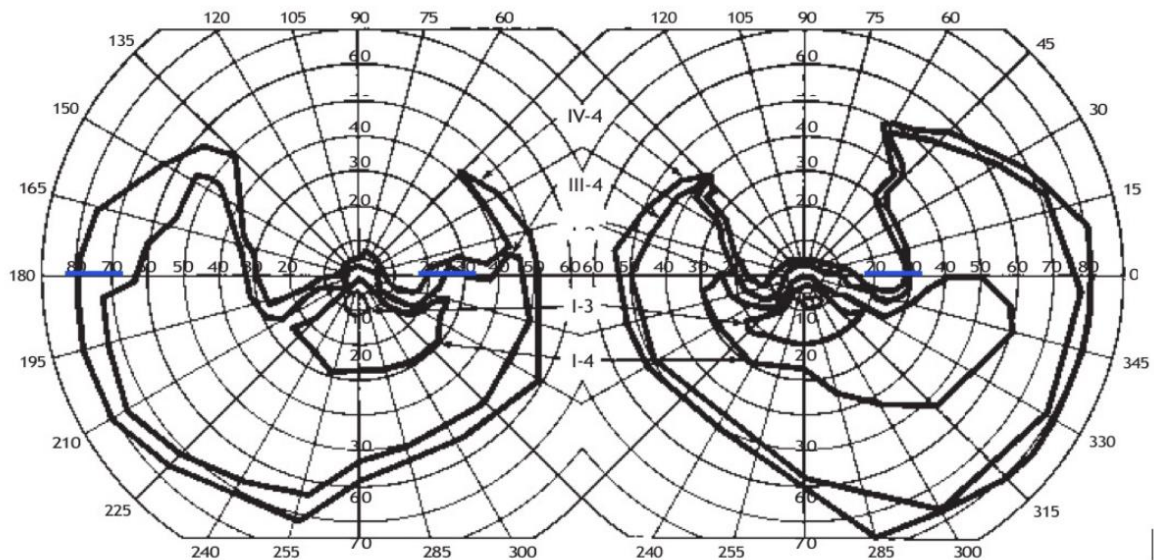


Figure 6. superior visual field deficits due to early involvement of the inferior retina in retinitis pigmentosa⁶

In typical RP, visual field loss is usually progressing slowly (years or decades). However, visual fields may change dramatically over a few months or years. The visual field loss may be unnoticeable, if the central field remains clear.⁶

Patient complained restriction of visual field in the last one year before admission. Visual field loss is caused by initial involvement of photoreceptors which leads to subsequent damage to inner retinal cells.⁶ The patient didn't notice as the visual field defect was slowly progressing from the peripheral side. There was no diminished visual acuity in the night (night blindness). The night blindness may be unnoticeable due to the unilateral

involvement of the disease; therefore, this complaint may be compensated by the other eye. Typical fundus findings in RP include arteriolar narrowing, optic nerve head pallor, and intraretinal bone spicule pigmentation.^{1,6} (figure 7) Intraretinal bone spicule pigment formations represent migration of pigment into the retina from disintegration of RPE cells with accumulation in the interstitial spaces surrounding retinal vessels.⁶ Fundus examination of the left eye in this patient revealed there were narrowing of retinal vessels, depigmented retinal pigment epithelium (RPE) on macular region, and bone spicules spreading to peripheral fundus (figure 7).

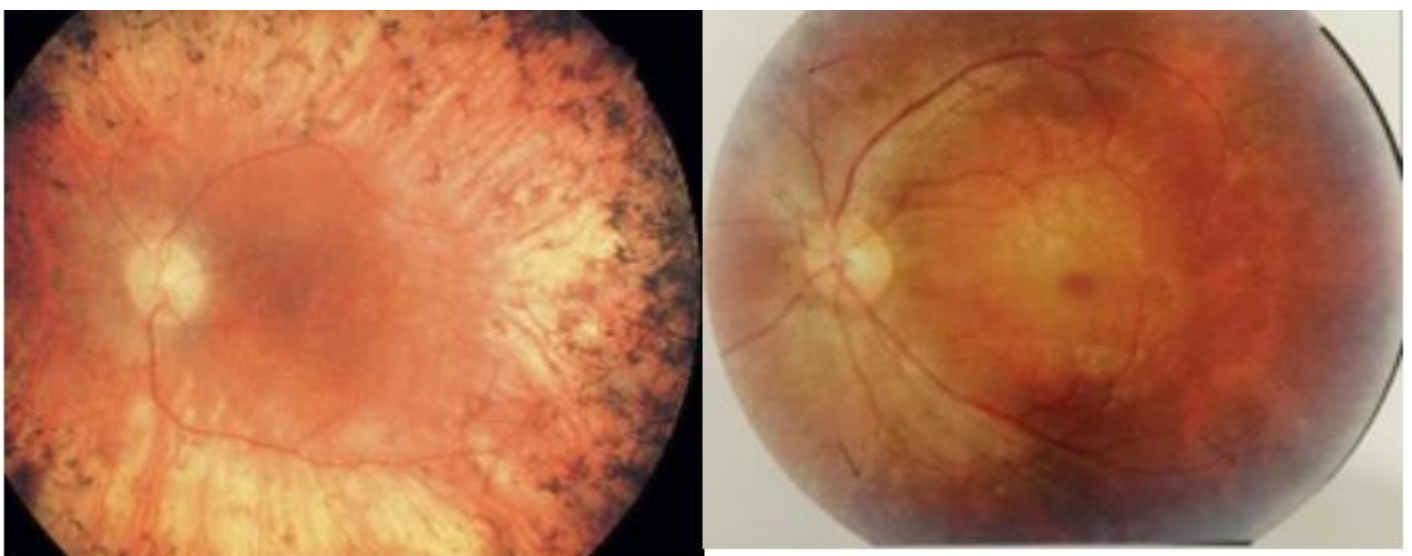


Figure 7. Typical fundus findings in RP (left picture)⁶. Fundus examination on patient's left eye (right picture)

Based on the patient's chief complaint, several diseases that have similar complaints (visual field defect) such as glaucoma, retinal disease, or a neuroophthalmologic entity should be considered.⁷ As we know, enlargement of the cup may be the earliest change detected in glaucoma. This enlargement can be difficult to be noticed unless previous photographs or diagrams are available. Confocal scanning laser ophthalmoscopy can be used to create a 3D image of

the optic nerve head. Parameters such as cup area, cup volume, rim volume, CDR, and peripapillary nerve fiber layer thickness are then calculated.⁸ This examination was performed to our patient and the results were within normal limit (figure 8). There was no neuroretinal thinning, CDR and mean RNFL thickness were within normal limit. Based on these results, we can exclude glaucoma as the etiology of visual field constriction in this patient.

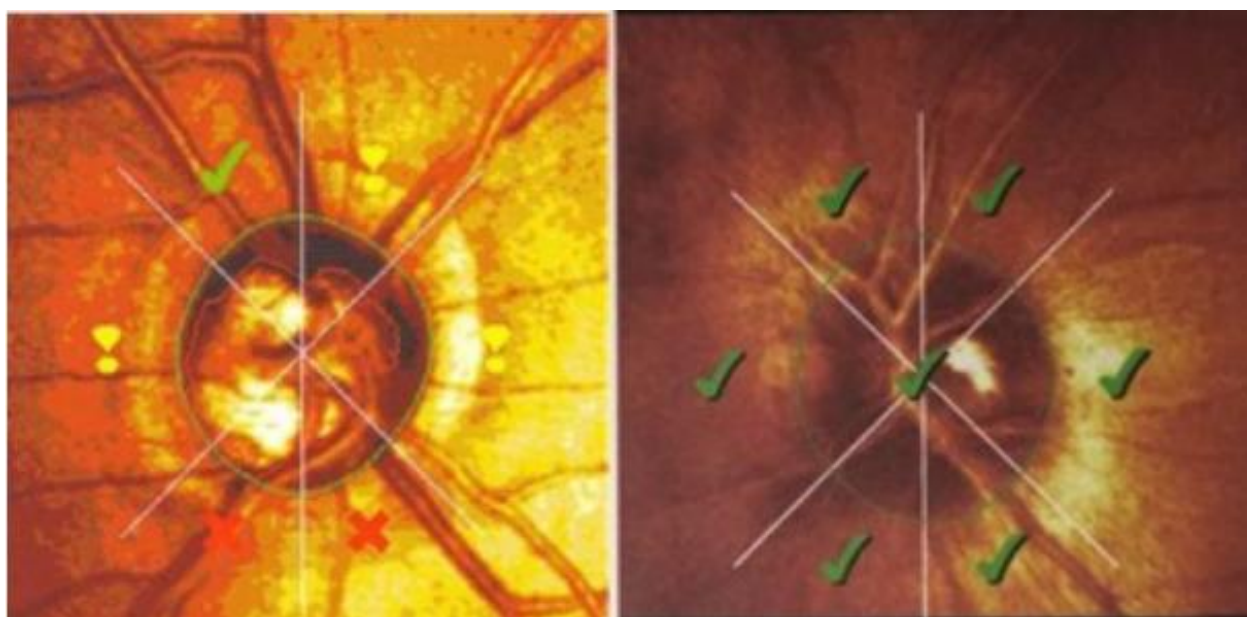


Figure 8. **Confocal scanning laser ophthalmoscopy of glaucomaotus optif nerve (left picture)⁸. Confocal scanning laser ophthalmoscopy of patient's left eye (right picture)**

One of neuro-ophthalmologic disorder that we have to be concern in patient complaining unilateral field defect is compressive optic neuropathies.⁷ Compressive optic neuropathies (CON) are diseases of the optic nerve that can cause visual loss secondary to pressure on the optic nerve, either within the orbit, inside the optic canal or intracranially.⁹ The highly specific clinical characteristics for a compressive lesion are age less than 50 years, optic nerve pallor and cupping, visual field defects at the vertical meridian, unilateral field defects, and visual acuity less than 20/40.⁷ We can exclude CON as the etiology of unilateral field defect, because the visual acuity was 6/6 with correction, there were no pallor and cupping optic nerve, and the orbital and brain coherence tomography scan (CT scan) showed there were no abnormality of orbital structures nor intracranial space occupying lesion (SOL).

Multifocal ERGs (mfERG) examination in patient with RP reveals a normal amplitude in macular area, but the

topographic map of the multifocal ERGs shows an extremely reduced periphery, indicating marked reduction of the peripheral responses (figure 9).¹⁰ MfERG examination showed the ERG function of the right eye was within normal limit. In contrast, the ERG function of the left eye was extremely depressed with reduction of foveal responses. The rods and cones components of the left eye at peripheral side were nearly undetectable and focal macular ERGs stimulus of the left eye was smaller than the right eye (figure 9). Based on this mfERG result, we can conclude that the left eye was in the advanced stage of the disease. Majority form of retinitis pigmentosa initially leads to death of the rod photoreceptors.² Severe cone involvement occurs in the end stage of the disease, when total vision loss happens.² This conclusion was supported by a "tunnel vision" visual field test which indicate the disease had been in the advanced stage.

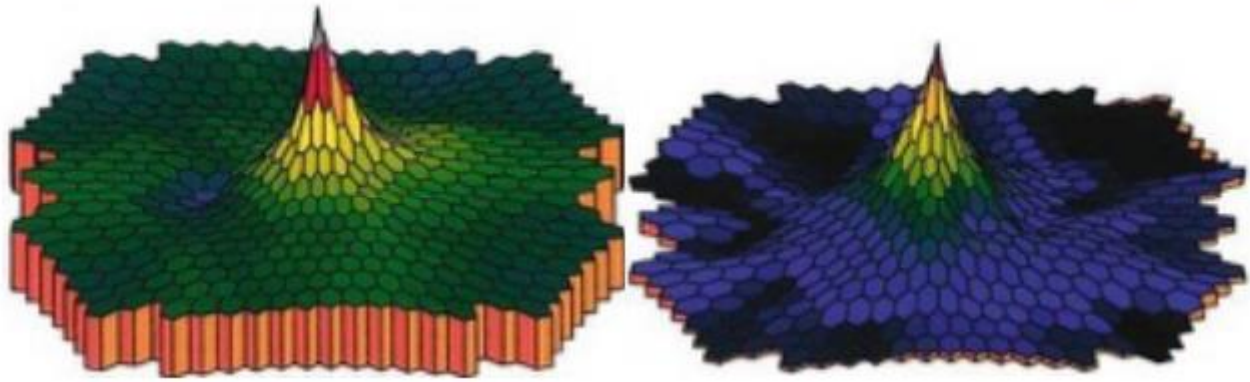


Figure 9A. MfERG examination of normal eye (left picture). MfERG examination of patient with RP (right picture)¹⁰



Figure 9B. MfERG examination of patient's left eye

In making the diagnosis of unilateral RP, we must rule out the secondary causes that show unilateral pigmentary retinal degeneration, such as previous vascular occlusion, trauma, uveitis, infection (diffuse unilateral subacute neuroretinitis), or retained metallic intraocular foreign body. 1 Based on anamnesis, there were no history of trauma, nor retained metallic intraocular foreign body. We can directly rule out the history of trauma and retained metallic intraocular foreign body as the etiology of unilateral pigmentary retinal degeneration. In diagnosing unilateral RP, we have to rule out the history of vascular

occlusion in this patient, because it can reveal unilateral pigmentary degeneration like we find in unilateral RP. 1 Patients with history vascular occlusion usually complain about sudden painless loss of vision. The visual field defect is usually isolated to one eye and may be partial (branch retinal artery occlusion and cilioretinal artery occlusion) or complete (central retinal artery occlusion and ophthalmic artery occlusion). In the ophthalmological examination, patient with long standing central retinal artery occlusion (CRAO) will reveal neovascularization of the iris and attenuated retinal arteries (figure 10).¹¹

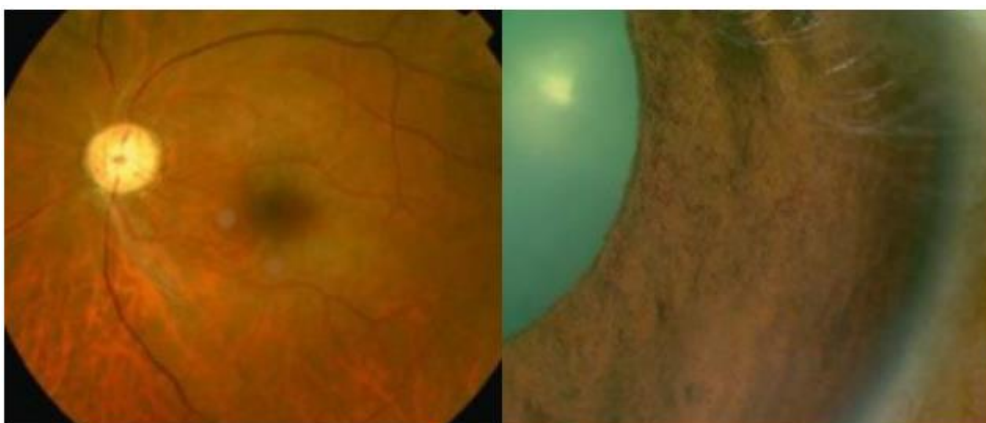


Figure 10. Attenuated retinal arteries in CRAO (left picture). Neovascularization of the iris in CRAO (right picture)¹¹

In CRAO, despite the extremely constricted visual fields and poor visual acuity, the ERGs in the affected eye is relatively well preserved. Although the b/a ratio in the affected eyes is lower than that of fellow eye, none of the ERGs from the affected eyes has a negative configuration. (figure 11) These results suggest that the function of the retinal layer related to the ERG can recover to some degree following recovery of the retinal circulation, as demonstrated by fluorescein angiography.¹²

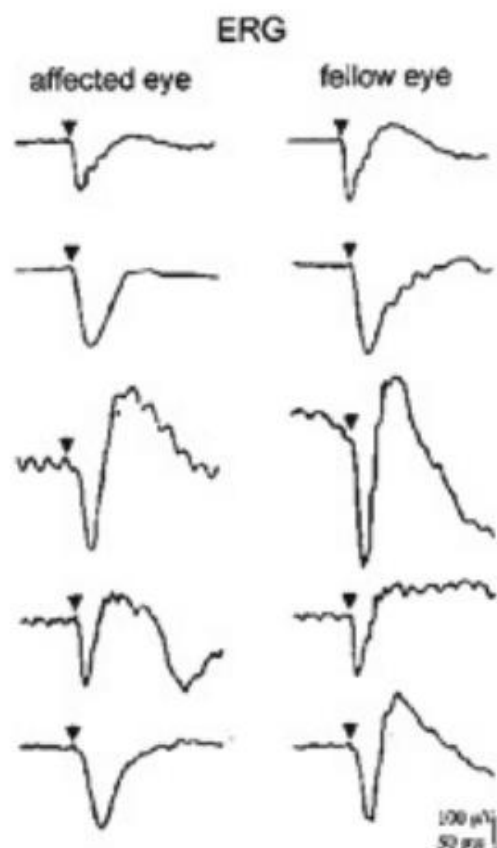


Figure 11. Full-field ERG examination on eye with CRAO¹²

Based on anamnesis, ophthalmological examination, and multifocal electrophysiology exam, we can exclude prior artery occlusion in this patient. The patient did not complain about sudden, painless vision loss, only visual field restriction. In ophthalmological examination, there were no neovascularization of the iris found. ERGs in the CRAO is relatively well preserved. In contrast, the ERG function of the patient's left eye was depressed with reduction of foveal responses. In diagnosing RP, we have to rule out uveitis as the secondary causes that can reveal pigmentary retinal degeneration.¹ Congenital or acquired syphilis can present as pigmentary retinopathy that resembles advanced retinitis pigmentosa.¹³ (figure 12). Pseudoretinitis pigmentosa can be found in ocular acquired syphilis. This finding can be found in secondary syphilis with other manifestations include apulosquamous

eyelid rash, alopecia of the eyebrows and eyelashes, dacryocystitis, signs of conjunctivitis, episcleritis, scleritis, iris papules, lens dislocation, interstitial keratitis, intermediate uveitis, posterior uveitis, panuveitis, cystoid macular edema, and sign of retinitis (including retinal necrosis).¹⁴

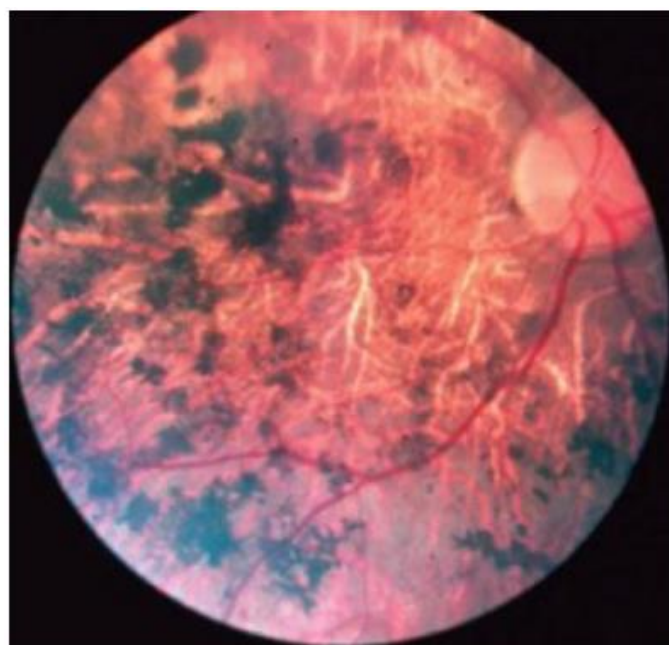


Figure 12. Pigmentary retinopathy in acquired syphilis¹³

Full-field ERGs are usually subnormal, unlike the undetectable ERGs from retinitis pigmentosa (figure 13).¹⁵ Diagnosis of ocular syphilis can be made by serologic testing. The Venereal Disease Research Laboratories (VDRL) and rapid plasma reagin (RPR) antibody tests can indicate active disease but may be negative in tertiary disease. The fluorescent treponemal antibody absorption (FTA-Abs) test is the most specific test of infection.¹³

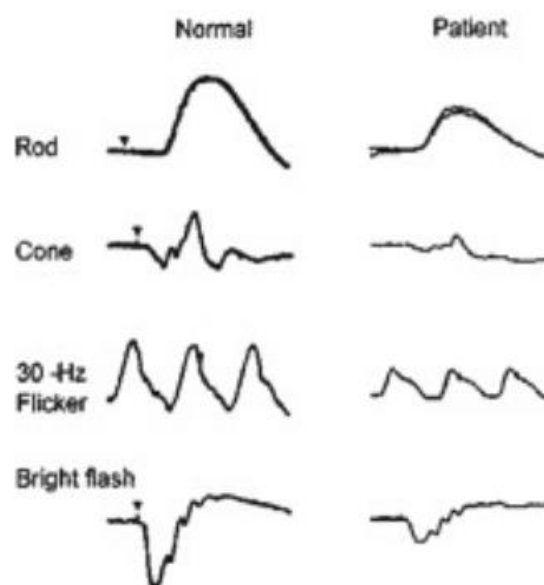


Figure 13. Full-field ERG in ocular syphilis¹⁵

VDRL or RPR and FTA-Abs were not performed in our patient. Nevertheless, based on anamnesis, ophthalmological examination, and multifocal electrophysiology exam, we can still rule out ocular syphilis as the etiology of unilateral pigmentary retinal degeneration in this patient. The patient did not complain about eye redness that can be found in uveitis and ophthalmological examination revealed a normal anterior segment. There were no signs of papulosquamous eyelid rash, alopecia of the eyebrows and eyelashes, interstitial keratitis, signs of conjunctivitis, episcleritis, scleritis, iris papules, lens dislocation, and signs of uveitis. Based on ERG examination, ocular syphilis revealed relatively good responses than recorded in our patient.

Retinopathy is the most common finding in congenital rubella syndrome (CRS). It may be unilateral or bilateral. Fine, granular, symmetric mottling of the pigment epithelium is seen in the posterior fundus. Occasionally, pigment spicules and changes in the choroidal vasculature may be seen.¹³⁻¹⁶ However, pigment spicules in our patient were unlikely caused by CRS. Based on anamnesis, the onset of the symptom was one year before admission, whereas the onset of CRS should be presented since birth. There was no cardiac malformation, cataract, corneal clouding, microphthalmia, strabismus, or deafness which can be found in CRS.¹⁶ Most often today, the diagnosis of rubella is attempted by the use of a single serum test for identifying rubella IgM antibody.¹⁷ From the laboratory test, we found a non-reactive anti Rubella IgM in our patient. Based on anamnesis, ophthalmological exam, and laboratory test, rubella was then excluded.

The most common form of unilateral pigmentary retinopathy referred to as unilateral RP is diffused unilateral subacute neuroretinitis (DUSN). DUSN is the term used for the disorder previously called "unilateral wipe-out syndrome," and "unilateral RP." True unilateral inherited RP does not exist, except as an example of extreme lyonization of retinal involvement in a carrier of X-linked RP. This disease is believed to result from the panretinal degeneration that have been infected by any of several possible worms.⁶

The pathogenesis of DUSN appears resulting from a local toxic reaction by the products of the worm. This toxic reaction affects both the inner and outer retinal tissues. This later reaction is manifested initially by rapid loss of visual function and alterations of the ERGs, suggesting inner retinal abnormalities.¹⁸ Another features of late stage DUSN are pigment epithelial disruption, and pigment migration into the retina (bone spicule).¹⁹ One of the important examination that excludes DUSN as the etiology of unilateral pigmentary retinal degeneration in our patient is ERG examination. The rod and cone components of the full-field ERGs in DUSN were moderately reduced, whereas

the rod and cone components in the unilateral RP were extremely depressed or nearly undetectable.^{10,18} (figure 14)




Figure 14. **mfERG in diffused unilateral subacute neuroretinitis (left picture)¹⁸.mfERG in patient's left eye.**

With clinical examination and some ancillary tests, we can make a clinical diagnosis of RP. Nowadays, there is genetic test for to confirm clinical diagnosis of RP and provide additional information about familial risk. Genetic information can be informative for prognosis, and providing risk information to family members. From a perspective research, genetic testing improves the understanding of the pathophysiology of the disease and provides information for gene-based therapies.² Unfortunately we did not perform this examination because it is still not available in Indonesia. Our patient was included in primary RP, because the disease only involved the eyes, without any other systemic manifestations.¹ Based on clinical examination and some ancillary test we could diagnose unilateral RP in our patient. Nevertheless, to make a diagnosis of true unilateral RP, we must follow the patient for at least five years to rule out bilateral but highly asymmetric disease.¹ Unilateral RP can occur in two mechanisms. The first is the carrier state for X-linked RP. Lyonization, or X-chromosomal inactivation, occurs close in time to lateralization during embryogenesis. Thus, if the number of cells undergoing inactivation of the X-chromosomes that contain the normal gene for RP is uneven at the time of lateralization and, by chance occurrence, a greater number of those cells are directed to one side of the developing embryo, the carrier will express an extremely asymmetrical phenotype with asymmetrical field loss and pigmentary changes. The second mechanism can occur as a genetic trait is through somatic mosaicism of a dominant gene for RP. This mechanism has been reported as the cause of unilateral RP in a patient with somatic mosaicism of RP1.⁶ Because these diseases are rare, most ophthalmologists have limited experience working with retinal dystrophy patients. Management of RP includes regular ophthalmic evaluation at intervals of 1-2 years. Although the death of photoreceptor cells in RP cannot be reversed, routine follow up allows the clinician to monitor progression with visual field and ERG evaluation.¹

It is important to support the patient to become adjusted to RP by supplying useful information of RP, by giving appropriate correction of refractive error and access to low-vision aids, cataract extraction or treatment of macular edema when it indicated.⁶ Various nutritional

supplements have been investigated as therapy for RP such as vitamin A, docosahexaenoic acid (DHA), and lutein supplements.¹⁻⁶ Nowadays, gene therapy is one of the future management of RP. ^{6,20} As a target for genetic manipulation, the retina has some advantages. Target cells (usually photoreceptors) are more directly accessible than in most tissues, and the effects of manipulations can be directly observed.⁶ The visual prognosis of patient with RP is poor.²¹ Most patients with RP are anxious about the possibility of blindness. However, total blindness is an infrequent endpoint, and prognosis of each patient varies depending on the clinical findings.¹ The visual prognosis of our patient is poor, as the visual field was severely depressed and the ERG function was extremely depressed with reduction of foveal responses.

CONCLUSION

Making the diagnosis of unilateral RP has become one of the most challenging case. Clinicians must be able to rule out the secondary causes that show unilateral pigmentary retinal degeneration such as a previous vascular occlusion, trauma, uveitis, infection, or retained metallic intraocular foreign body. Based on clinical examination and some ancillary tests, the patient was diagnosed with unilateral RP. Nevertheless, to make a diagnosis of true unilateral RP, we must do a routine follow-up of the patient for at least five years to rule out bilateral, yet highly asymmetric disease.

ACKNOWLEDGMENTS

Address for reprints and sources of support that require acknowledgement is none.

REFERENCES

- American Academy of Ophthalmology: Hereditary Retinal and Choroidal Dystrophies. In: Retina and Vitreous, Basic and Clinical Science Course. San Francisco: American Academy of Ophthalmology; 2003. p: 228-236
- Cukras Catherine, Zein Wadih. Progressive and 'Stationary' Inherited Retinal Degenerations. In: Ophthalmology 4th edition. Elsevier. 2014. 480-490
- Nettleship E. In: retinitis pigmentosa and allied diseases. R Lond Ophthalmol Hosp Rep 1907. p:1-56.
- Boughman JA, Conneally PM, Nance WE. Population genetic studies of retinitis pigmentosa. Am J Hum Genet 1980. p: 223-35.
- Daiger SP, Bowne SJ, Sullivan LS. Perspective on genes and mutations causing retinitis pigmentosa. Arch Ophthalmol 2007. p:151-8.
- Evans Kevin, Pennesi Mark. Retinitis Pigmentosa and Allied Disorders. In: Retina 5th edition. Elsevier. 2013. p: 761-835.
- Moster Mark, Kay Matthew. Glaucoma: The Neuro-ophthalmologic Differential Diagnosis. Jaypee Journals. Jaypee Brothers Medical Publishers. 2013.
- American academy of Ophthalmology: Clinical Evaluation. In: Glaucoma, Basic and Clinical Science Course. San Francisco: American Academy of Ophthalmology; 2003. p: 51-54.
- Falardeau Julie, Oregon Portland. Compressive Optic Neuropathies. In: Roy and Fraunfelder's Current Ocular Therapy 6th edition. Elsevier. 2008. p: 575-6.
- Miyake Y. Hereditary Retinal and Allied Disease. In: Electrodiagnosis of Retinal Diseases. Springer. Tokyo: 2006. p: 45-50.
- Burton M, Gregor Z. Retinal Arterial Occlusion. In: Retinal Vascular Disease. Springer. Berlin. 2007. p: 510-1.
- Miyake Y. Central Retinal Artery Occlusion. In: Electrodiagnosis of Retinal Diseases. Springer. Tokyo: 2006. p: 180-2.
- Lew Julie, Friedman Alan. Infectious Causes of Posterior Uveitis. In: Albert & Jakobiec's Principles & Practice of Ophthalmology 3rd edition. Elsevier. 2008. p: 1173-93.
- Shalaby Ismail. Acquired and Congenital Syphilis. In: Roy and Fraunfelder's Current Ocular Therapy 6th edition. Elsevier. 2008. p: 2-4.
- Miyake Y. Luetic Chorioretinitis. In: Electrodiagnosis of Retinal Diseases. Springer. Tokyo: 2006. p: 196.
- American Academy of Ophthalmology: Infectious Ocular Inflammatory. In: Intraocular Inflammation and Uveitis, Basic and Clinical Science Course. San Francisco: American Academy of Ophthalmology; 2003. p: 209-11
- Cherry James, Adaci Kristina. Rubella Virus. Feigin and Cherry's Textbook of Pediatric Infection Diseases 7th edition. Saunders. 2014. p: 2218.
- Miyake Y. Diffuse Unilateral Subacute Neuroretinitis. In: Electrodiagnosis of Retinal Diseases. Springer. Tokyo: 2006. p: 191-2.
- Jumper Michael, McDonald Richard. Diffuse Unilateral Subacute Neuroretinitis. In: Albert & Jakobiec's Principles & Practice of Ophthalmology 3rd edition. Elsevier. 2008. p: 2135-40.
- Berson Eliot. Retinitis Pigmentosa and Allied Diseases. In: Albert & Jakobiec's Principles & Practice of Ophthalmology 3rd edition. Elsevier. 2008. p: 2225-52.
- Kansky J. Fundus Dystrophies. In: Clinical Ophthalmology: a Synopsis. 2009. Elsevier. p:354-5.



This work licensed under Creative Commons Attribution