

REMARKABLE RESULT TOWARDS RETINOPATHY ASSOCIATED AUTOIMMUNE HEMOLYTIC ANEMIA

Rofa Husnul Khuluqi¹, Nadia Artha Dewi¹, Susanto Nugroho², Lely Retno Wulandari¹

¹ Department of Ophthalmology, Universitas Brawijaya, Dr. Saiful Anwar General Hospital, Malang, East Java, Indonesia

² Department of Pediatrics, Universitas Brawijaya, Dr. Saiful Anwar General Hospital, Malang, East Java, Indonesia

Abstract

Introduction: To present the clinical findings of Autoimmune hemolytic anemia (AIHA) Retinopathy and its rapid resolutions following treatment with steroid.

Case report: A 14-year-old female patient presented with decreased vision in the left eye. There was history of AIHA. Visual acuity was 1/60 in LE and 6/6 in RE. There was conjunctival pallor, and the other anterior segment were unremarkable. Fundus examination of left eye revealed flame shaped and dot blot hemorrhage, roth's spots, optic disc swelling, venous tortuosity, and elevated macula. There were afferent pupil defect, red green deficiency, and contrast sensitivity decline. Hematological evaluation revealed anemia. A MRI Head and Orbital examination were unremarkable.

Discussion: This patient was assessed with LE Anemic retinopathy due to AIHA. The patient's visual acuity improved as the retinopathy resolved after 1 month of oral steroid therapy.

Conclusion: Anemia may play a role in the occurrence of retinopathy. The diagnosis of retinopathy can be made by linking ophthalmic findings with positive serological test. Accurate comprehensive examination can establish the systemic diagnosis, and control of systemic parameters will improve retinopathy, reverse vision loss, and avoid permanent blindness

Keywords: Autoimmune hemolytic anemia, pediatric AIHA, Retinal Hemorrhage

Cite This Article: KHULUQI, ROFA HUSNUL. REMARKABLE RESULT TOWARDS RETINOPATHY ASSOCIATED AUTOIMMUNE HEMOLYTIC ANEMIA. International Journal of Retina, [S.l.], v. 5, n. 1, p. 53, feb. 2022. ISSN 2614-8536. Available at: <<https://www.ijretina.com/index.php/ijretina/article/view/190>>.

doi: <https://doi.org/10.35479/ijretina.2022.vol005.iss001.190>.

Correspondence to:

Rofa Husnul Khuluqi,
Department of Ophthalmology,
Universitas Brawijaya,
Indonesia
rofakhuluqi@gmail.com

INTRODUCTION

Anemia is characterized by decrease level of hemoglobin in blood. Autoimmune hemolytic anemia (AIHA) is one type of anemia, which erythrocytes are attacked by the patient's own antibodies.^{1,2} Etiology of autoimmune response is unknown, but it may include idiopathic, viral infections, autoimmune disease, blood malignancy, immune deficiency, bone marrow transplant, history of previous blood transfusion, and use of certain drugs.^{1,3}

Autoimmune hemolytic anemia is a rare etiology of hemolytic anemia in children with an incidence of approximately 0.2 – 0.4 per 100,000 people in the group of ages 11-20 years. Despite of it's etiology, anemia is accompanied by many ocular manifestations. Pale conjunctiva is the most common ocular manifestation that found in 98% of cases, followed by retinopathy which occurred in 42% of cases and pallor of posterior pole in 39% case.^{4,5} Study by Carraro et al revealed that anemia can causes retinopathy in 28% cases, and increase to 38% cases when there is coexisting thrombocytopenia.⁶ Manifestations of anemic retinopathy may include retinal hemorrhage, white-centered retinal hemorrhages (roth spots), sub-hyaloid and vitreous hemorrhages, venous and arteriolar turtuosity, cotton wool spots, macular stars and edema papil. Increasing severity of anemia, directly proportional to increased risk of retinopathy, especially when level hemoglobin (Hb) below 6 grams/ dL.^{3,7} The prevalence of anemic retinopathy is 83% of cases, among patients with severe anemia (<8gr/dl).³

Here, we present a case of retinopathy in children which is related to AIHA and it's rapid resolution after anemia treatment.

CASE PRESENTATION

A 14-year-old girl was consulted to Ophthalmology department by Pediatrician in Saiful Anwar Hospital with sudden painless blurred vision in her left eye for 3 days duration, during hospital admission for autoimmune hemolytic anemia. She also complained about dizziness and weakness, nausea and signs of bleeding in the other part of body. Patient has been diagnosed with AIHA since 1.5 years ago with previous positive Coombs test.

The patient received therapy from pediatric involved of intravenous methylprednisolone 35 mg three time a day, intravenous metamizole 500 mg three time a day and oral sucralfate 15 mg three time a day. Ophthalmological examination revealed visual acuity of 6/6 in the right eye and 1/60 in the left eye. Anterior segment examination revealed pallor on the conjunctiva of both eyes and positive RAPD examination on left eye. Other anterior segments examination and intraocular pressure measurement were unremarkable on both eyes.

Dilated Fundus examination revealed segmental optic nerve head swelling, dot blot hemorrhages, flame-shaped hemorrhage and venous turtuosity, only in left eye. Optic nerve function examination showed red green deficiency with ishihara plate in her left eye. Amsler Grid examination revealed metamorphopsia in central of left eye. Optic nerve head and macular Optical Coherence Tomography (OCT) examination showed left intraretinal hyperreflection, retina and macular thinning, and peripapillary RNFL thickening,

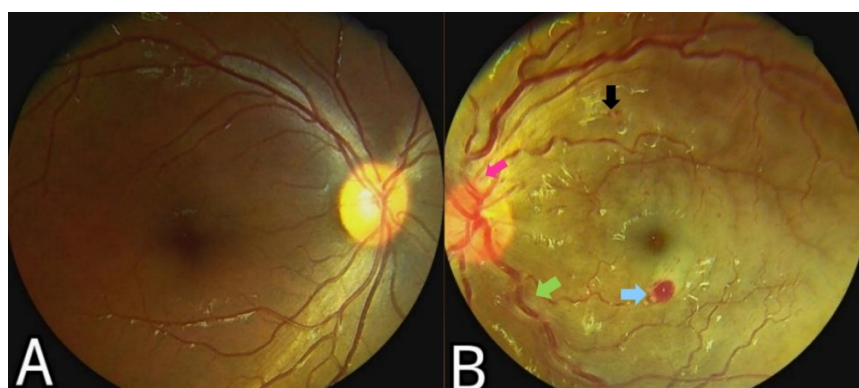


Figure 1. (A) Fundus photograph of the right eye compared to (B) left eye on first examination. Right Eye are normal findings, while the left eye revealed, segmental papilledema (pink arrow), venous turtuosity (green arrow), dot blot (black arrow) and flame shaped hemorrhage (blue arrow).

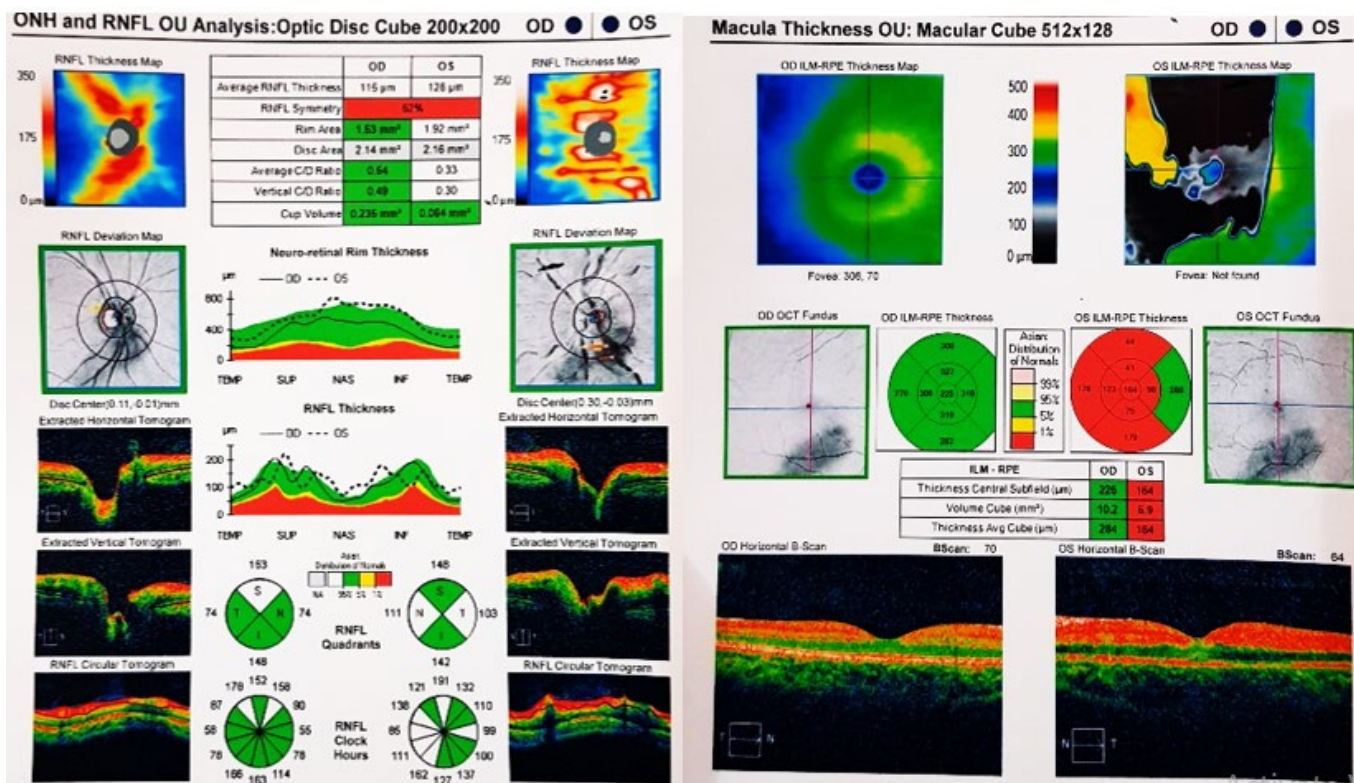


Figure 2. Optic nerve head OCT (left) and macular OCT (right) at first examination. There were intraretinal hyperreflective, retinal and macular thinning, and peripapillary thickening of the left eye. Right eye showed normal findings.

Her hemoglobin level was markedly low (7.0 g/dl) but the leucocyte and platelet counts were normal. The peripheral blood smear revealed hypochromic microcytic anemia. The patient was treated with oral steroid provided by pediatrician.

The patient had worsening symptoms 5 days after initial treatment. Her left visual acuity was decrease to counting finger at half meter without new abnormal findings on her anterior segment. Only left RAPD was detected, while the other optic nerve function test such as isihara, amsler grid, contrast sensitivity and confrontation tests were difficult to assess due to poor visual acuity.

Posterior segment examination showed marked left optic disc swelling with dot blot hemorrhage, flame shaped hemorrhage, roth's spot, arteriovenous tortuosity, retinal edema and macular edema. Optic nerve and Macular OCT examination of the left eye showed blurred disc margin and exudation in subretina respectively.

The patient was consulted to the Neuro-Ophthalmologist (NO) due to worsening left papilledema and then was suspected with left infiltrative optic neuropathy. Patient were planned for Head and Orbita MRI examination and complete blood count. Steroid treatment with methylprednisolone 32 mg three time a day orally, was continued according to pediatrician's advice.

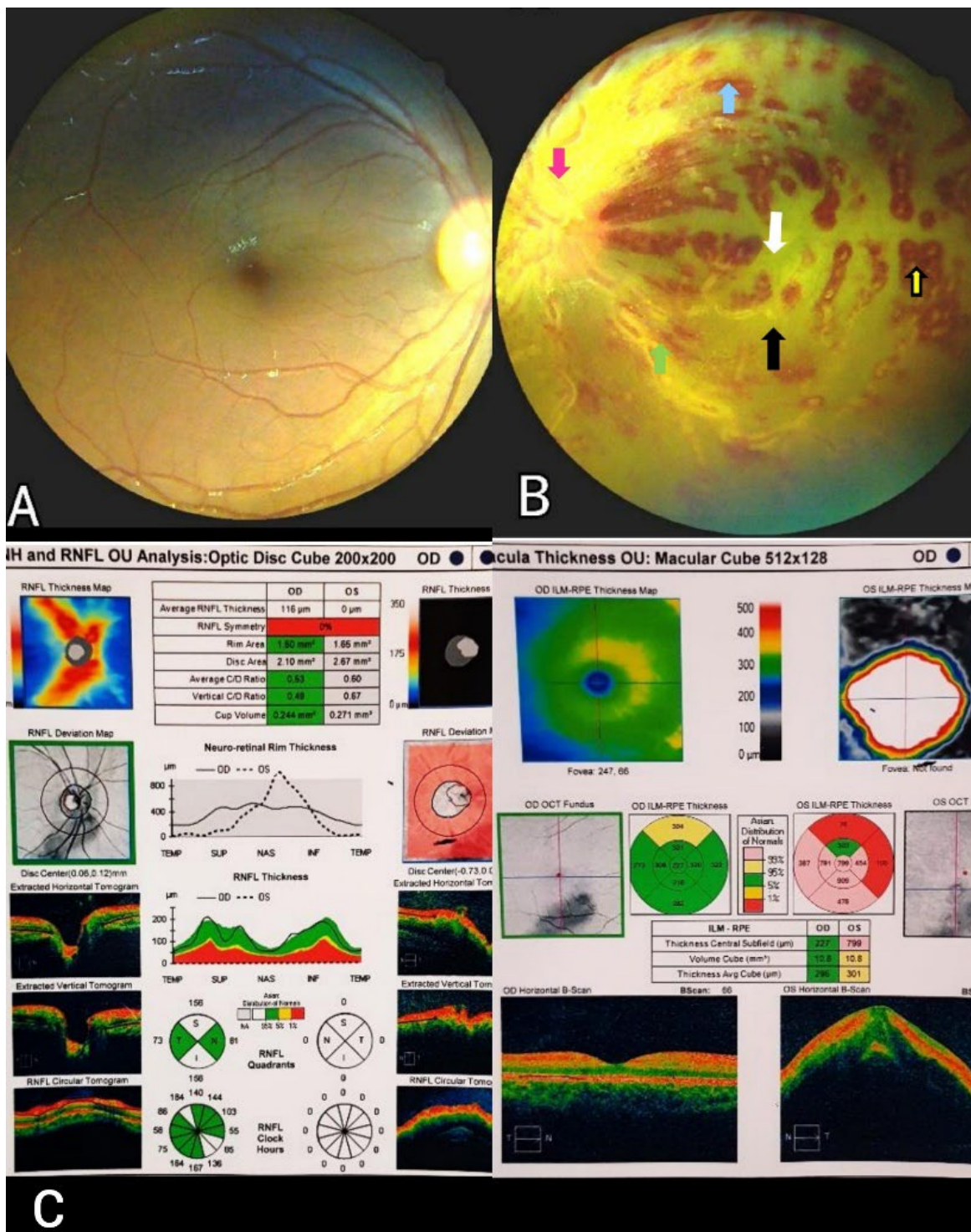


Figure 3. Funduscopy photo (A) of the right eye compared to (B) left eye at 5 day after initial treatment. The left eye revealed disc swelling (pink arrow), vein tortuosity (green arrow), dot blot hemorrhage (black arrow), flame shaped hemorrhage (blue arrow), roth's spot (yellow arrow), retinal edema and macular edema (white arrows). OCT examination (C) showed left exudation of the macula and subretinal, and marked disc swelling. Right eyes was unremarkable

Twenty days later (or 1 month after onset of symptoms) the patient reported subjective improvement in her symptoms. Visual acuity of left eye has improved to 2/60. Anterior segment

examination showed normal findings, with relative afferent pupillary defect, decreased contrast sensitivity, and metamorphopsia of left eye.

Other optic nerve function test of left eye, isihara and confrontation examination were unremarkable. Dilated fundus examination revealed significant regression of optic nerve swelling and retinal hemorrhage, with minimally exudate surrounding macula. Optic coherence tomography examination showed improvement of retinal thickening and

macular thinning with the absent of subretinal hyporeflective.

Head & Orbital MRI and Repeat blood test were done, and the result were normal (Hb 12.4 g/dL). Oral ethylprednidolone was tapered to 16 mg TID according to pediatrician's advice,

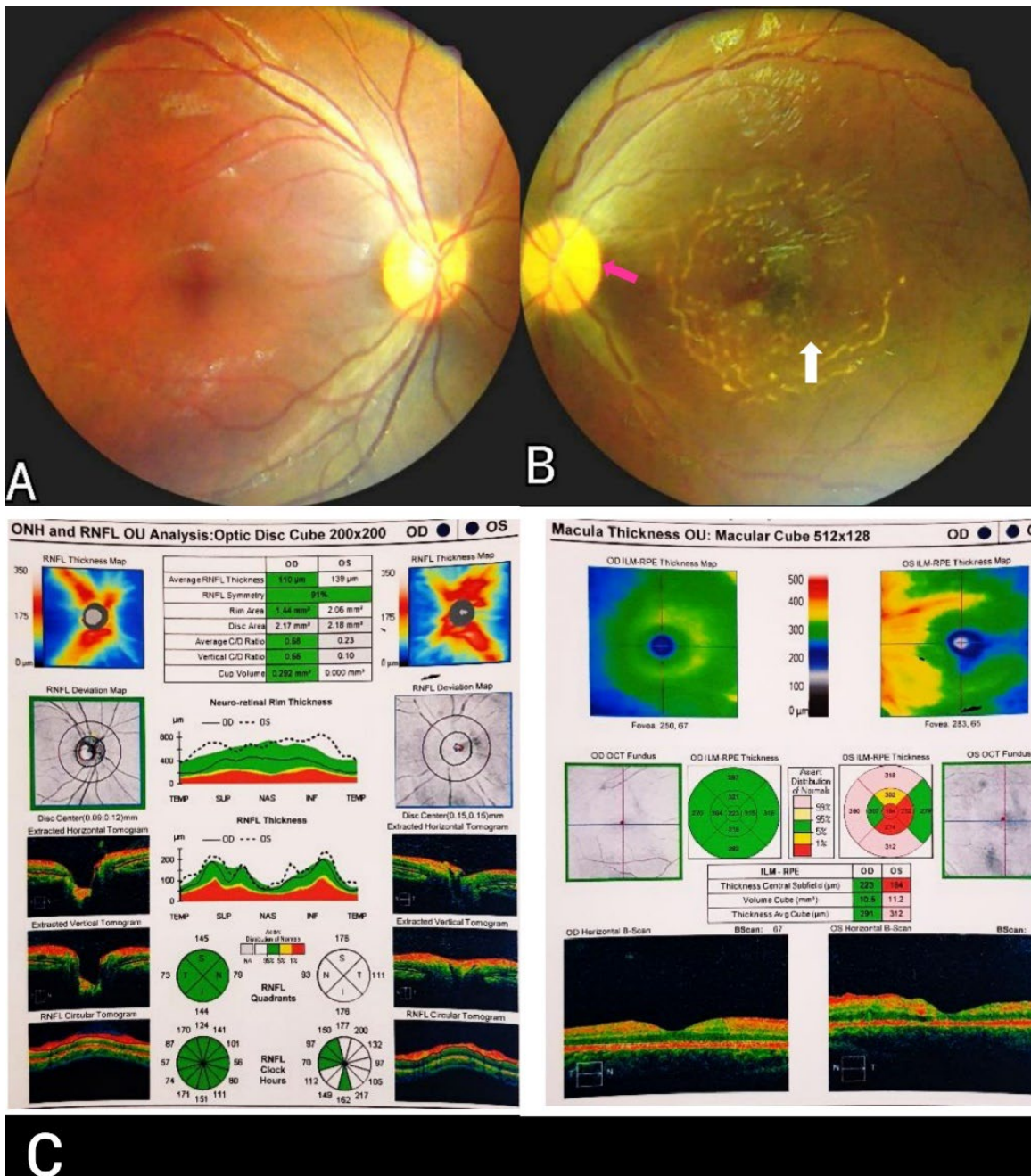


Figure 4. Fundus photo (A) of the right eye and (B) left eye at 20 days after progression of symptoms (or 1 months after initial symptoms). Left eye showed regression of disc edema (pink arrow), exudate (White arrow), and complete resolution of arteriovenous turtoisity, flame shaped hemorrhages, dot blots, roth's spots, and macular elevation. Peripapillary and macular OCT examination (C), also revealed improvement. Right eye was unremarkable.

At the 4 months and 6 months follow-up after onset of symptoms, the patient's best corrected

visual acuity of her left eye improved to 6/24, anterior and posterior segments were unremarkable,

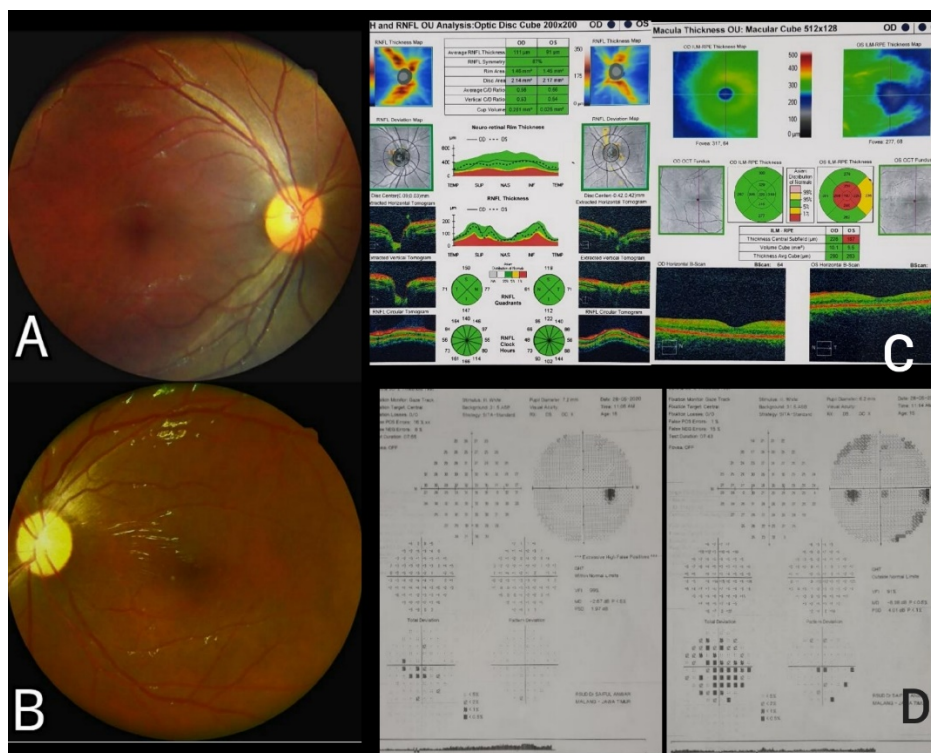


Figure 5. Examination at 4 month follow-up after onset of symptoms. Fundus photograph of both eyes was normal (A) & (B), Left macular OCT (C) showed macular thinning, and Humphrey visual field test (D) showed arcuate defect with central

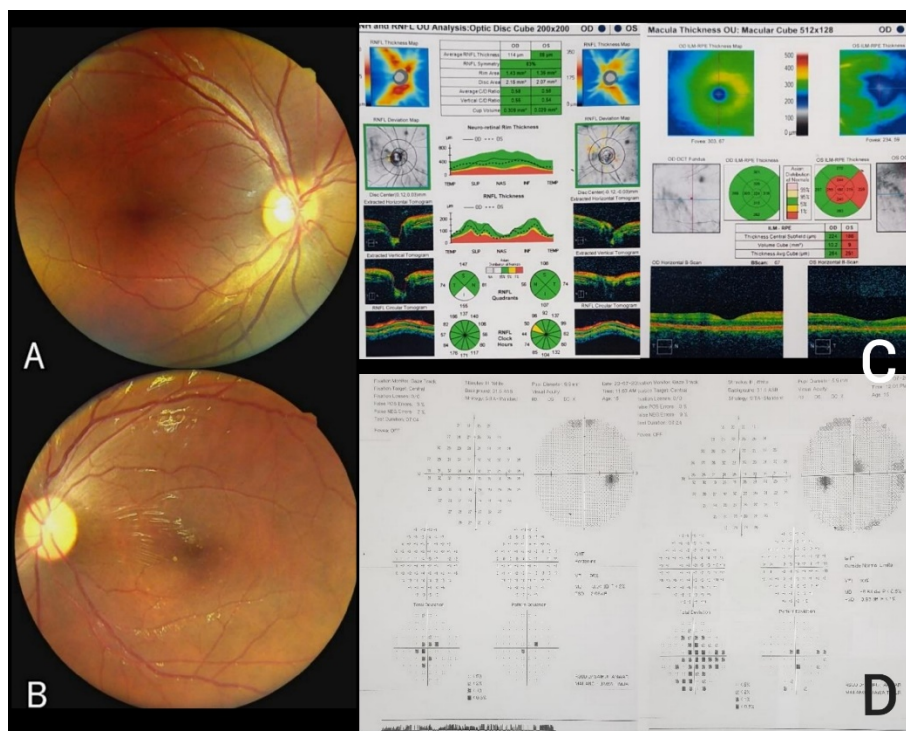


Figure 6. Examination at 6 month follow-up after onset of symptoms. Fundus photograph of both eyes was normal (A) & (B), Left macular OCT (C) showed macular thinning, and Humphrey visual field test (D) showed arcuate defect with central scotoma on the left eye

but the optic nerve function remains altered. There were relative afferent pupillary defect, red green deficiency, decreased contrast sensitivity, and metamorphopsia on central. Humphrey visual field test revealed arcuate defect with central central scotoma. Peripapillary OCT examination showed normal results of both eyes, macular OCT of left eye showed thinning of the macula.

DISCUSSION

Anemia is a very common haematological disorder, which provides various ocular manifestations. Research conducted by Garg and Argawal, pale conjunctiva is the most common ocular manifestation of anemia, seen in 100% of cases. Retinal hemorrhage occupies second most common of ocular manifestation seen in 35% of cases. While the decrease of vision takes third order of ocular manifestation, seen in 29% of cases.⁸ Study by Satish S. et al, concluded that pale on conjunctiva is the most common finding and seen in all patients. Flame shaped hemorrhage is second most common findings, seen in 37.50% of patients. Posterior pole pallor is the third most common finding that seen in 31.25% of cases. Other less common eye manifestations such as edema of eyelids, subconjunctiva bleeding, papilledema, macular star and cotton wool spot.⁹

Sigh et al, on his study concluded that retinopathy only occurs in patients with severe anemia.⁷ Retinal changes that common to all anemia include the findings of retinal haemorrhage (flame shape hemorrhage and dot blot hemorrhage), cotton wool spots, roth spots, retinal edema, hard exudate, change of blood vessels and optic nerve.^{7,10}

Decline of visual acuity can be rare in anemia because most cases are asymptomatic. Hemorrhage, edema, or hard exudate in macula can cause visual impairment. Decreased visual acuity can also occur due to disc edema or optic neuropathy.^{10,11}

Incidence and severity of retinopathy is always proportional to severity of anemia. Therefore,

improvements of anemia will be followed by improvements of ocular manifestation.^{8,9,10}

Decrease of visual acuity in this patient occurs rapidly due to low hemoglobin level that causes bleeding on the retina, macular edema and hypoxaemia associated papilledema or microvascular insufficiency.¹² This explains the findings on macular OCT of the left eye, where the hypoxaemic area showed improvement of thickness and reflectivity in the inner retinal layer corresponds to improvement of retinal oedema. Beside, increasing in contour is also seen in Irregular macules due to edema caused by ischemia. Hyperreflexivity in inner retinal layer causes optical shadowing signal of outer retinal layer and retinal pigment epithelium/choriocapillaris complex resembling retinal edema.¹³

Funduscopy examination in this case show retinal changes in the form of general findings that can be occurs in all types of anemia including retinal hemorrhage, cotton wool spots, retinal edema, vascular changes and optic nerve changes. In this case, retinal hemorrhage occurs in the form of flame shaped hemorrhage, dot and blot hemorrhages and roth spots.

Bleeding that occurs in anemic retinopathy can appeared in the form of superficial bleeding i.e. flame shaped haemorrhage located in the nerve fiber layer of retina (Retinal Nerve Fiber Layer/ RNFL). The bleeding in some cases can appeared as dot and blot haemorrhage which located in the deeper retinal layer. Rare form of bleeding are subhyaloid and vitreous bleeding. White centered retinal hemorrhages or Roth spots are also not uncommon. White lesion in the middle of the Roth spot can be caused by infiltration of inflammation, fibrin and platelets, neoplastic cells, or areas of ischemia.¹² Retinal haemorrhage and retinal edema in suspected anemia related with endothelium cell dysfunction originating from ischemia, reactive retinal vasodilation and improved flow dynamics associated retinal vasculature with hypoxemia.¹⁴

Retinal hypoxia may cause an increase in transmural pressure associated with hypoproteinemia and may cause microtrauma of blood vessel walls, and then causes macular retinal edema and bleeding on the retina.⁸

Cotton wool spots are superficial white lesions that represent RNFL infarcts caused by anemic retinal hypoxia. Retinal edema in anemic retinopathy is caused by hypoxemia which triggers an increase in retinal blood vessel flow dynamics and microtrauma on the vessel wall, thereby increasing transmural pressure and causing leakage. Hard exudates occur as a result of retinal oedema that undergoes repair. If it is severe enough and is located in the macula, then a macular star will appear. Vascular changes occurring in anemic retinopathy include tortuosity, weakness and pallor of arteries and veins. This finding is more pronounced as the severity of anemia increases. Optic nerve changes may present as papilledema or as papillary atrophy at a later stage.¹⁰

In addition to anemic retinopathy, the patient also had ischemic optic neuropathy. In this case, the patient had persistent optic nerve dysfunction including dyschromatopsia, decreased contrast sensitivity, RAPD, and arcuate visual field defect with central scotoma. This is consistent with optic nerve ischemia and macular disorders.

In anterior ischemic optic neuropathy (AION), monocular vision loss may be painless, and may develop over hours to days. Visual acuity may be reduced, but visual field defects are always present. Visual field defects can vary in the form of altitudinal defects, arcuate defects, and other defects. Relative afferent pupillary defect can be seen, unless optic nerve neuropathy occurs in both eyes. Optic disc edema develops at onset and may precede visual disturbances.¹⁵

In addition to the hypertension, diabetes mellitus and nocturnal hypotension that have long been associated with AION, acute anemia has also been

shown to be associated with the incidence of shock-induced ischemic optic neuropathy following massive gastrointestinal bleeding and major surgical procedures. Anemia that contributes to the initiation of non-arteritic ischemic optic neuropathy through delayed organ hypoxia and/or microvascular insufficiency can lead to impaired axoplasmic outflow and subsequent disc oedema.¹²

Neuroimaging using CT scan and MRI is performed in cases of optic nerve swelling to rule out infiltrative optic neuropathy, intracranial masses or space-occupying lesions, including intraorbital lesions that can cause optic nerve head swelling.¹² Magnetic Resonance Imaging (MRI) was performed in this patient and showed normal results, no intracranial mass was detected.

Other examinations in anemic retinopathy are indicated only for treatment consideration. Fluorescein angiography may show delayed arteriovenous transit time in the presence of venous occlusion. Optical coherence tomography (OCT) is useful in cases of vascular occlusion to demonstrate macular edema. Because anemic retinopathy can be seen in oncology patients and in infectious endocarditis or autoimmune disease, a complete blood count with peripheral blood smear is mandatory. Bone marrow biopsy may be indicated in myeloproliferative cases.¹²

Other tests performed on these patients included macular and optic nerve head OCT, blood tests, and MRI of the head and orbits. Examination of the macular and optic nerve head OCT showed optic disc edema and macular edema which worsened at the second visit compared to the other visits.

A study conducted by Carraro et al., proved that anemia can cause retinopathy, especially when there is thrombocytopenia. This also proves that an increase in the severity of anemia and a decrease in platelet levels are associated with an increase in the severity of retinopathy.

This patient's blood test showed a decrease in hemoglobin with normal platelet levels. On subsequent blood tests, it was found that the hemoglobin and platelet levels had improved. It is known that the Patient delayed her blood test due to worsening of general condition. Therefore progression of retinal findings in this patient could not be demonstrated to be associated with decreased hemoglobin and platelet levels.

Glucocorticoids are the gold standard for AIHA treatment with 60% responding well to this therapy and 20% providing complete resolution. In the patients who have a good response to this therapy, glucocorticoids must be tapered down slowly for 2-3 months. But relapses are frequent and the patient should be monitored closely. If the patient does not respond to this therapy, other therapies should be considered. Second-line treatment includes splenectomy and anti-CD20 mAb.¹⁶ Our patient received oral treatment for AIHA with moderate-dose steroids, oral prednisone 32 mg TID given by the pediatrician. Most cases of anemia retinopathy require only treatment of the underlying etiology of the anemia and retinopathy usually resolves on its own.¹⁰

CONCLUSION

Anemia regardless of its etiology is the cause of retinopathy which include retinal hemorrhages, Roth spots, subhyaloid and vitreous hemorrhage, cotton-wool spots, vascular tortuosity, optic disc edema, macular edema and ischemic neuropathy. Severity of the retinopathy corresponds with the severity of anemia. The lower the hemoglobin level, the severe the anemia and, the severe the retinopathy. Therefore, complete blood examination with peripheral blood smear in patients with retinopathy are very recommended. On the other hand, in anemic patients, it is better to do funduscopy examination to evaluate anemic retinopathy, because in most cases anemic retinopathy are asymptomatic.

REFERENCES

1. Oner A, Ozkiris A, Dogan H, Erkilic K, Karakukcu M. Bilateral macular hemorrhage associated with autoimmune hemolytic anemia. *Retina*. 2005 Dec 1;25(8):1089-90.
2. Chew FL, Tajunisah I. Retinal phlebitis associated with autoimmune hemolytic anemia. *Ocular immunology and inflammation*. 2009 Dec 1;17(6):394-5.G
3. Thomas AS, Walter SD, Fekrat S. Bilateral Prefoveal SubInternal Limiting Membrane Hemorrhage in Autoimmune Hemolytic Anemia. *Ophthalmic Surgery, Lasers and Imaging Retina*. 2016 Dec 16;47(12):1151-3.
4. Reddy VS, Samayam P, Ravichander B, Bai U. Autoimmune hemolytic anemia: mixed type—A case report. *Indian Journal of Hematology and Blood Transfusion*. 2011 Jun 1;27(2):107-10.
5. Sankaran J, Rodriguez V, Jacob EK, Kreuter JD, Go RS. Autoimmune hemolytic anemia in children: Mayo Clinic experience. *Journal of pediatric hematology/oncology*. 2016 Apr 1;38(3):e120-4.
6. Carraro MC, Rossetti L, Gerli GC. Prevalence of retinopathy in patients with anemia or thrombocytopenia. *European journal of haematology*. 2001 Oct;67(4):238-44.
7. Singh B, Gupta M, Ahmad E, Srivastava S, Ranjan R, Prabhakar T. Retinal Changes in Anaemia: An Observational Study.
8. Garg P, Agrawal A. Ocular manifestations in patients with anaemia. *J. Evid. Based Med. Healthc*. 2017;4(79):4646-9.
9. Satish SC, Tapan JP. Ocular manifestations in patients with nutritional anaemia. *Indian J of Basic and Applied Med Research* 2014;3(4):89-94.
10. Shah G, Modi R. Anemic Retinopathy: Case Reports And Disease Features. *Retina today*. 2016 May

11. Goel N. The "Double-Ring Sign" in anemic retinopathy evaluated by spectral domain optical coherence tomography. *Retinal Cases and Brief Reports*. 2018 Jul 1;12(3):247-50.
12. Varner P. Isolated unilateral disk edema. *Clin Optom*. 2011;3:13-55.
13. Badaró E, Novais E, Prodocimo LM, Sallum JM. Spectral-domain optical coherence tomography for macular edema. *The Scientific World Journal*. 2014;2014.
14. Mansour AM, Lee JW, Yahng SA, Kim KS, Shahin M, Hamerschlak N, Belfort RN, Kurup SK. Ocular manifestations of idiopathic aplastic anemia: retrospective study and literature review. *Clinical ophthalmology (Auckland, NZ)*. 2014;8:777.
15. American Academy of Ophthalmology. Basic and Clinical Science Course Section 5. NeuroOphthalmology. USA: American Academy of Ophthalmology 2016-2017.
16. Bass GF, Tuscano ET, Tuscano JM. Diagnosis and classification of autoimmune hemolytic anemia. *Autoimmunity reviews*. 2014 Apr 1;13(4-5):560-4.



This work licensed under Creative Commons Attribution