

RECONSTRUCTIVE SURGERY OF SEVERE DAMAGES OF LOWER EXTREMITIES INTEGUMENT AFTER INJURY

O. V. Ponomarenko

ZAPORIZHZHIA STATE MEDICAL UNIVERSITY, ZAPORIZHZHIA, UKRAINE

Background. Injury of lower extremities requires the fastest and most effective method of closing wound surfaces.

Objective. The aim of the study was to define the indications and improve the reconstructive interventions for severe damage of lower extremities integument due to mechanical trauma.

Methods. During 2008-2016, 242 patients with defects of cover tissues of the body and extremities were operated in the clinic. Depending on the size, depth and degree of tissues damage, all were divided into 4 groups.

Results. The lower extremity was the most vulnerable segment (75.2% of patients). Damage Control tactics was used in 83% of cases. To protect the functionally tense areas, free plastics by a split skin graft (the 1st group – 12.8%, the 2nd – 20.4%, the 3rd – 37%, the 4th – 8.9%) were used for closure of the defect. If the wound defect affected functionally significant structures up to 1% of the body surface, the complex flaps of local tissues, tissues close to the defect and anatomically distant areas (the 2nd group – 6%, the 3rd – 10.6%, the 4th – 4.3%) were used. If the defect was more than 1% of the body surface only functionally tense areas were closed with compound complexes of tissues. The rest of the skin was restored by means of autodermoplastics. We suggested and approved our specific protocol of treatment of such injury.

Conclusions. Implementation of the suggested protocol of reconstructive interventions for closure of the defects of cover tissues of lower limbs allowed attaining a positive result in 98.8% of the interventions.

KEY WORDS: **trauma; soft tissue defect; wound surface; flaps; lower extremities.**

Introduction

The defects of cover tissues caused by mechanical factors differ regarding major anatomical and functional changes, damage to main vessels and nerves, bleeding, fractures of partial or complete separation of limb segments [5, 6, 7]. Injury is always accompanied by ischemia and infection of soft tissues and therefore it requires the fastest and most effective method of closing wound surfaces [2, 3, 4, 9, 14]. The nature of the damage in acute trauma of lower limbs, on the one hand depends on the weight, speed, direction and duration of the traumatic agent, on the other – on the location, anatomical and physiological characteristics of the damaged structures [1, 10, 11, 15]. All the above requires a careful evaluation of the volume of reconstruction to

restore the form and function of a lower limb [8, 12, 13, 16].

The aim of the study is to define the indications and improve the restorative reconstructive interventions in cases of severe damage of cover tissues of lower extremities of the mechanical genesis.

Methods

242 patients were involved into study. All of them had defects of cover tissues of the body and extremities as a result of mechanical damage were operated in the Regional Centre of Plastic and Reconstructive surgery (Zaporizhzhia, Ukraine) for the period of 2008-2016. The lower extremities were damaged in 182 cases (182/242; 75.2% of patients). Most of the surgical interventions were performed for tissue restoration: 334 among all 472 (334/472, 70.8%), 235 were reconstructions. The criteria for inclusion in the study were: age of over 17 years old of both sexes with a diagnosed defect of skin and underlying soft tissues of the body and limbs, requiring restoration of form and function of the body. The criteria for excluding

Corresponding author: Ponomarenko Olena, MD, Ph.D., assistant professor of the Department of Disaster Medicine, Military Medicine, Anesthesiology and Intensive Care, Zaporizhzhia State Medical University, Head of the Regional Centre of Thermal Injuries and Plastic Surgery
80 Peremohy str., Zaporizhzhia, Ukraine
Phone number: +38067-612-73-42,
e-mail: alena.ponomarenko@gmail.com

from the study were: patients age of below 17 years old, defects of face and head, ulcerative defects that were developed due to chronic vascular or neurological pathology, as well as the consequences of purulent inflammatory diseases or malignant neoplasms of skin.

Depending on the size, depth and degree of damage of the tissues of lower extremities, all patients were divided into 4 groups. The 1st group I involved 31 (31/182; 17%) patients with a narrow (up to 5 cm in diameter) area of damage of skin and underlying tissues to deep fascia. The 2nd group counted in 56 (56/182; 30.8%) patients with large and extra-large wound surface and damage to soft tissues below deep fascia. The 3rd group was composed 75 (75/182; 41.2%) patients with defects of cover tissues, which developed together or as a result of damage of the osteoarticular apparatus. The 4th group involved 20 (20/182; 11%) patients with combined or multiple trauma accompanied by damage to major vessels, nerves, partial or complete secretion of a limb.

In the 1st group of there were 13 (13/31; 41.9%) males, 18 (18/31, 58.1%) females; average age – 53 years old. In the 2nd group there were 20 (20/56; 35.7%) males, 36 (36/56, 64.3%) females; the average age was 54 years old. In the 3rd group there were 56 (56/75; 74.7%) males, 19 (19/75, 25.3%) females, the average age was 51 years old. In the 4th group there were 17 (17/20; 85%) males, 3 (3/20, 15%) females, the average age – 48 years old.

In all four groups (the 1st, 2nd, 3rd, 4th), there were 76 (41.8%) females and 106 (58.2%) males in the study, the average patients age was 51.8 years old.

All patients were examined by standard clinical and laboratory methods, which included blood and urine tests, total protein and its fractions, glucose test, electrolytes and acids, basic-acid balance, bilirubin, coagulation profile, creatinine, urea, amylase and aminotransferases (ALAT, ASAT) activity, microbiological and cytological examination of the wounds.

Duplex ultrasound (DU) results were one of the most important diagnostic criteria for choosing the method of surgical intervention: marking the feeding vessel of the future complex flap on axial or segmental blood supply. In that case, the length and diameter of the vessel, the depth of its occurrence, the presence of perforations and collateral branches were evaluated. The study was carried out using the Vivid 3 Expert device General Electric (USA) by a linear sensor with a frequency of 5 MHz. The

method allowed visualization of the arteries and veins in real time, studying the functional parameters of blood flow and the condition of surrounding tissues. A comparative assessment of the indicators with those of the opposite limb was performed to reveal a blood flow deficit or severe violations of blood flow. Also, DU allows to investigate the regional hemodynamics was in the injury area and in the donor area of the future non-free complex flap. The quantity of DU: in the 1st group 1 examination was performed, in the 2nd group – 12, in the 3rd – 11, in the 4th – 12.

Results

The choice of the reconstruction method for repair of the defects of cover tissues depended on the volume of damage, as well as on anatomical and functional characteristics and hemodynamic features of the traumatized area.

In 1st group 38 (38/472; 8.1 %) interventions were performed, 8 of which were primary surgical treatment of the wound at the hospitalization stage, and 30 (30/334; 9%) – skin restoration interventions.

The 2nd group patients underwent 126 (126/472, 26.4%) surgeries, 29 – a primary surgical treatment of wounds, autopsy and drainage of hematomas, 97 (97/334; 29 %) – interventions for closure of cover tissue defects.

In 3rd group 237 (237/472, 50.2%) operations were performed, 28 of them were primary surgical treatment of wounds, 4 – opening and drainage of hematomas, 1 – fasciotomy, 40 – operations for bone restoration, 1 – thoracoscopy, 4 – laparocentesis; 159 (159/334; 47.6%) – operations for closure of wound surfaces and defects of cover tissues.

In 4th group, 71 (71/477; 14.9%) patients underwent interventions at the first stage for initial debridement (6 cases), 2 – for drainage of hematomas and wounds treatment, 5 – for fasciotomy, 10 – for bone restoration. In one case, laparocentesis and drainage of abdominal cavity were performed.

48 interventions among 339 (48/334; 14.4%) were performed for restoration of vessels, nerves, and closure of wound defects.

Depending on the depth and mechanism of the injury, combined or multiple trauma, concomitant illnesses, the following surgical interventions for restoration of cover tissues were performed. Free split skin graft was used for the patients of all groups (the 1st – 30/235; 12.8 %, the 2nd – 48/235, 20.4%, the 3rd – 87/235, 37%, the 4th – 21/235, 8.9%) with superficial

granulating wounds of different sizes. One or several grafts were received by disk dermatoms DED-75 (Russia) and DD-717 (Ukraine) or a razor blade, depending on the size of the wound. The thickness of the graft varied from 0.25 to 0.6 mm.

If size of the wound did not exceed 1% (patient's palm size), the method of autodermoplasty by Tyrsh was used, when one or more grafts were taken using a disposable razor blade (thickness of the layer 0.25-0.3 mm).

With proper taking of the graft (thickness of the graft did not exceed two thirds of the derma), the healing processes of the donor's zone was without any functional and aesthetic deficiency. In all groups (the 1st, 2nd, 3rd, 4th), the patients experienced no complications in healing of the donor area.

At the stage of preparation for the surgery, the necrotic tissues were cleaned out of the wounds, marginal cavities were removed, as well as additional hematoma drainage. Stage necrotomy was performed surgically or using bandages, creams, ointments to treat wound and control the microflora. The transplantation was carried out using the standard method. The autodermotransplant was laid out on the wound surface. With two or more transplants, their edges were carefully compared, fixed with individual seams along the edges if necessary (Fig. 1 A, B).

In 2 (2/235; 0.9%) cases (1 in the 2nd group and 1 in the 3rd group) there was a partial lysis of autodermotransplants requiring additional surgical interventions. There were no complications after repeated operations.

By transplantation of free split skin grafts, the surface-granulating wounds of different in

size were closed as quickly as possible. This was especially important in the patients with multiple and combined traumas requiring multi-stage interventions into various anatomical structures. The main disadvantage of this technique was the formation of a structurally and aesthetically defective skin cover in the area of damage. The most optimal result of the study was attained by using different types of flaps with a nourishing stalk.

The indications for use of complex flaps in plastics were:

- the damaged area was a functionally tense part of the limb (projection of joints) or a subject to high mechanical stress (heel, sole);
- poor blood supply to the defect area and the surrounding cover tissues;
- depth of the defect, at the bottom of the wound a freely settled bone, joint, tendon, vessel, nerve;
- elimination of contour defects of the limbs.

The choice of the donor area depended on a patient's age, concomitant pathology, features of regional hemodynamics in the region of the injury. The main principle was a distance to the damage zone - closer to the defect, the better the result of surgical intervention was. An important issue was the scarring in the donor area not to cause functional disorders and have a minimal aesthetic deficit.

The flap with a nourishing stalk can be cut out of the cover tissues that are directly adjacent to the defect, the tissues that are close to the defect or distant anatomical zones (Fig. 2 A, B).

In the 1st group (n=31), the patients with a narrow (up to 5 cm in diameter) area of da-

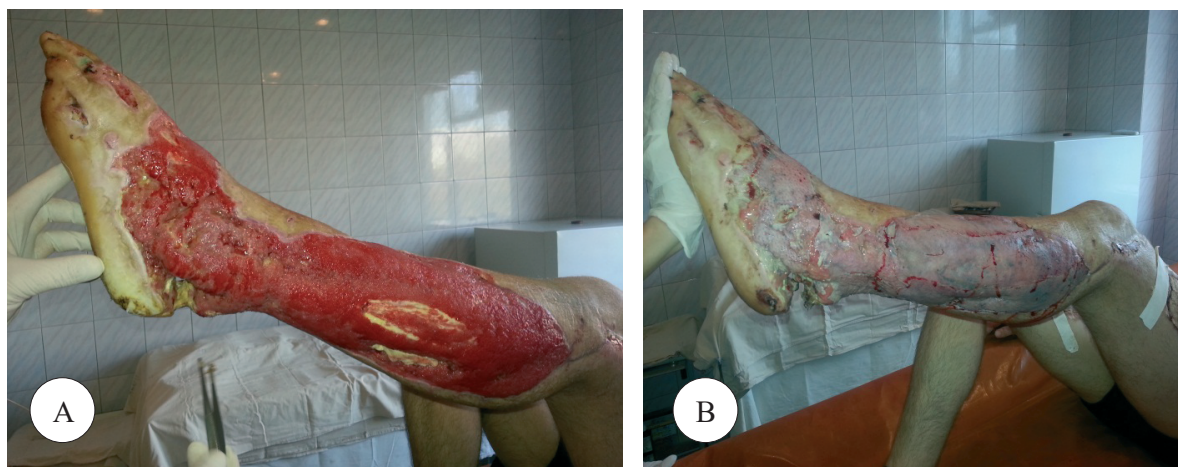


Fig. 1 A, B. Plastics with a free split skin transplant of a semicircular post-traumatic defect of the left shin (patient D., Case No 14318).

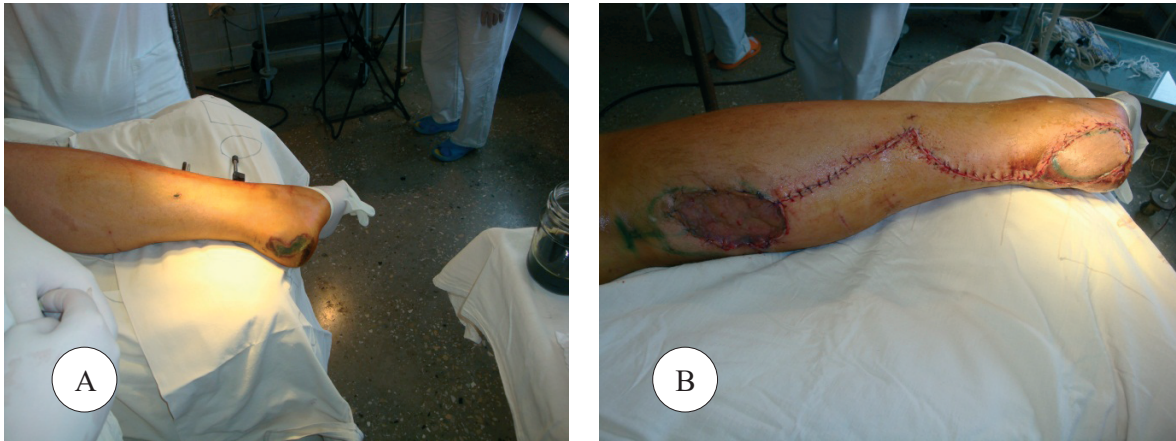

Fig. 2 A, B. Plastic wound defect with five islet flaps with a nourishing stalk (S. S., Case No 20414).

maged skin and underlying tissues to deep fascia, the flap with a nourishing stalk was not used because of the lack of indications for reconstructive interventions.

The patients of the 2nd group (n=56) with a large and extra-large wound area and damage of soft tissue to deep fascia underwent 8 plastics of tissues around the defect using flaps, 5 of which were local plastics by means of flat, sliding flaps, and 3 – by transposition flaps. 6 surgical interventions were performed by flaps of the tissues adjacent to the defect of anatomical sites: 1 – an islet flap with a peripheral stalk, 2 – a bridge-like flaps (a flap with two nourishing stalks), 1 plastic by a flat flap using the technique of derma tension (3 surgical interventions). Totally 14 surgical interventions with complex flaps were performed.

In the 3rd group (n=75), 25 surgical interventions using the flaps with nourishing stalks were performed for the patients with defects of cover tissues that developed together or as a result of damage of osteoarticular apparatus. 3 plastics by local tissues were conducted: 2 – by a sliding flap, 1 – by a transposition flap. 2 surgical interventions were performed by a flap of the tissues adjacent to the defect of anatomical sites: 1 – by an islet flap with a peripheral stalk, 1 plastic – using a flat flap. 20 operations were performed by means of a tubular migratory classical flap (of a remote anatomical site).

The patients of the 4th group (n=20) with combined or multiple trauma accompanied by damage of main vessels, nerves, partial or complete separation of a limb underwent 10 reconstructions using flaps with a nourishing stalk. 7 plastics were performed using the tissues around the defect: 6 – by sliding flaps, 1 – by a transposition flap. 1 closure of the

wound defect was conducted by an islet flap on a peripheral stalk, 2 interferences were conducted by flat flaps, which were formed using the technique of tissue derma tension.

In 1 (1/235; 0.4%) case (in the 3rd group) there was a partial ischemic necrosis of the flap, which required additional surgical interventions. No complications after a repeated operation were present.

Discussion

Only in 17% (the 1st group, n=31/182) of the patients the lower limb trauma was an isolated damage of cover tissues with limited (up to 5 cm in diameter) area of the skin and subordinate tissues damage to deep fascia.

In 83% of patients (the 2nd, 3rd, 4th groups, n=151/182), the injuries were caused by a high-energy trauma, in 41.2% (the 3rd group, n=75/182), the defects of cover tissues developed together or as a result of damage of osteoarticular apparatus, 11% (the 4th group, n=20/182) of patients suffered from combined or multiple injuries that were accompanied by damage to great vessels, nerves, partial or complete abruption of a limb. Therefore, the treatment of the patients of the 2nd, 3rd, 4th groups involved mainly the Damage Control tactics, the main principles of which were to support or sustain life, minimize additional injuries from primary intervention and perform the final surgical reconstruction of a damaged area after stabilizing the patient's condition (Fig. 3).

In cases of initial cover tissues defect of a lower limb, the choice of reconstruction technique depended, according to the algorithm, on the severity of patient's condition on admission. Thus, the patients in a stable condition

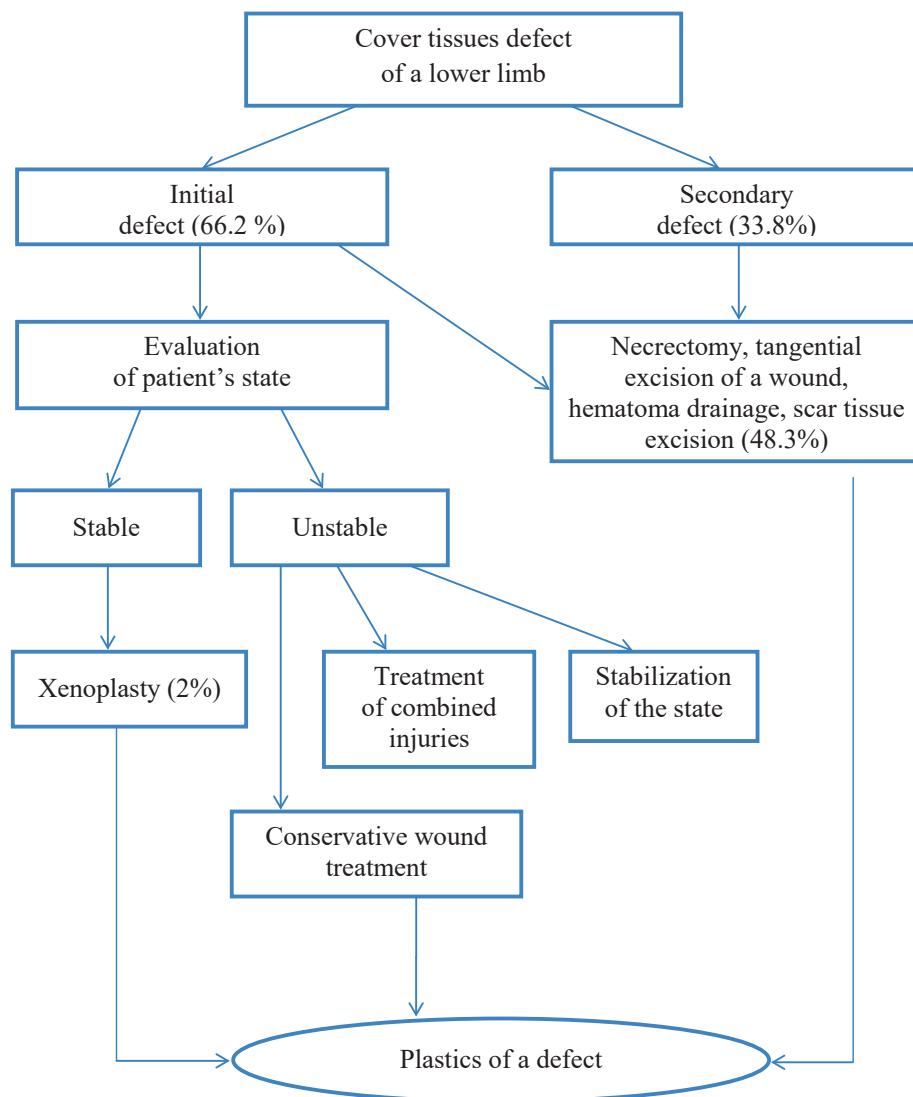


Fig. 3. Algorithm of surgical treatment of cover tissues defect of a lower limb

underwent a primary surgical treatment of the wound according to the standard method; 2% of the patients underwent xenoplasty for temporary closure of the wound surface with the subsequent restoration of cover tissues.

If the patient's condition was unstable, after intensive therapy, normalization of hemodynamics, primary surgical treatment of the wound, stabilization of fracture, management of limb ischemia, the reconstruction of cover tissues was delayed.

The choice of the corresponding tissue graft depended on localization, size of the defect and volume of the damage of subordinate soft tissue structures (Table 1).

Thus, the primary cover tissues defect of a lower limb was present in 100 (66.2%) patients: in the 2nd group – 46 patients, in the 3rd group – 44, in the 4th group – 10 patients. In cases of

localization of the wound surface not in the projection of functionally tense areas, i.e. hip, knee, ankle-foot joints, for the closure of the defect, a free plastic by a split skin graft was used

If the wound defect involved functionally significant structures such as exposed bones and tendons, joint areas and had an area of up to 1% of the body surface, the flaps out of local tissues and tissues close to the defect were used. In 2 patients with cover tissues defect of a limb stump, and in 1 – of a foot stump, the flaps out of anatomically distant areas (tubular flaps) were used to form a full-value stump under the prosthesis. If the defect was more than 1% of the body surface, only functionally tense areas were closed with compound complexes of tissues. The rest of the skin was restored by means of autodermplastics.

Table 1. Characteristic features of the tissues used for closure of the cover tissues defect of a lower limb

Tissues composition	Foot				Shin				Hip			
	I	II	III	IV	I	II	III	IV	I	II	III	IV
Free skin graft (n)	6	3	19	4	24	36	43	7	1	5	5	
Local tissues (n)	-	1	1	-	-	6	2	5		2	1	1
Tissues close to the defect (n)	-	-	1	-	-	2	-	1		1		2
Compound complexes out of distant areas (n)	-	-	1	-	-	-	2	-	-	-	-	-

Notes: n - number of patients.

There were twice less patients with secondary cover tissues defects – 51 (33.8%) patients: 10 patients in the 2nd group, 31 in the 3rd group, 10 patients in the 4th group.

These cases were associated with the presence of tissues necrosis caused by disturbance of blood supply or tissue death due to crushing, development of primary or secondary post-traumatic hematomas, which required drainage and led to cover tissues defects, formation of pathological scar tissue on the area of damage and the need for its excision with the impossible use of the primary suture.

Such patients, according to the above-mentioned algorithm of treatment, underwent primary surgical treatment of the wound; after stabilizing of their condition, a full excision of devitalized tissues with a single-stage plastic of the developed defect was performed. In cases of an unstable state of a patient (more than 2-3

weeks), the closure of the cover tissues defect was implemented using the simplest and least traumatic methods of cover recovery.

The method of choosing a plastic material for closure of a wound surface on a lower limb is presented in Table 1.

Cover tissues defects of the distal areas of a lower limb, which were accompanied by a large (more than 1% of the body surface) and significant area of soft tissues traumatization, were the most severe in terms of full and quick damage recovery (Fig. 4).

The highest frequency of cover tissues defects was present in the segment of a leg, 128 (70.3%) patients, and of a foot 36 (19.8%) patients. The hip was traumatized in 18 (9.9%) patients.

This problem was caused by anatomical, hemodynamic and functional features of a lower limb. Firstly, the array of muscles was unevenly situated on the shin, the anterior and

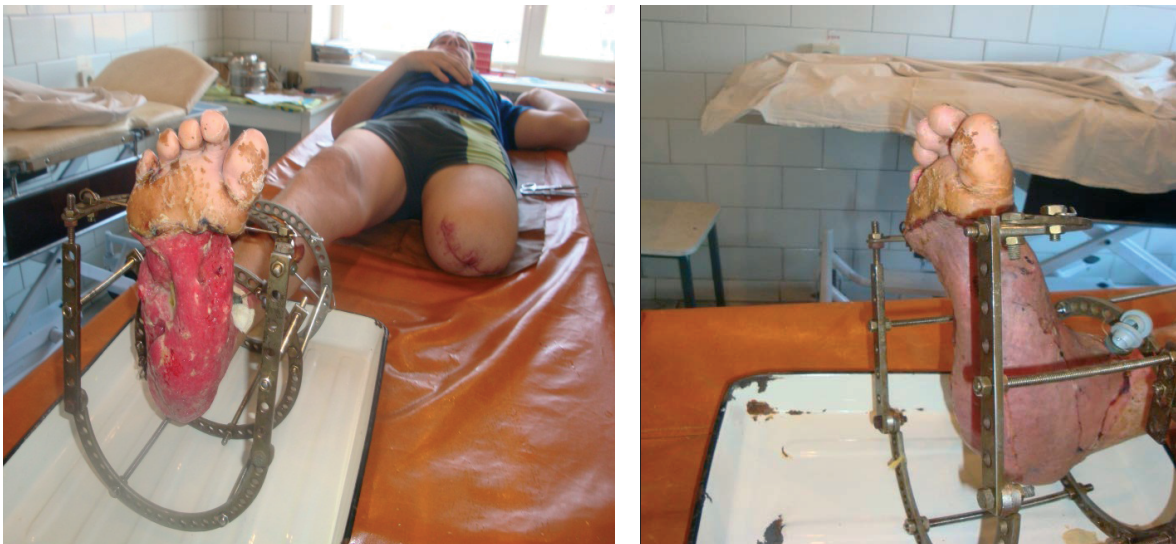

Fig. 4. Patient K., Case No. 19332. Traumatic amputation of the left lower limb at the level of upper third of the leg, crushing of soft tissues, open fragmentary fractures of the bones of the right foot with displacement. Traumatic shock, stage 3. Alcoholic intoxication.

medial surfaces of the tibia were covered only with the skin fascial layer, a lack of soft tissues was present on the foot as well as the specificity of architectonics – a large number of anatomical structures were located in a small space and closely functionally connected with each other.

Secondly, the features of blood supply and the minimum mobility of cover tissues of the distal segments of a lower limb, in cases of combined injuries (83% of patients), did not allow the wound to be sewn by a primary suture, even by moving the skin edges after their mobilization. In that case bone fragments, tendons and muscles were exposed; there was a risk of development of irreversible necrotic purulent inflammatory processes of the osteoarticular apparatus of a limb.

Conclusions

The lower extremity, 182 (182/242; 75.2%) patients, was the most vulnerable segment of the injury. In that case, the defects of cover tissues were characterized by significant anatomical and functional changes, accompanied by bleeding, ruptures and crushing of organs, partial or complete separation of limb segments. The suggested protocol of reconstructive interventions for closure of the defects of cover tissues of lower limbs allowed attaining a positive result in 98.4 % of the interventions.

The prospects for further research go for implementation into clinical practice of full-fledged reconstructive interventions for closure of the defects of traumatic genesis to restore the shape and function of lower extremities in the early stages.

РЕКОНСТРУКТИВНО – ВІДНОВНА ХІРУРГІЯ ВАЖКИХ ПОШКОДЖЕНЬ ПОКРИВНИХ ТКАНИН НИЖНІХ КІНЦІВОК ПІСЛЯ ТРАВМИ

О. В. Пономаренко

ЗАПОРІЗЬКИЙ ДЕРЖАВНИЙ МЕДИЧНИЙ УНІВЕРСИТЕТ, ЗАПОРІЖЖЯ, УКРАЇНА

Вступ. *Пошкодження нижніх кінцівок через загрозу інфікування та розвитку гангрену потребують якомога швидшого та ефективного закриття ранової поверхні*

Мета роботи: *розширити покази та покращити результати відновних реконструктивних втручань при важких пошкодженнях покривних тканин нижніх кінцівок механічного генезу.*

Методи дослідження. *Протягом 2008-2016 рр. у клініці прооперовано 242 хворих з дефектами покривних тканин тулуба та кінцівок, які виникли в наслідок механічного пошкодження. В залежності від розмірів, глибини та ступеню пошкодження тканин нижніх хворі були розподілені на 4 групи.*

Результати. *Найбільш уразливим сегментом при пошкодженнях були нижні кінцівки – 75,2 % пацієнтів. Тактика Damage Control була застосована у 83 % випадків. При локалізації ран не в проекції функціонально напружених ділянок для закриття дефекту використовували вільну пластику розщепленим шкірним трансплантатом (I група – 12,8 %, II – 20,4 %, III – 37 %, IV – 8,9 %). Якщо рановий дефект зачіпав функціонально значущі структури, такі як оголені кістки та сухожилки, ділянки суглобів та мав площу до 1 % від поверхні тіла використовували складні клапти з місцевих тканин, тканин близьких до дефекту та анатомічно віддалених ділянок (II група – 6 %, III – 10.6 %, IV – 4.3 %). При дефектах понад 1 % від поверхні тіла, складними комплексами тканин закривали лише функціонально напружені ділянки. Решту шкірного покриву відновлювали за допомогою аутодермопластики. На підставі отриманих результатів лікування нами розроблено та запропоновано протокол реконструктивних втручань.*

Висновки. *Впровадження запропонованого протоколу реконструктивних втручань для закриття дефектів покривних тканин нижніх кінцівок дозволило отримати позитивний результат у 98,4 % випадків.*

КЛЮЧОВІ СЛОВА: *травма; дефект покривних тканин; ранова поверхня; клапти; нижні кінцівки.*

References

1. De Blacam C, Colakoglu S, Ogunleye AA, Nguyen JT, Ibrahim AM, Lin SJ, et al. Risk factors associated with complications in lower-extremity reconstruction with the distally based sural flap: a systematic review and pooled analysis. *J Plast Reconstr Aesthet Surg.* 2014;67(5):607-16. doi: 10.1016/j.bjps.2014.01.044.
2. Egeler SA, de Jong T, Luijsterburg AJM, Mureau MAM. Long-term patient - reported outcomes following free flap lower extremity reconstruction for traumatic injuries. *Plast Reconstr Surg.* 2018; 141(3):773-83. doi: 10.1097/PRS.0000000000004124.
3. Falola RA, Lakhiani C, Green J, Patil S, Jackson B, Bratescu R, et al. Assessment of function after free tissue transfer to the lower extremity for chronic wounds using the lower extremity functional scale. *J Reconstr Microsurg.* 2018;34(5): 327-33. doi: 10.1055/s-0037-1621736.
4. Karkos CD, Papoutsis I, Giagtzidis IT, Pliatsios I, Mitka MA, Papazoglou KO, et al. Management of Postfasciotomy Wounds and Skin Defects Following Complex Vascular Trauma to the Extremities Using the External Tissue Extender System. *Int J Low Extrem Wounds.* 2018;17(2):113-19. doi: 10.1177/1534734618765343.
5. Keeley J, Koopmann M, Yan H, DeVirgilio C, Putnam B, Plurad D, et al. Factors Associated with Amputation after Popliteal Vascular Injuries. *Ann Vasc Surg.* 2016;33:83-7. doi: 10.1016/j.avsg.2016.02.004.
6. Lang NW, Joestl JB, Platzer P. Characteristics and clinical outcome in patients after popliteal artery injury. *J Vasc Surg.* 2015;61(6):1495-1500. doi: 10.1016/j.jvs.2015.01.045.
7. Liang NL, Alarcon LH, Jeyabalan G, Avgerinos ED, Makaroun MS, Chaer RA. Contemporary outcomes of civilian lower extremity arterial trauma. *J Vasc Surg.* 2016;64(3):731-6. doi: 10.1016/j.jvs.2016.04.052.
8. Mahmoud WH. Foot and ankle reconstruction using the distally based sural artery flap versus the medial plantar flap: a comparative study. *J Foot Ankle Surg.* 2017;56(3):514-18. doi: 10.1053/j.jfas.2017.01.019.
9. Maurya S, Srinath N, Bhandari PS. Negative pressure wound therapy in the management of mine blast injuries of lower limbs: Lessons learnt at a tertiary care center. *Med J Armed Forces India.* 2017; 73(4):321-7. doi: 10.1016/j.mjafi.2016.06.002.
10. Perkins ZB, Yet B, Glasgow S, Cole E, Marsh W, Brohi K, et al. Meta-analysis of prognostic factors for amputation following surgical repair of lower extremity vascular trauma. *Br J Surg.* 2015;102(5):436-50. doi: 10.1002/bjs.9689.
11. Persaud S, Chesser A, Pereira R, Ross A. Sural flap use for the treatment of wounds with underlying osteomyelitis: graft size a predictor in outcome, a systematic review. *Foot Ankle Spec.* 2017;10(6):560-566. doi: 10.1177/1938640017729496.
12. Shammass RL, Mundy LR, Truong T, Weber JM, Grier AJ, Cho EH, et al. Identifying predictors of time to soft - tissue reconstruction following open tibia fractures. *Plast Reconstr Surg.* 2018;142(6):1620-8. doi: 10.1097/PRS.0000000000005007.
13. Stranix JT, Rifkin WJ, Lee ZH, Anzai L, Jacoby A, Ceradini DJ, et al. Comparison of Hand-Sewn versus Coupled Venous Anastomoses in Traumatic Lower Extremity Reconstruction. *J Reconstr Microsurg.* 2018;15. doi: 10.1055/s-0038-1660831.
14. Yang L, Liu H, Zhang W, Song G, Xia S, Zhang N, Gu J, Yuan C. Modified anterolateral thigh perforator flap pedicled by cross-bridge microvascular anastomosis for repairing soft tissue defects in middle and lower segments of leg. *Zhongguo xiu fu chong jian wai ke za zhi= Zhongguo xiu fu chongjian waik e zazhi= Chinese journal of reparative and reconstructive surgery.* 2017 Oct;31(10):1240-4. doi: 10.7507/1002-1892.201705022.
15. Yousaf MA, Abidin ZU, Khalid K, Haq AU, Khalid FA, Tarar FA, et al. Extended islanded reverse sural artery flap for staged reconstruction of foot defects proximal to toes. *J Coll Physicians Surg Pak.* 2018;28(2):126-8. doi: 10.29271/jcpsp.2018.02.126.
16. Zhu Z, Wang X, Huang J, Li J, Ding X, Wu H, et al. Mechanical versus Hand-Sewn Venous Anastomoses in Free Flap Reconstruction: A Systematic Review and Meta-Analysis. *Plast Reconstr Surg.* 2018;141(5):1272-81. doi: 10.1097/PRS.0000000000004306.

Received: 2018-09-17