

## Secondary Choledocholithiasis in Obstructive Jaundice Patient due to Choledochoduodenal-fistula Stricture

*M. Begawan Bestari\**, Eka Surya Nugraha, Siti Aminah Abdurachman

Division of Gastroenterohepatology, Department of Internal Medicine, Faculty of Medicine Universitas Padjadjaran - Hasan Sadikin Hospital, Bandung, Indonesia.

**\* Corresponding Author:**

M. Begawan Bestari, MD, PhD, FASGE. Division of Gastroenterohepatology, Department of Internal Medicine, Faculty of Medicine Universitas Padjadjaran - Hasan Sadikin Hospital, Bandung, Indonesia. Email: begawan@gmail.com.

### ABSTRACT

*Choledochoduodenal fistula (CDF) is a rare condition marked by an abnormal connection between the biliary duct and duodenum. The common etiology of secondary CDF are cholecystolithiasis, tumor, and duodenal ulcer. CDF may also caused by prior inflammatory condition or as a complication of radiation therapy. Management for this case is based on the patient condition. Herein we aimed to present a case of secondary choledocholithiasis due to stricture in the CDF which presented with cholangitis treated by self-expanding metal stent (SEMS) for biliary drainage. Patient admitted with jaundice, fever, right upper quadrant pain, and history of cholecystectomy. Diagnosis of CDF was determined by endoscopic retrograde cholangiopancreatography (ERCP) and followed by putting biliary stent for urgent biliary drainage. The follow up result after stent removal was excellent.*

**Keywords:** choledochoduodenal fistula, CDF, cholangitis, choledocolithiasis.

### INTRODUCTION

Choledochoduodenal fistula (CDF) is a rare condition in which an abnormal connection forms between the biliary duct and duodenum.<sup>1-3</sup> They account for 5–25% of all internal biliary fistulas.<sup>1</sup> Biliary-enteric fistula was first described by Bartholin in 1654.<sup>4</sup> First case report of CDF was described in 1840, however there are only a few cases reported in the world.<sup>1-4</sup> Virtually 90% of CDF, the particular type of biliary-enteric fistulas, are caused by cholecystolithiasis.<sup>4,5</sup> Other causes are pancreatobiliary tumor, and less commonly by duodenal ulcer.<sup>5,6</sup> CDF may ensue following inflammatory causes or as a consequence of radiation therapy. In few cases, it may serve as an alternative pathway of biliary drainage while the main biliary duct is obstructed.<sup>3</sup> This is a case report of secondary choledocholithiasis

due to stricture in the CDF which presented with cholangitis.

### CASE ILLUSTRATION

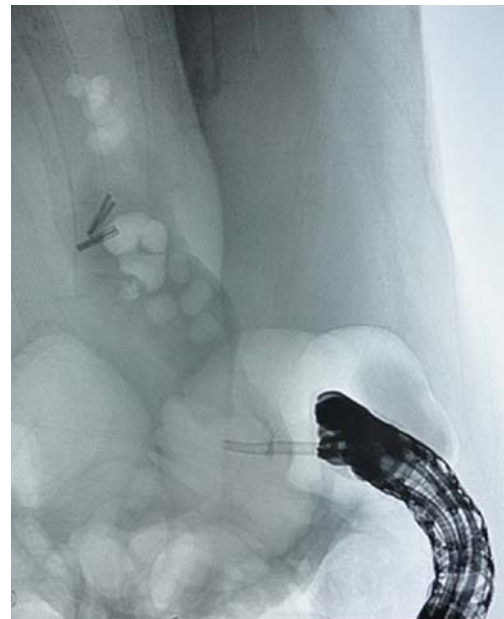A 43 years old female presented with jaundice in the last 10 days. She had fever for 7 days, with right upper quadrant abdominal pain. Patient undergone cholecystectomy 3 years ago. On clinical examination, she was hemodynamically stable with tachycardia and fever (38.1°C). Her sclerae was icteric and abdominal pain at the right upper quadrant. The rest of the physical examination was normal. Laboratory investigations showed raised WBC count (16,550/mm<sup>3</sup>), ureum (52 mg/dl), creatinine (2,1 mg/dl), total bilirubin (9.27 mg/dl), direct bilirubin (7.54 mg/dl), mildly raised liver enzymes (AST 70 U/L, ALT 135 U/L),

increased alkaline phosphatase (247 U/L), Gamma-GT (337 U/L), while amylase and lipase were within normal limits.

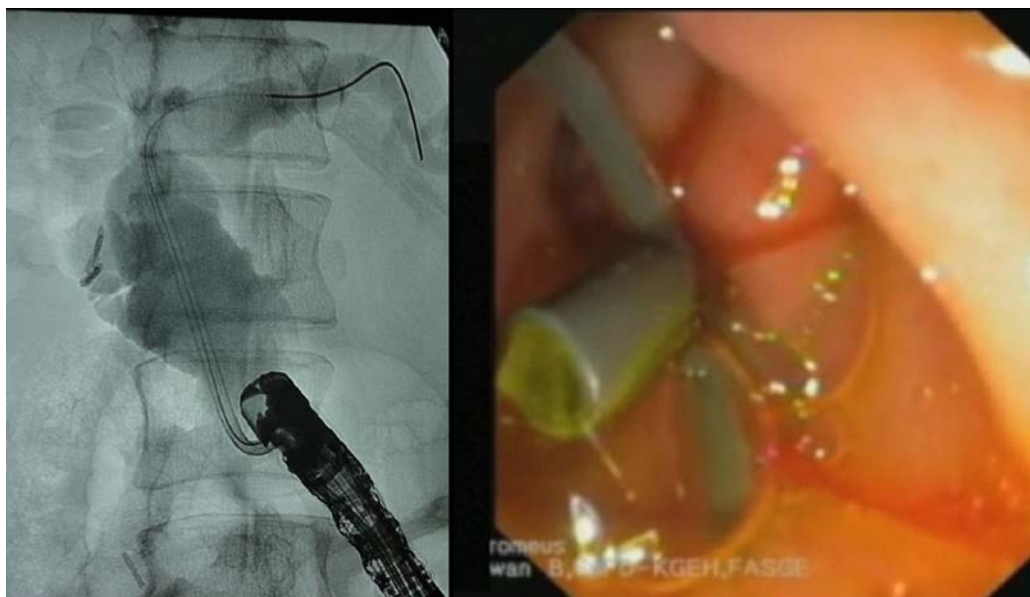
Ultrasonography revealed biliary stone with dilatation of intra and extra hepatic biliary ducts. Patient was diagnosed with severe cholangitis based on Tokyo Guidelines for cholangitis, consequently required urgent biliary drainage. Endoscopic retrograde cholangiopancreatography (ERCP) was performed, however cannulation at ampulla of Vater was unsuccessful. We discovered a fistula adjacent to the ampulla of Vater, proceeded with fistula cannulation. Medium contrast was injected showing a fistula between bile duct and duodenum with stricture at distal part toward the duodenum, multiple biliary stones in the bile duct, and total obstruction at ampulla of Vater (**Figure 1**). The stricture at distal fistula made secondary-choledocholithiasis which lead to severe cholangitis. A Pigtail Plastic Stent 10F was inserted for urgent temporary bile-drainage (**Figure 2**). Subsequently patient's condition improved clinically. Second ERCP was done and the plastic stent was replaced by fully-covered self-expanding metal stent (SEMS) 3 days afterwards (**Figure 3**). Six weeks later, third ERCP was done and SEMS was removed. Follow up cholangiography showed no stones in the bile duct, this result indicated the biliary stones passed spontaneously through the fistula while SEMS was still in placed (**Figure 4**).

## DISCUSSION

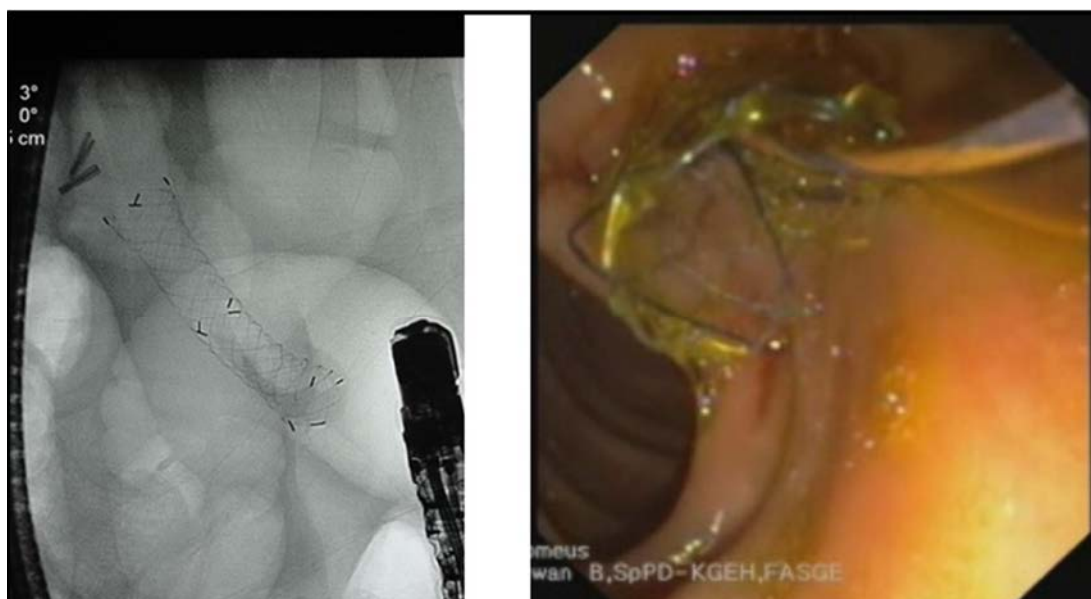CDF was one of the rare conditions reported. A study presents 81 biliary fistula cases from 1948-1998 and choledochoduodenal fistula was only found in 7 cases (8.6%).<sup>7</sup> The most common cause of CDF was cholecystolithiasis.<sup>1,6</sup> Some reported CDF was caused by duodenal ulcer, tumors, and tuberculosis.<sup>6,8</sup> In a study reviewed in the period between 1976 and 1989, 14 (0.7%) patients who underwent ERCP because of biliary disease were found to be having CDF.<sup>9</sup> Another



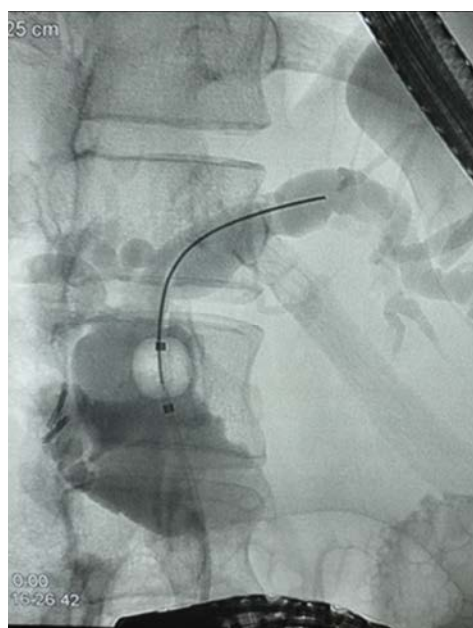
**Figure 1.** CBD Cannulated via CDF with Multiple Biliary Stones.



**Figure 2.** CBD Plastic stent



**Figure 3.** SEMS.



**Figure 4.** Post SEMS removal.

study in China found 50 cases of CDF from 1200 patient with biliary disease who underwent ERCP.<sup>10</sup> The incidence of CDF in an endemic area of cholelithiasis documented as high as 2.53%.<sup>11</sup> The exact pathophysiology of CDF formation is not well known. One hypothesis suggests that it is caused by recurrent gallstone or cholangitis resulting in increased proximal ductal pressure leading to the formation of the fistula. The clinical presentation of CDF is usually unclear. Most of the patients with CDF

presented with symptoms of cholangitis with right upper quadrant pain, jaundice, and fever.<sup>4</sup> Infection occurred due to the ascending bacteria from duodenum to the biliary tract.<sup>1,10,11</sup> In our case, she was admitted with severe cholangitis, noticed by symptoms, ultrasound findings, and sign of organ failure which was acute kidney injury.

Although CDF is difficult to diagnose, recent advances in imaging and endoscopic techniques are developed to increase detection of CDF. Fistulography and cholangiography are commonly used to acquire an accurate diagnosis for all fistula in all cases. The study demonstrated that imaging did not show the fistula in any various imaging modalities.<sup>12</sup> However, some studies reported patients with CDF presenting with pneumobilia on their imaging workups (X-Ray and/or CT).<sup>1,13–15</sup>

In 1975, Ikeda classified CDF into two types of fistulas based on the location. Type I was located on the longitudinal fold of the papilla, while type II was on the posterior wall of the duodenal bulb.<sup>4,16</sup> This patient was considered type II Ikeda classification, owing to the fact that the location of the fistula was posterior from papilla fold or minor papilla. The ampulla of Vater orifice was completely obstructed since unsuccessful attempt of the cannulation. Even so, cannulation resulted in biliary drainage success

in duodenal bulb where the fistula presented.

The option of CDF treatment was based on the etiology, type of the fistula, and severity of the disease. The management of CDF was surgery in general, however, in conditions where surgery remains a relative contraindication, endoscopic biliary drainage is the alternative option.<sup>1,3</sup> The biliary drainage is aimed to reduce the intraluminal pressure to allow bile to flow. The stent will usually be left in place for four to six weeks and removed after excellent follow up result.<sup>17</sup> Previous study describes larger fistula orifices > 1 cm recommended to have surgical therapy since they have higher recurrence rate of cholangitis. However, for fistula orifices less than 1 cm, a biliary drainage can be considered as treatment.<sup>10</sup>

Chintanaboina et al. demonstrated biliary stenting in alternative to surgery for CDF patient with several comorbidities.<sup>3</sup> Study from France shows successful treatment in CDF patient with biliary obstruction by placing endoprosthesis for biliary drainage and have good clinical result in follow up.<sup>18</sup> Other studies demonstrated that using SEMS on endoscopic procedure are found to be effective and reliable for patient with bilioduodenal obstruction and the clinical outcome was excellent.<sup>19,20</sup> We decided to insert 10F pigtail plastic stent, which was subsequently replaced with self-expandable metal stent (SEMS) to optimize drainage since it had a larger diameter. Compared to plastic stents, the use of SEMS in malignant biliary obstruction results in higher rate of patient survival and lower risk of future complication.<sup>21</sup> The follow up result was excellent, patient's condition improved and laboratory parameters returned to normal. The benefit of using large diameter stent also allowed biliary stones to migrate spontaneously, which has never been reported yet.

## CONCLUSION

This case demonstrated a secondary choledocholithiasis with severe cholangitis due to the choledochoduodenal fistula stricture. Inserting self-expandable stent in the fistula allows both bile and even biliary stone to pass spontaneously. Fully covered SEMS insertion may serve as an alternative practice to avoid

surgery procedures on biliary drainage and removing biliary stones, in choledochoduodenal fistula cases.

## REFERENCES

1. B S B, Kar A, Dutta M, et al. A case of choledochoduodenal fistula - an unusual case report. *Clin case reports*. Wiley-Blackwell. 2017;5(9):1462-4.
2. Aguilar-Espinosa F, Maza-Sánchez R, Vargas-Solis F, et al. Cholecystoduodenal fistula, an infrequent complication of cholelithiasis: Our experience in its surgical management. *Rev Gastroenterol México*. 2017;82(4):287-95.
3. Chintanaboina J, Mathew A, Moyer MT. Taking an alternate route home: Stenting of choledochoduodenal fistula. *ACG Case Reports J*. 2015;2(2):104-6.
4. Wu M-B, Zhang W-F, Zhang Y-L, et al. Choledochoduodenal fistula in mainland China: a review of epidemiology, etiology, diagnosis and management. *Ann Surg Treat Res*. 2015;89(5):240.
5. Mallikarjunappa B, S. R. A. Choledochoduodenal fistula: a rare case report with review of literature. *JIMSA*. 2013;26(4):226.
6. Chansaenroj P, Wood S, Rogers SJ. Selective management for gastrointestinal hemorrhage caused by choledochoduodenal fistula. *Siriraj Med J*. 2017;67:97-101.
7. Stagnitti F, Mongardini M, Schillaci F, et al. Spontaneous biliodigestive fistulae. The clinical considerations, surgical treatment and complications. *G Chir*. 2000;21(3):110-7.
8. Yamamoto T, Yamamoto T, Abe K, et al. Choledochoduodenal fistula associated with recurrent peptic ulcer. *J Med Cases*. 2012;3(4):243-6.
9. Jorge A, Diaz M, Lorenzo J, et al. Choledochoduodenal fistulas. *Endoscopy*. 1991;23(02):76-8.
10. Li Z-H, Ding J, Ye Y, et al. New strategy to prevent ascending cholangitis in larger choledochoduodenal fistula. *ANZ J Surg*. 2006;76(9):796-800.
11. Sheu BS, Shin JS, Lin XZ, et al. Clinical analysis of choledochoduodenal fistula with cholelithiasis in Taiwan: assessment by endoscopic retrograde cholangiopancreatography. *Am J Gastroenterol*. 1996;91(1):122-6.
12. Oikarinen H, Päivänsalo M, Tikkakoski T, et al. Acta radiologica findings in biliary fistula and gallstone ileus. *Acta radiol*. 1996;37(6):917-22.
13. Antony A. Pneumobilia resulting from choledochoduodenal fistula secondary to metastatic colon adenocarcinoma. *ACG Case Reports J*. 2016;3(2):112-4.
14. Tonolini M. Spontaneous pneumobilia revealing choledocho-duodenal fistula: A rare complication of peptic ulcer disease. *J Emerg Trauma Shock*. Wolters Kluwer -- Medknow Publications. 2013;6(2):146-7.
15. Dadzan E, Akhondi H. Choledochoduodenal fistula

- presenting with pneumobilia in a patient with gallbladder cancer: a case report. *J Med Case Rep.* 2012;6(1):61.
16. Ikeda S, Okada Y. Classification of choledochoduodenal fistula diagnosed by duodenal fiberscopy and its etiological significance. *Gastroenterology.* 1975;69(1):130–7.
  17. Crespi M, Montecamozzo G, Foschi D. Diagnosis and treatment of biliary fistulas in the laparoscopic era. *Gastroenterol Res Pract.* 2016;2016:6293538.
  18. Ponchon T, Gallez J-F, Valette P-J, et al. Endoscopic treatment of biliary tract fistulas. *Gastrointest Endosc.* 1989;35(6):490–8.
  19. Hori Y, Naitoh I, Hayashi K, et al. Covered duodenal self-expandable metal stents prolong biliary stent patency in double stenting: The largest series of bilioduodenal obstruction. *J Gastroenterol Hepatol.* 2018;33(3):696–703.
  20. Lu L, Tang X, Jin H, et al. Endoscopic ultrasound-guided biliary drainage using self-expandable metal stent for malignant biliary obstruction. *Gastroenterol Res Pract.* 2017;2017:6284094.
  21. Dumonceau J-M, Tringali A, Papanikolaou I, et al. Endoscopic biliary stenting: indications, choice of stents, and results: European Society of Gastrointestinal Endoscopy (ESGE) Clinical Guideline – Updated October 2017. *Endoscopy.* 2018;50(09):910–30.