

Evaluation of Iron Overload Between Age Groups Using Magnetic Resonance Imaging and Its Correlation with Iron Profile in Transfusion-dependent Thalassemia

Pustika A. Wahidiyat¹, Stephen D. Iskandar¹, Damayanti Sekarsari²

¹ Department of Child Health, Faculty of Medicine Universitas Indonesia – Cipto Mangunkusumo Hospital, Jakarta, Indonesia.

² Department of Radiology, Faculty of Medicine Universitas Indonesia – Cipto Mangunkusumo Hospital, Jakarta, Indonesia

Corresponding Author:

Pustika Amalia Wahidiyat, MD, PhD. Division of Pediatric Hematology - Oncology, Department of Child Health, Faculty of Medicine Universitas Indonesia – Cipto Mangunkusumo Hospital. Jl. Diponegoro no. 71, Jakarta 10430, Indonesia. email: pa.wahidiyat@gmail.com.

ABSTRAK

Latar belakang: transfusi darah berulang pada pasien thalassemia menyebabkan penumpukan besi pada berbagai organ. Penanda serum untuk kelebihan besi, yaitu feritin serum dan saturasi transferin, bersifat sensitif tetapi tidak spesifik. MRI T2-star (T2*) sangat penting untuk mendeteksi kadar besi pada berbagai organ. Penelitian ini bertujuan untuk mengetahui derajat hemosiderosis pada berbagai organ, perbedaan derajat penumpukan besi antara anak dan dewasa, serta korelasinya dengan penanda serum untuk kelebihan besi. **Metode:** penelitian ini merupakan penelitian potong lintang terhadap pasien thalassemia yang membutuhkan transfusi rutin. Pasien-pasien tersebut menjalani pemeriksaan MRI T2* di RS Cipto Mangunkusumo sejak 2014 - 2018. **Hasil:** sebanyak 546 subyek terlibat dalam penelitian ini. Jumlah subyek anak dan dewasa setara. Pada umumnya, penumpukan besi di jantung masih dalam batas normal. Perbedaan derajat hemosiderosis jantung antara anak dan dewasa signifikan ($p=0.009$). Evaluasi organ hati menunjukkan umumnya pasien mengalami hemosiderosis sedang-berat, dengan perbedaan antara anak dan dewasa yang signifikan ($p=0.017$). Evaluasi organ pankreas menunjukkan umumnya pasien mengalami hemosiderosis ringan dan penumpukan besi di pankreas terus meningkat dengan bertambahnya usia. Kadar feritin serum mempunyai korelasi yang lemah dengan hasil MRI T2* jantung, korelasi sedang dengan hasil MRI T2* hati dan pankreas. Korelasi saturasi transferin dengan hasil MRI T2* pada berbagai organ sangatlah lemah. **Kesimpulan:** terdapat perbedaan derajat hemosiderosis di jantung dan hati yang signifikan antara anak dan dewasa. Hati merupakan organ dengan penumpukan besi terbanyak, diikuti oleh pankreas dan jantung. Penumpukan besi di hati dan pankreas sudah terjadi sejak anak-anak. Penumpukan besi di pankreas terus meningkat dengan bertambahnya usia. Kadar feritin serum dan saturasi transferin tidak boleh digunakan secara tunggal untuk menilai derajat hemosiderosis di berbagai organ. Kami menyarankan agar pemeriksaan MRI T2* minimal dilakukan 1 kali untuk mengetahui penumpukan besi di organ.

Kata kunci: talasemia mayor, penumpukan besi, T2 relaxation time, serum feritin, saturasi transferin.

ABSTRACT

Background: routine blood transfusion in transfusion-dependent-thalassemia (TDT) causes iron accumulation in various organ. Serum markers of iron overload, serum ferritin and transferrin saturation, are sensitive but not specific. MRI T2-star (T2*) is valuable for detecting iron level in organs. This study aimed to

explore the degree of iron overload in various organs, iron deposition difference between children and adults, also its correlation with serum marker of iron overload. **Methods:** this was a cross-sectional study of TDT patients who had been evaluated by MRI T2* examination in Cipto Mangunkusumo Hospital from 2014 to 2018. **Results:** a total of 546 subjects was included in this study. The number of subjects between children and adults was almost equal. Most of subjects had normal cardiac iron deposition. The difference of cardiac iron overload between children and adults was significant ($p=0.009$). Liver evaluation showed that most of subjects had moderate to severe iron overload. This difference between children and adults was significant ($p=0.017$). Pancreas evaluation showed that either children or adults mostly had mild pancreatic iron overload. Analysis of T2* showed that pancreatic iron deposition progressed with increasing age. Serum ferritin had weak correlation with heart T2* MRI, moderate correlation with pancreas and liver T2* MRI. Relationship between transferrin saturation and T2* MRI was extremely weak. **Conclusion:** cardiac and hepatic iron deposition between children and adults differ significantly. Liver has the greatest iron overload, followed by pancreas and heart. Iron deposition in liver and pancreas has been started from earlier age. Pancreatic iron deposition rises with increasing age. Serum ferritin and transferrin saturation should not be used solely to predict iron overload in various organs. We suggest that MRI evaluation must be conducted at least once to assess iron deposition in organs.

Keywords: thalassemia major, iron overload, T2 relaxation time, serum ferritin, transferrin saturation.

INTRODUCTION

Thalassemia is a group of inherited blood disorder characterized by decrease or absence of one or more globin chains. It is the most common single gene disorder in the world. There are two main treatments for thalassemia: blood transfusion and iron chelation therapy.¹

Transfusion-dependent thalassemia (TDT) is the term given to individuals with thalassemia who require routine blood transfusions. There are three main purposes of transfusion in thalassemia: improve the anemia; suppress the ineffectiveness process of erythropoiesis; and prevent major skeletal and neurological complications. The excess iron from transfused erythrocytes will be accumulated in various organs. In non-transfusion dependent thalassemia (NTDT), gastro-intestinal absorption of iron increases several folds to accommodate the decrease of hemoglobin levels.² Iron overload is toxic to cells, causing severe and irreversible organ damage.¹

Serum markers of iron overload, serum ferritin and transferrin saturation, are inexpensive techniques to predict iron concentration in the body. Those markers have been widely used to determine the needed for starting iron chelation therapy and monitoring therapeutic response. However, these techniques have many shortcomings and cannot be used solely to monitor iron levels in the body. They are sensitive but not

specific. Ferritin as an acute phase reactant will increase sharply in the presence of inflammation. Patients who got frequent transfusion will have fully saturated transferrin.³⁻⁵

Magnetic resonance imaging (MRI) is valuable for detecting iron levels because it is non-invasive, reproducible, accurate, and can be used in various organ. The last characteristic is important because the ability of iron uptake varies in each organ.⁵ MRI is an expensive method, it must be used cost-effectively. In this study, we wanted to explore the difference in iron deposition between children and adults. The result can be used to determine the degree of iron overload in various organs and the progress of iron deposition with increasing age. We also aimed to evaluate the correlation between MRI T2* value in specific organs with iron markers (serum ferritin and transferrin saturation).

METHODS

This study was a cross-sectional study, conducted from 2014 to 2018. Total sampling of all subjects (N=546) who had been evaluated by MRI T2* examination in Cipto Mangunkusumo Hospital were recruited in this study.

This study has been approved by the Ethics Committee of Faculty of Medicine Universitas Indonesia on June 27th, 2016, with a reference number 547/UN2.F1/ETIK/2016.

Subjects

Subjects were divided into two groups: children (≤ 18 years) and adults (> 18 years). We assessed three organs, including heart, liver, and pancreas. MRI assessment was done using MRI Avanto 1.5 Tesla (Siemens Avanto Germany). Quantification of T2* value was obtained using CMRtoolsTM software (Thalassemia-Tools, London, United Kingdom). Liver T2* value was determined in the center of the liver using a single 10 mm slice at 12 different echo times (1.3-23 millisecond=ms). Subjects were asked to hold their breath for 11-13 s. Cut-off points of iron overload by T2* MRI are as follows: Heart: normal >20 ms, mild 14-20 ms, moderate 10-14 ms, severe <10 ms; Liver: normal >6.3 ms, mild 2.7-6.3 ms, moderate 1.4-2.7 ms, severe <1.4 ms; Pancreas: normal >33 ms, mild 10-33 ms, moderate 2.5-10 ms, severe <2.5 ms.^{6,7} Blood sample was collected to measure serum ferritin level (ng/mL) and transferrin saturation (%).

Data Analysis

Data analysis between age groups and degree of iron overload was performed using Chi-square analysis. Correlations between MRI T2* value with iron markers (ferritin and transferrin saturation) was assessed using Pearson's correlation analysis.

RESULTS

A total of 546 transfusion-dependent thalassemia subjects was included in this study. We found that the number of TDT subjects between male and female were almost equal. The number of child subjects (56.4%) was greater than adult subjects (43.6%), with only 3.5% of total subjects were younger than 9 years. Most of the subjects were diagnosed as β -thalassemia and β -thalassemia and HbE/ β -thalassemia. Around 63.7% of them used deferiprone (DFP) monotherapy as iron chelator. (Table 1)

Table 2 showed that most of the children (89.0%) and adults (82.7%) subject had normal iron deposition in the heart. However, cardiac iron overload had been observed more common in adults than children ($p=0.009$). The percentage of severe iron overload in adult subjects was four times greater than children.

Table 1. Subject's Characteristics

Variables	n (%)
Sex	
- Male	277 (50.7)
- Female	269 (49.3)
Age	
- ≤ 18 y.o	308(56.4)
- > 18 y.o	238 (43.6)
Type of thalassemia	
- α -thalassemia	16 (2.9)
- β -thalassemia	257 (47.0)
- HbE/ β -thalassemia	271 (49.6)
- HbE/ α - β -thalassemia	2 (0.3)
Iron chelator	
- Monotherapy	
- DFO	12 (2.2)
- DFP	348 (63.7)
- DFX	85 (15.6)
Combination therapy	
- DFO+DFP	35 (6.4)
- DFO+DFX	10 (1.8)
- DFP+DFX	47 (8.6)
Without chelation	9 (1.7)

The result of liver T2* MRI showed the opposite result, of which almost all subjects had iron overload in the liver. Only few of children (9.4%) and adults (13.4%) still had normal liver iron levels. There was significant difference of severity degree of iron overload between children and adults ($p=0.017$). Severe hepatic iron overload was observed more frequently in adults than children (Table 2).

Iron deposition in the pancreas did not differ significantly between children and adults ($p=0.387$). Only around a quarter of subjects still had normal pancreatic iron deposition. Interestingly, most of them had mild pancreatic iron overload and only a few of them who had severe pancreatic iron overload (Table 2).

Analysis of T2* values (ms) showed that iron deposition in pancreas increased with increasing age and the peak was reached at 45-50 years. Meanwhile, analysis of the heart and liver showed no specific progressive pattern with increasing age (Figure 1).

Table 3 showed that serum ferritin and transferrin saturation were inversely correlated

Table 2. Comparison of cardiac, hepatic, and pancreatic iron deposition between children and adults

Variables	n (%)				p value
	Normal	Mild	Moderate	Severe	
Cardiac iron deposition					
≤ 18 y.o	274 (89.0)	25 (8.1)	5 (1.6)	4 (1.3)	0.009
> 18 y.o	197 (82.7)	18 (7.6)	9 (3.8)	14 (5.9)	
Hepatic iron deposition					
≤ 18 y.o	29 (9.4)	87 (28.2)	107 (34.7)	85 (27.7)	0.017
> 18 y.o	32 (13.4)	49 (20.6)	69 (29.0)	88 (37.0)	
Pancreatic iron deposition					
≤ 18 y.o	79 (25.6)	169 (54.9)	57 (18.5)	3 (1.0)	0.387
> 18 y.o	69 (29.0)	121 (50.8)	45 (18.9)	3 (1.3)	

Table 3. Correlation coefficients between serum markers of iron overload with T2* MRI

	Heart T2*MRI	Liver T2*MRI	Pancreas T2*MRI
Serum Ferritin	- 0.291	- 0.540	- 0.326
Transferrin saturation	- 0.138	- 0.080	- 0.031

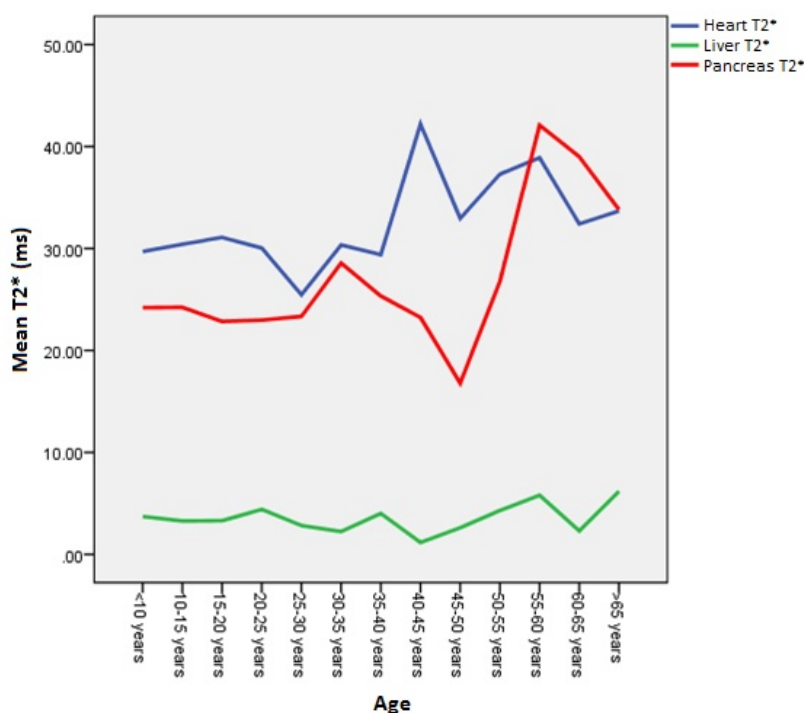


Figure 1. Mean T2* MRI value in various organs

with T2* MRI. There was only weak relationship between serum ferritin and heart T2* MRI. Moderate relationship was observed between serum ferritin and liver T2* MRI, also serum ferritin and pancreas T2* MRI. The correlation of transferrin saturation with T2* MRI was

extremely weak. The scatter plots between those values was presented in **Figure 2**.

DISCUSSION

The gold standard to quantify iron overload is direct measurement of iron concentration in

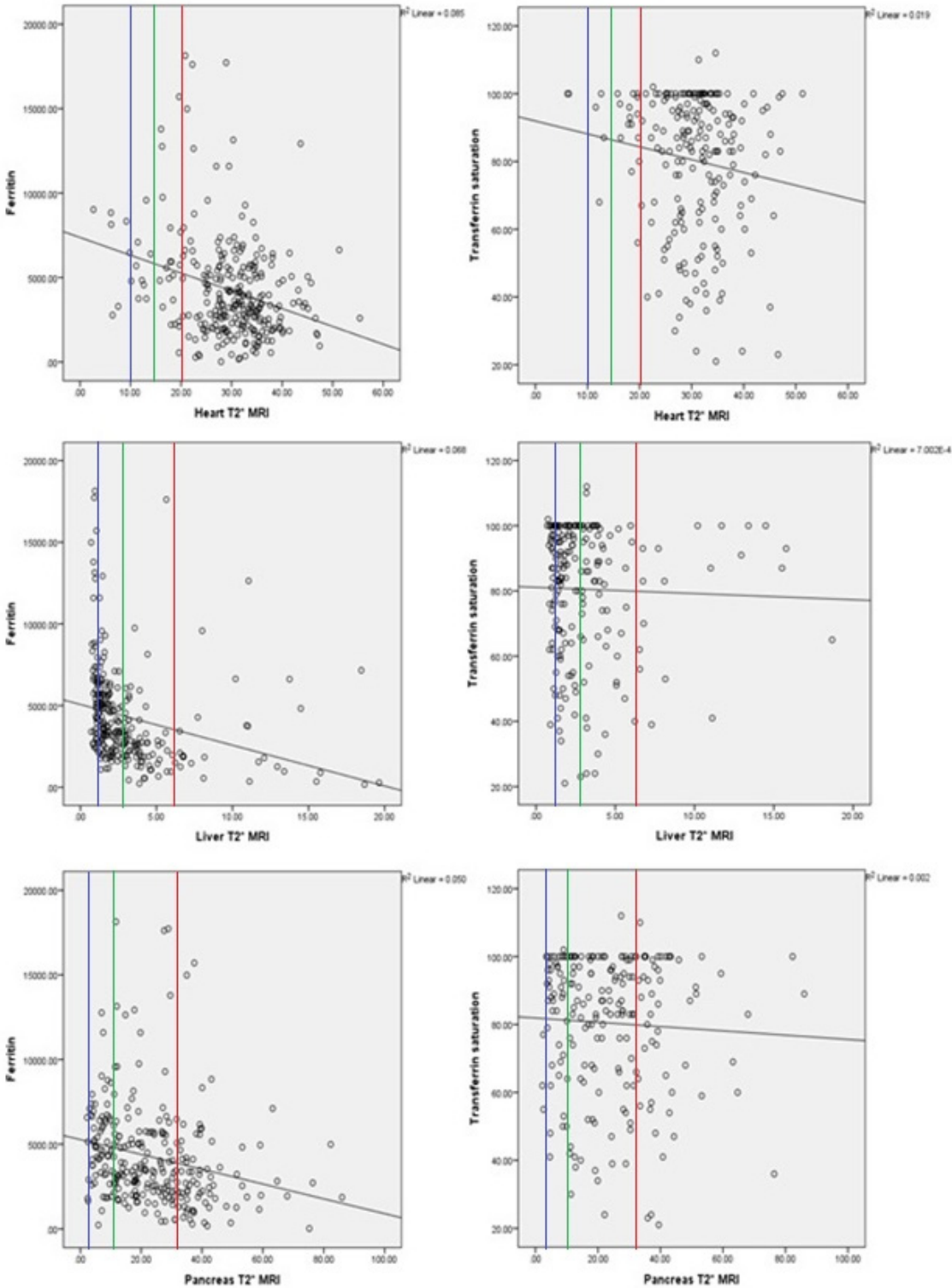


Figure 2. Scatter plots of serum markers of iron overload vs T2* MRI.

(Normal iron overload: area on the right side of red line; mild iron overload: area between green and red line; moderate iron overload: area between blue and green line; severe iron overload: area on the left side of blue line)

biopsy specimens using spectrophotometry. However, this technique is invasive and only available at specialized centers.⁸ T2* relaxometry MRI demonstrated high accuracy and is very effective in quantifying iron concentration in various organs, especially liver.⁵

Our study found that only few subjects had moderate-severe cardiac iron overload. Leonardi et al⁹ found that low values of T2* myocardial was correlated significantly with decreased left ventricular ejection fraction (LVEF). T2* value <9 ms has high sensitivity (100%) and specificity (89%) to diagnose EF <50%. However, its value was correlated poorly with diastolic function.

Interestingly, myocardium was less affected by iron deposition compared to other organs. There are two reasons that may explain this phenomenon. Firstly, extrahepatic tissues have lower kinetic ability of iron uptake because they selectively load circulating non-transferrin-bound iron.^{10,11} The other reason was almost all subjects in our study consumed DFP, around 63.7% as single iron chelator and 15% as combined iron chelator. Deferiprone had been proven to be effective in lowering cardiac iron stores.¹² Even, in some studies it had shown improvement in left and right ventricular ejection fraction.¹³

In our study, the trend of pancreatic iron deposition rose with increasing age, reaching its peak around 45-50 years. Among other organs, liver was the most affected organ. Theoretically, liver iron concentration describes total body iron contents. As the main site of iron storage, liver contains almost 70% of total body iron. Therefore, it is very valuable to monitor the response of therapy.¹⁴

The data from our study should arise more awareness for further liver examination, such as liver elastography. Factor that may contribute to increase the risk of hepatic iron overload is hepatitis infection. Routine blood transfusion increased the risk of transfusion-transmitted infection. One of the studies in our thalassemia center found that the prevalence of positive serological markers for hepatitis B, hepatitis C, and combination infection were 0.8%, 17.8%, and 0.8%, respectively. However, even in the absence of hepatitis infection and other cause

of chronic liver disease, cirrhosis may develop from chronic hepatic iron overload.¹⁵

Our study showed that only around 20% of subjects had moderate to severe pancreatic iron overload. Meanwhile, Noetzly LJ, et al¹⁶ study showed less than 34% of subjects had normal to mild pancreatic iron overload. Maybe it was because in their study mostly the subjects used deferasirox (DFX) as iron chelator (81%), whereas in our study mostly the subjects were on DFP (63.7%). Deferiprone may improve the activity of glucuronyl transferase enzyme.

Pancreas T2* MRI measurement showed that most of subjects had mild iron overload, started from earlier age. The same result was obtained in other Noetzly LJ, et al¹⁶ study, which showed that pancreatic iron overload occurs nearly a decade earlier than cardiac iron overload. This information can be very useful to monitor the response of iron chelation therapy. If a patient has normal cardiac but decreased pancreas T2* MRI value, the physician should not wait cardiac iron overload appearance to modify or increase the chelation therapy.¹⁰ It is important because cardiac iron overload is the leading cause of death in TDT patients.¹⁷

In our study we found that serum ferritin value could not be used solely to predict the degree of iron overload in heart and pancreas because the small correlation between those values. Serum ferritin may be used to predict the degree of hepatic iron overload because the correlation was moderate. However, we must notice that serum ferritin is an acute phase reactant, which is easily affected by any kind of inflammation.³ From our study, we also observed that transferrin saturation should not be used to predict the degree of iron overload in TDT patients. Transferrin saturation is defined as the percentage of transferrin being occupied by iron, which indirectly describes iron overload states in the body. However, TDT patients get frequent transfusions which cause the iron accumulated in body, but it is not followed by the increased iron-binding capacity. Transferrin itself is reduced in the presence of any inflammation, which is almost unavoidable in thalassemia patients.¹⁸ Therefore, almost all patients, either normal, mild, moderate, or severe iron overload

had 100% transferrin saturation. Other markers of non-transferrin bound iron (NTBI), like labile plasma iron (LPI) may be more useful to predict the degree of iron overload and evaluate the response of therapy.

Another interesting finding from our study was that 1.7% of TDT subjects had never used iron chelation. They had normal ferritin value, transferrin saturation, and T2*MRI, although they got routine transfusion. Certainly, protecting factors in this population, such as genetic factors, should be explored. It may become target treatment of iron overload in future.

CONCLUSION

In conclusion, this study demonstrated significant difference of cardiac and hepatic iron deposition between children and adults. Liver had the greatest iron overload, followed by pancreas and heart. Hepatic and pancreatic iron overload in transfusion-dependent-thalassemia patients had started from earlier age. The trend of pancreatic iron deposition rises with increasing age. Our findings suggest that serum marker of iron overload should not be used solely to predict the degree of iron overload. MRI evaluation must be conducted at least once to monitor the deposition of iron in organs.

REFERENCES

- Marengo-Rowe AJ. The thalassemias and related disorders. *Proc (Bayl Univ Med Cent)*. 2007;20(1):27–31.
- Langhi D, Ubiali EMA, Marques JFC, et al. Guidelines on Beta-thalassemia major – regular blood transfusion therapy: Associação Brasileira de Hematologia, Hemoterapia e Terapia Celular: project guidelines: Associação Médica Brasileira – 2016. *Rev Bras Hematol Hemoter*. 2016;38(4):341–5.
- Wang W, Knovich MA, Coffman LG, Torti FM, Torti SV. Serum ferritin: past, present, and future. *Biochim Biophys Acta*. 2010;1800(8):760–9.
- Puliyel M, Sposto R, Berdoukas VA, et al. Ferritin trends do not predict changes in total body iron in patients with transfusional iron overload. *Am J Hematol*. 2014;89(4):391-4.
- Echeverria JMA, Castiella A, Emparanza JI. Quantification of iron concentration in the liver by MRI. *Insights Imaging*. 2012;3(2):173–80.
- Eghbali A, Taherahmadi H, Shahbazi M, Bagheri B, Ebrahimi L. Association between serum ferritin level, cardiac and hepatic T2-star MRI in patients with major β -thalassemia. *Iran J Ped Hematol Oncol*. 2014;4(1):17-21.
- Saggar K, Sobti P. MRI assessment of iron overload in thalassemia: an overview. *Endo-Thal*. 2013;11(1):29-36.
- Hernando D, Levin YS, Sirlin CB, Reeder SB. Quantification of liver iron with MRI: state of the art and remaining challenges. *J Magn Reson Imaging*. 2014;40(5):1003-21.
- Leonardi B, Margossian R, Colan SD, Powell AJ. Relationship of magnetic resonance imaging estimation of myocardial iron to left ventricular systolic and diastolic function in thalassemia. *JACC Cardiovasc Imaging*. 2008;1(5):572-8.
- Noetzli LJ, Papudesi J, Coates TD, Wood JC. Pancreatic iron loading predicts cardiac iron loading in thalassemia major. *Blood*. 2009;114(19):4021-6.
- Noetzli LJ, Carson SM, Nord AS, Coates TD, Wood JC. Longitudinal analysis of heart and liver iron in thalassemia major. *Blood*. 2008;112(7):2973-8.
- Belmont A, Kwiatkowski JL. Deferiprone for the treatment of transfusional iron overload in thalassemia. *Expert Rev Hematol*. 2017;10(6):493-503.
- Berdoukas V, Farmaki K, Carson S, Wood J, Coates T. Treating thalassemia major-related iron overload: the role of deferiprone. *J Blood Med*. 2012;3:119-29.
- Sirlin CB, Reeder SB. Magnetic resonance imaging quantification of liver iron. *Magn Reson Imaging Clin N Am*. 2010;18(3):359-ix.
- Deugnier Y, Turlin B. Pathology of hepatic iron overload. *World J Gastroenterol*. 2007;13(35):4755-60.
- Noetzli LJ, Mittelman SD, Watanabe RM, Coates TD, Wood JC. Pancreatic iron and glucose dysregulation in thalassemia major. *Am J Hematol*. 2012;87(2):155-60.
- de Montalembert M, Ribeil JA, Brousse V, et al. Cardiac iron overload in chronically transfused patients with thalassemia, sickle cell anemia, or myelodysplastic syndrome. *PLoS One*. 2017;12(3):e0172147.
- McLaren CE, Li KT, Gordeuk VR, Hasselblad V, McLaren GD. Relationship between transferrin saturation and iron stores in the African American and US Caucasian populations: analysis of data from the third National Health and Nutrition Examination Survey. *Blood*. 2001;98(8):2345-51.